

Received 15 June 2022, accepted 3 July 2022, date of publication 7 July 2022, date of current version 18 July 2022.

Digital Object Identifier 10.1109/ACCESS.2022.3189374

## RESEARCH ARTICLE

# Hybrid Retinal Image Enhancement Algorithm for Diabetic Retinopathy Diagnostic Using Deep Learning Model

SAIF HAMEED ABOOD<sup>1,2</sup>, HAZA NUZLY ABDULL HAMED<sup>1</sup>, MOHD SHAFRY MOHD RAHIM<sup>1</sup>, AMJAD REHMAN<sup>3</sup>, TANZILA SABA<sup>3</sup>, AND SAEED ALI BAHAJ<sup>4,5</sup>

<sup>1</sup>School of Computing, Faculty of Engineering, University Technology Malaysia (UTM), Skudai, Johor 81310, Malaysia

<sup>2</sup>Wasit Health Directorate, Iraqi Ministry of Health, Al Kut, Wasit 52007, Iraq

<sup>3</sup>Artificial Intelligence & Data Analytics Lab (AIDA), CCIS, Prince Sultan University, Riyadh 11586, Saudi Arabia

<sup>4</sup>MIS Department College of Business Administration, Prince Sattam bin Abdulaziz University, Alkharj 11942, Saudi Arabia

<sup>5</sup>Department of Computer Engineering, College of Engineering and Petroleum, Hadhramaut University, Al-Mukalla 50512 Yemen

Corresponding authors: Saeed Ali Bahaj (saeedalibahaj@gmail.com) and Amjad Rehman (drrehman70@gmail.com)

**ABSTRACT** Diabetic Retinopathy (DR) is a prevalent acute stage of diabetes mellitus that causes vision-affecting abnormalities on the retina. This will cause blindness if not identified early. Because DR not an irreversible procedure, and only vision is preserved via care. Consequently, Early diagnosis and care with DR will significantly minimize the chance of vision loss. In modern ophthalmology, retinal image analysis has become a popular approach to disease diagnosis. The ophthalmologists and computerized systems extensively employ fundus angiography to detect DR-based clinical signs for early detection of DR. fundus photographs are commonly prone to low contrast, noise, and irregular illumination issues due to the complexity of imaging environments such as imaging variety of angles and light conditions. This research presents an Algorithm for improving the quality of images to strengthen the standard of color fundus images by reducing the noise and improving the contrast. The approach includes two main stages: cropping the images to remove insignificant content, then applying the shape crop and gaussian blurring for noise reduction and contrast improvement. The experimental results are evaluated using two standard datasets EyePACS and MESSIDOR. It's clearly shown that the outcomes of feature extraction and classification of enhanced images is outperform the results without applying the enhancement approach. The improved algorithm is also tested in smart hospitals as an IoMT application.

**INDEX TERMS** Image enhancement, deep learning, diabetic retinopathy, retina, fundus image, healthcare, health risks.

## I. INTRODUCTION

The use of efficient image processing technologies improves the quality of treatment that is provided to patients [1]. This Image processing has a diverse range of applications [2], most of these applications are in medicine. Because multiple diseases may affect people. Therefore, early detection is hardly required, particularly in the case of sensitive organs like the eyes. The most crucial eye disease is diabetic retinopathy, glaucoma, retinal neoplasms, and macular degeneration,

The associate editor coordinating the review of this manuscript and approving it for publication was Carmelo Militello<sup>1</sup>.

early detection of which results in cure, but may lead to blindness if the disorder is left undiscovered for an extended time [3]. Color fundus imaging is very important in ophthalmology for detecting various eye diseases. Physicians rely heavily on imaging to make accurate diagnoses of eye diseases. The human eye is considered a light-sensitive body that serves as the primary organ of the visual system. In the existence of daylight, the human eye produces a three-dimensional colored moving image. Rod and cone cells in the retina provide conscious light perception, color differentiation, and depth perception. The retina is lining in the back of the eye as transparent crystalline layer that. Fig. 1 illustrates a healthy

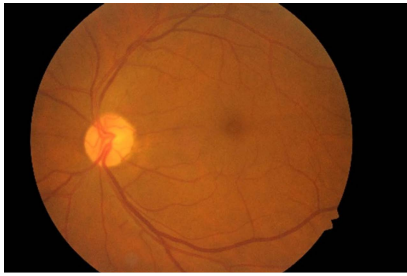


FIGURE 1. Human eye retina.

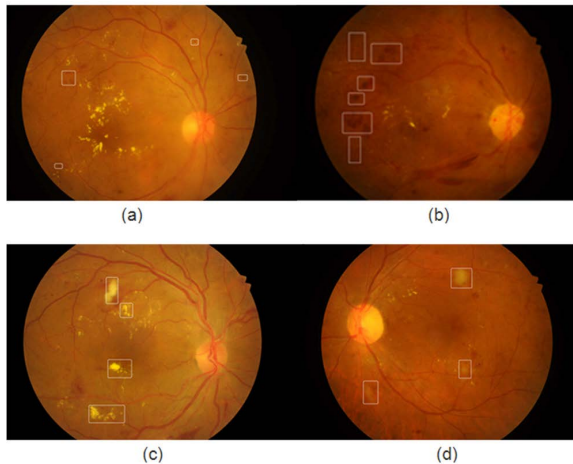


FIGURE 2. An illustration of fundus images (a) microaneurysms (MAs); (b) hemorrhages (HEMs) and vessel abnormality; (c) exudates (EXs); and (d) cotton wool spots (CWSes).

human retina. It is only about 0.2 mm thick and consist of light-absorbing photoreceptors (rods and cones) that transfer image signals from the lens-focused eye to the brain via the optic nerve.

Digital fundus imaging is an effective medical imaging source employed by computer-aided diagnosis (CAD) systems and ophthalmologists to identify various eye diseases in current ophthalmology [4]. Photographs of the fundus's central and posterior retinal surfaces are normally divided into bright "optic disc and optical cup" and dark "macula and fovea" areas. Additionally, fundus images show DR clinical characteristics including "microaneurysms (MAs), hemorrhages (HEMs), exudates (EXs), and cotton wool spots (CWSes)". Clinical experts and screening algorithms commonly process these images for grading and explain the intensity of DR [5]. Fig. 2 highlights a fundus image with DR-based markers.

During the earlier stage of DR, Neovascularization occurs due to advance stage of diabetic retinopathy called proliferative (PDR) on the rear of the eye; it may explode and bleed, blurring the image, due to the fragility of these new-fangled blood vessels. When this bleeding occurs for the first time, it may not be very acute. It often leaves only a few blood dots or spots flowing in a person's visual field, although the scars frequently fade away after some hours. Within a few days or weeks, these spots are frequently followed by a significant increase in blood leakage, resulting in blurred vision. In severe cases, a patient can only distinguish light from

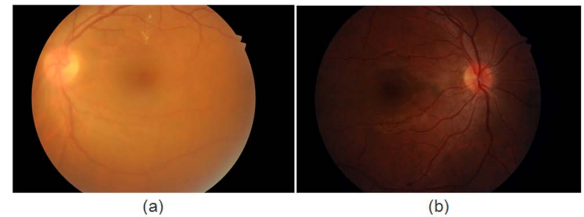


FIGURE 3. A specimen of fundus images in which (a) demonstrates a low lighting ratio and (b) is a hazy, low-contrast photograph.

darkness with that eye. Occasionally, considerable bleeding occurs multiple times, most frequently during sleep [6].

Typically, fundus images are captured with fundoscopic cameras in a disparity of angels and lighting conditions. As a result, those are the images likely to have uneven lighting, low contrast, transmitting flaw, poor brightness, and noise, resulting in inadequate segmentation and classification findings in DR evaluation. Medical imaging treatments may also have an impact on image contrast and detail [7]. Figure 3 clearly shows the fundus images' uneven illumination conditions, noisy, and a low-contrast tissue sample.

Automated DR prognosis is just possible by recognizing fundus images with DR-related features. This may be difficult due to these DR-related lesions' varying contrast, appearance, and structure. MA is characterized as an early diagnostic index of the existence of DR in the images, where the contrast level between vessels and background, and with the light-yellow portion (MAs), white area (exudates), and vascularization system is much limited, allowing of very small MAs segmentation in the relevant retinal portion rhetoric and comprehensive for both physicians and computerized systems. The fundus image quality must be optimized satisfactorily to achieve more accurate DR scenarios or introduce the good visualization of DR-related features. Contrast seems to be a more crucial aspect of better photo quality than brightness in a dynamic scale or resolution. Fundus image contrast improvements has become an essential factor in getting more quantitative measurements from the images by computational algorithms. Various research have been published to enhance fundus images such as Histogram equalization (HE) [8], adaptive histogram equalization (AHE) [9], contrast-limited adaptive histogram equalization (CLAHE) [10], sub-image histogram equalization (ESIHE) [9], bin underflow-bin overflow histogram equalization (BUBOHE) [11], RGB image to Gray image [12], which are solved a different issues of image quality.

It is determined from the literature that the recent enhancement techniques relative to contrast, sharpness features, and the brightness issues need more research, especially it is highly related to the results of disease diagnostics. Therefore, this paper demonstrates enhancement approach for fundus images to improve the image quality. This research has following two main contributions.

- 1- DR detection is performed after image preprocessing phase in order to improve extracted features from image.

- 2- According to our best knowledge, this article is the first in performing DR detection based on feature extraction after retinal cropping. The contribution of retinal cropping in the performance is measured which provides the role of this step in improving DR detection.
- 3- The algorithm of feature extraction is based on deep learning model using ResNet50 which provides rich set of features in order to assist in the classification stage.
- 4- The article provides comprehensive evaluation based on several classifiers with and without retinal cropping and our phase of image enhancement using two benchmarking datasets.

Based on the above, this article aims to propose a hybrid image enhancement algorithm for color fundus images to boost the image contrast and improve the image quality. The model consists of two functionalities: (1) crop image from greyscale (2) Circle Crop and GaussianBlur. In addition, we developed a Deep learning network which has the role of the extraction for relevant features and classify DR accurately. The remaining article includes in section 2 a literature review. followed by the methodology in section 3. Afterwards, we present the dataset in section 4 and experimental works and results in section 5. Eventually, we come to the end of the article conclusion, summary, and future work in section 6.

## II. LITERATURE REVIEW

In the last decades, many image enhancement frameworks have been suggested to improve the computerized disease classifiers especially DR classification. [13] proposed an effective image processing approach to for diabetic retinopathy detection from fundus image, the enhancement of the images included convert the images to (Hue, Saturation and Intensity) then denoise the images. Zhou *et al.*, [14] described a method for assessing retinal pictures called multi-instance learning (MIL). Through pre-trained CNNs, the learnt characteristics are employed to obtain the DR image lesion. They are employed in the DR classification's global aggregation. Leeza and Farooq [15] developed a DR grading system using features bag model. They implemented this to enhance diabetic identification by using a dictionary method in both the preliminary and ultimate processing stages. It is mostly used to merge the outline of abnormal learning. In [16] proposed a a method for human objects classification, The method uses a sensible and reliable geometrical model to categorize the observed object in the photos as either human or non-human. Qureshi *et al.*, [17] presented an image enhancement system consists of two parts, In the beginning, an RGB fundus picture is captured and transformed the module of color presence. (referred to as 'lightness,' and represented by the letter J) to get image details in grayscale with bright light using the CIECAM02 color space design. After that, a nonlinear contrast enhancement approach is used in step two to enhance the fundus image's textural and color characteristics without the need for any additional steps of extraction.

Simon [18] proposed method of enhancing color fundus images by boosting their contrast and luminosity. In order to boost the brightness of RGB components, a luminance gain matrix is employed, whereas, CLAHE is used, to enhance the primary factor in contrast by illumination element of Lab color scheme. Hemanth *et al.*, [19] the authors employed image processing methos in addition histogram equalization and a restricted adaptability histogram equalization methods for the contrast. The resulting images proceed to a convoluo neural network for the diagnostic task. Whereas Pao *et al.*, [20] suggested deep learning framework to improve the detection and diagnosis of diabetic retinal diseases, The proposed method begins with the RGB image's green component. for the detection task of referable DR, the bi-channel CNN uses pre-processed UM entropy images and green component as inputs. Shanthini *et al.*, [21] devised a technique for detecting DR based on threshold segmentation. This method is particularly adept in recognizing the background and front regions of the input retinal picture and processing them using a segmentation approach based on pixels. [22] suggested a process to detect DR by detecting exudates and cotton wall. To enhance the images, they convert them to gray scale and de-noised them by wiener-2-function Afterwards, the contrast was boosted by utilizing Contrast Limited Adaptive Histogram Equalization (CLAHE).

We present a summary of the reviewed articles in terms of three perspectives, namely, image enhancement, classification, and circular retinal crop. It is found that non-of the existing algorithms has applied circular retinal cropping and evaluated that from classification perspective. The goal of this article is to fill this research gap.

### A. BLOCK DIAGRAM

Recently developed systems are challenging to detect most tiny vessels and lesions concurrently. Consequently, it cannot diagnose the early stages of disease. This is due to the problem of image quality. Hence, this article presents a model for enhancing color retinal fundus images and early diagnosis of DR five stages. Figure 4. outlines the conceptual block diagram of the framework. To accomplish that initially the processing has been done for that enhancement is completed followed by the classification.

The model of fundus image enhancement (FGB) is depicted in Fig. 4 As it is shown in the figure, it receives the data of retinal fundus images. Next, it performs foreground identification. Afterwards, the results are fed into Gaussian blurring subblock. The latter is responsible on highlighting the vessels of the retina. Next, the results of the processed image are provided to the network of modified Resnet50 which is responsible on deep learning feature extraction and classification. The final output of Resnet50 is the predicted decision that is provided to the end user.

### B. SEGMENTATION

To begin this approach, we begin by cropping image. The pseudocode is given in Algorithm 1. As it is shown,

TABLE 1. Overview of existing DR detection methods.

Article	dataset	Image enhancement	Classification	Circular Retinal Crop
[13]	DIARETD B1	HSI conversion ((Hue, Saturation and Intensity), DE noising, and Contrast enhancement CLAHE	Deep belief network	×
[14]	Kaggle and Messidor	Resize, contrast enhancement using Gaussian smoothing kernel	CNN-based patch-level classifier	×
[15]	390 images	highlights Laplacian of Gaussian (LoG) filter for regions of rapid intensity change	SVM and ANN	×
[16]	INRIA	Background removal using global threshold and histogram-based methods	Geometrical model	×
[17]	DRIVE and MESSIDOR	Brightness contrast enhancement CIECAM02, Histogram of J module	×	×
[18]	200 images	Luminosity enhancement and contrast enhancement CLAHE	SVM	×
[19]	Messidor	Image enhancement CLAHE and HE	CNN	×
[20]	Kaggle	Convert to RGB and Unsharp mask	CNN	×
[21]	collected	Gray scale conversion, noise removal and threshold segmentation	CNN	×
[22]	DIARETD B0 and DIARETD B1	Noise reduction using logic statistics with the Wiener-2 mechanism, conversion of intensity, normalization, and contrast adjustment utilizing CLAHE were all performed.	SVM	×

A threshold and image are inputs to the algorithm. Level of intensity called threshold is utilized to split the foreground and background. Grayscale and RGB images are both considered by the algorithm. The standards used to build the mask is that the intensity level must be higher than the threshold. The mask isolates the foreground in both grey and RGB images, and the segmented image is given back in the same format as the input image. After that, the segmented images are output.

C. CIRCLE CROP AND GAUSSIAIN BLUR

We conduct circle crop and gaussian blur algorithm to improve the image quality and contrast the occurrence vessels (in their normal or abnormal condition) in the image. The pseudocode of the algorithm is presented in Algorithm 2.

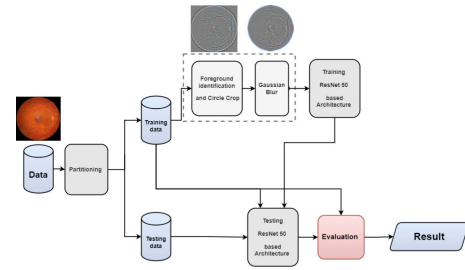


FIGURE 4. A conceptual fundus image enhancement model (FGB).

Algorithm 1 Crop Image From Grey Scale

```

Input:
    (1) image:
    (2) Threshold:
Output:
    SegmentedImage:
1: start algorithm
2: if image.ndim == 2 then
3:     mask = image > threshold
4:     segmented image = image[mask.any(1), mask(0)]
5: else
6:     grayImage = convertColor(image, RGB2GRAY)
7:     mask = grayImage > threshold
8:     redChanel = image[:, :, 0][mask.any(1), mask.any(0)]
9:     greenChanel = image[:, :, 1][ mask.any(1), mask.any(0)]
10:    blueChanel = image[:, :, 2][mask.any(1), mask.any(0)]
11:    segmentedImage = np.stack([redChanel, greenChanel, blueChanel]
12: end if
13: end algorithm
    
```

It accepts in addition to the image four variables, namely, sigma which represents the value of gaussian operation, gamma which represents the value of static weight that will be added to all the pixels of the image, alpha and beta that represents the weight to be considered while performing the blinding. The result of the algorithm is the processed image. As it is shown, after selecting the radius of the circle for cropping in lines 4-6, we conduct the cropping followed by Gaussian blur in line 11. Next, we use the function add weight in OpenCV for obtaining the processed image based on the defined weights.

D. FEATURE EXTRACTION AND CLASSIFICATION

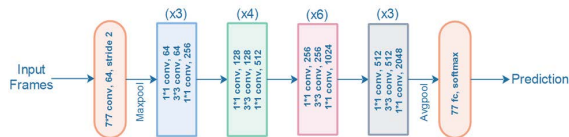The feature extraction and classification model suggested in this work is based on the Resnet architecture [23], It is an ImageNet pre-trained neural network. The main architecture shown in Fig. 5 A ResNet50 is sourced from ResNet 34 by substituting a three-layer bottleneck block for each of the two layers. The FLOP of the model is 3.8 billion. Our design was a reconfigured the version of Resnet50 that FC layers is removed. At the summit of the general model, we added Global Average Pooling layer and a Dropout 0.5 with Dense 2084 neurons. Finally, we used SoftMax layer with five classes for the classification.

**Algorithm 2** Circle Crop and Gaussianblur

Input:

- (1) *image*: The original image will be modified
- (2) *sigma*: Sigma value of gaussian operation
- (3) *gamma*: Static weight that will be added to all the image pixels.
- (4) *alpha*: Weight to be considered while performing the blinding.
- (5) *beta*: Weight to be considered while performing the blinding.

Output:

*imageProcessed***1: start algorithm**2: *img* = cropImageFromGray(*image*)3: *heigh*, *width* = *image*.shape4: *x* = *width*/25: *y* = *height*/26: *radius* = min(*x*, *y*)7: *circleImage* = np.zeros(shape = (*height*, *width*))8: *circleImage* = opencv.cricle(*circleImage*, (*x*,*y*), *radius*)9: *imageProcessed* = opencv.bitwiseAnd(*image*, *image*, *mask*=*circleImage*)10: *imageProcessed* = cropImageFromGray(*imageProcessed*)11: *blur* = opencv.gaussianBlur(*image*, *sigma*)12: *imageProcessed* = opencv.addWeighted(*imageProcessed*, *alpha*,*blur*, *beta*, *gamma* )**13: end algorithm****FIGURE 5.** ResNet-50 neural network architecture.**III. DATASET**

We used the EyePACS dataset from the Kaggle Diabetic Retinopathy Detection competition available on the internet. This dataset contains images of both eyes for each subject. As previously stated, all photographs are categorized by ophthalmologists in accordance with the conventional severity scale in. The photographs were captured using a several cameras, in different conditions, lighting, and resolutions. The dataset is divided into two sets for the training and testing, each including eye photos taken from a different patient.

**IV. THE RESULTS AND DISCUSSION OF THE EXPERIMENTS**

In this article we used the Kaggle dataset [24] which contains a big number of fundus images for five classes DR taken in different situations, these fundus images are provided by a free DR screening platform EyePACS. The MESSIDOR dataset [25] of 1200 fundus images is also used to test the model. The research is used five classes: Normal, Mild, Moderate, Severe, PDR. Our proposed enhancement model is applied to the fundus images, the original samples with their resulted images are shown in Fig. 6. As it is depicted, the image enhancement has isolated non-discriminative information and highlighted the vessels patterns to keep improving the classification performance.

To evaluate our enhancement model, we utilized DRRNet which is designed based on ResNet50, to extract the features

**TABLE 2.** A comparison the outcomes without and with enhancement for Kaggle and Messidor datasets.

Method	Accuracy/ Kaggle	Accuracy/ Messidor
classification without enhancement	73%	79.2%
classification with our enhancement approach	92%	93.6%

and classify them into five classes of DR. The image enhancement stage starts the procedure, then the image proceeded to the neural network, we executed the network with 40 epochs, patch size 8, learning rate is 1e-4, and the optimization algorithm is Adam. The total parameters were 27,794,309, trainable params: 27,741,189, and the non-trainable params: 53,120, with 9 hours 13 mins training time.

And the benchmark model training time was 8 hours and 40 mins. The performance executed with process unit GPU - 4 x NVIDIA Tesla M60 (24 cores, 224 GB RAM. For comparison purposes, we performed different scenarios. First, we classified DR from the original fundus image, which suffers from some illumination, noise, and low contrast. In the second scenario, we applied our enhancement model, the resulted image is progressed as an input to the classification approach. Accuracy, Recall and positive predictive value PPV is the metric which utilized to assess the image classification system's performance. It is the percentage of data that the system correctly identified. Eq. (1) shows the formula for calculating accuracy. Where TP (True Positives) is the count of cases of the class under inspection that classified correctly, TN (True Negatives) it is the total number of incidents that are classified correctly of classes rest that correctly, FP (False Positives) cases that have been incorrectly classified of the remaining classes, and FN (False Negatives) is the amount of incorrectly classified cases of the class during inspection.

$$Accuracy = \frac{TP + TN}{TP + TN + FP + FN} \quad (1)$$

Sensitivity/ Recall is the TP proportion and TP+FN (2)

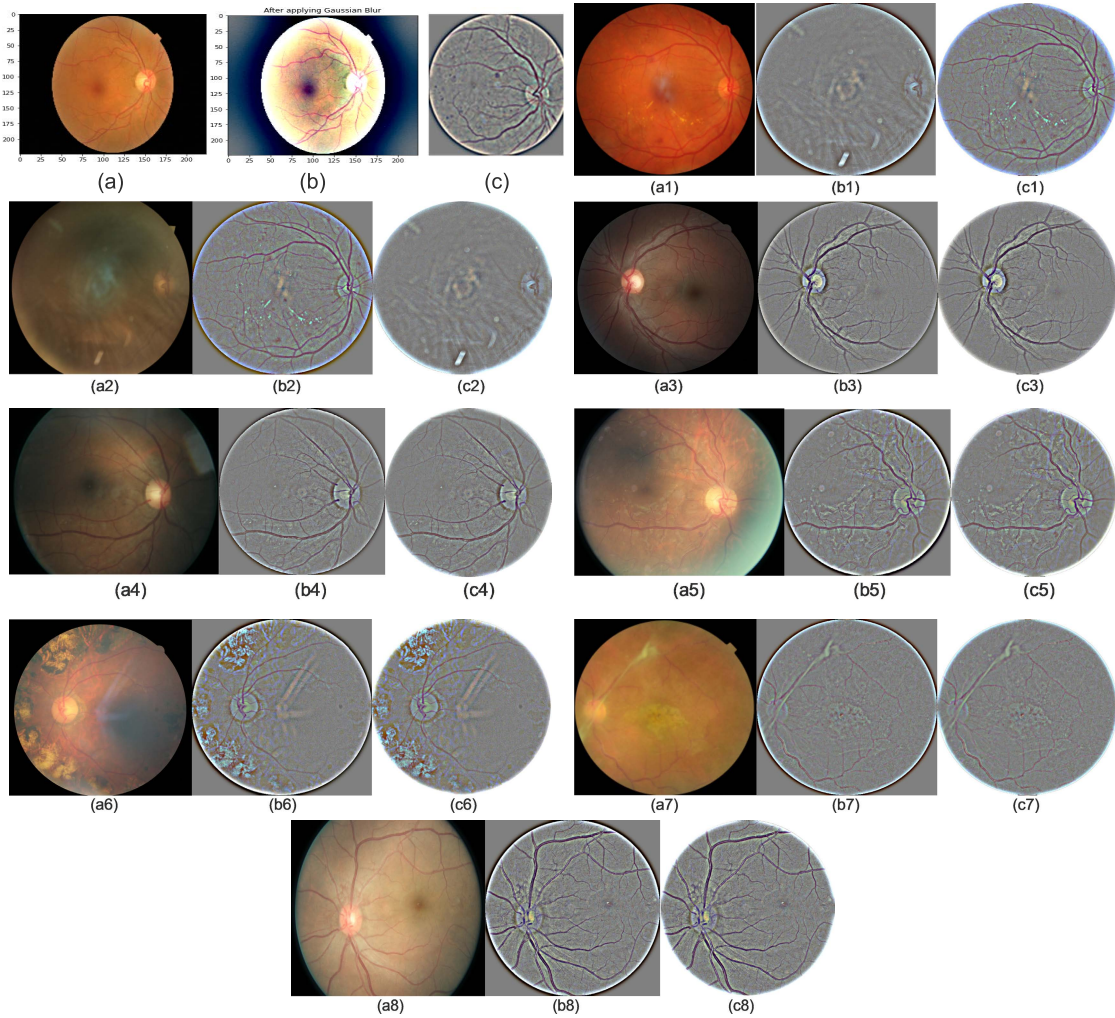
$$Sensitivity = \frac{TP}{TP + FN} \quad (2)$$

Whereas the positive predicted value PPV/ Precision is the TP proportion and TP+FP

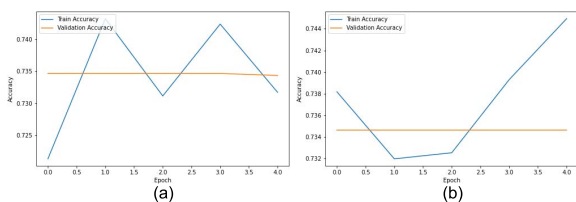
$$Precision/PPV = \frac{TP}{TP + FP} \quad (3)$$

System accuracy results are shown in Table 2. as a result of the experiments conducted.

The experiments show that the measures of DR classification by using Kaggle original images without enhancement was about 73% accuracy, 0.77 sensitivity and 0.56 PPV. whereas after applying our enhancement model, the classification accuracy reached to 92% with 0.82 sensitivity and 0.78 PPV. As well, with the Messidor dataset the classification measures increased from 79.2% accuracy, 0.72 sensitivity and 0.69 with original images to 93.6% by using enhanced images, the sensitivity and PPV was 0.84 and 0.76,



**FIGURE 6.** (a.x) A sample of image in its original form, (b.x) output image after gaussian blur, (c.x) final resulted image after enhancement approach.



**FIGURE 7.** (a) Training accuracy without enhancement, (b) training accuracy with enhancement.

Respectively. It clearly shows the big disparity of results that outperformed the classification without applying proposed enhancement model. The training diagram is shown in Fig. 7. Consequently, when our image enhancement technique is used, the results are superior to those obtained without it. By looking at the outcomes of execution without enhancement of image, it impossible to match the outcomes after the application of image enhancement approach.

This further shows that the suggested approach was effective in improving fundus contrast while maintaining a high level of details and structure of lesions. It's also, successfully removed blurriness and noise from DR fundus images,

**TABLE 3.** Comparison of the Performance with state-of-the-art works on the Kagle dataset.

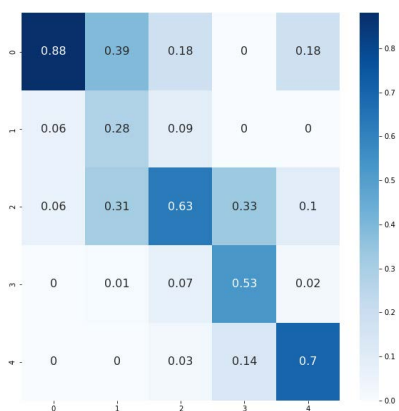
552	Accuracy
[26]	90.7%
[27]	91.6%
[28]	80.8%
[18]	90%
Proposed work	92%

as well. It is evident from the experiments that the suggested technique enhanced fundus image quality more effectively, which improved the feature extraction and the prediction accuracy than the state-of-the-art approaches, as shown in comparison Table 3. It's compared the performance of our work with previous used Kaggle dataset. As well as Table 3. Show the comparison of our result with previous works used Messidor dataset. According to our best knowledge, we obtained the highest accuracy of DR five class classification on both Kaggle and Messidor compared to previous works.

Existing image enhancement methods often adopt those processing steps to improve the quality of the image. Furthermore, current techniques for enhancing fundus images

**TABLE 4. Comparison of the Performance with state-of-the-art results on Messidor dataset.**

Author	Accuracy
[29]	90.5 %
[30]	92.6%
[31]	90.4%
[32]	92.1
Proposed work	93.6%



**FIGURE 8. Confusion matrix of proposed system.**

**TABLE 5. Comparison of metrics evaluation of proposed model with benchmarks Kaggle.**

Measure	SVM	Logistic regression	Decision tree	Benchmark [28]	Our work
Accuracy	74%	79%	69%	80.8%	92%
Sensitivity	74%	72%	78%	51.5%	82%
PPV	78%	77%	79%	63.85%	78%

are primarily ignored the brightness and focused on enhancing contrast. Although both brightness with contrast play an important role in increasing the effectiveness of DR-based CAD systems in classifying important features. The confusion matrix of the posited method is depicted in Fig. 8.

Finally, we demonstrate the performance metrics of the model during the classification task, such as accuracy, positive predictive value PPV, and sensitivity, in a Table 5 and Table 6, along with comparisons to numerous classifier benchmarks and the model presented in [28].

**V. DISCUSSION**

Automatic DR grading has recently been intensively investigated in the research community, especially with advances in deep learning algorithms. In this work, we investigate the significance of the correlation between the image quality improvement and the efficiency of the grading task and propose an image processing approach to capture this correlation. The model included two levels, the image enhancement and grading DR, which was both included a new contribution. First was the combination of crop method from gray scale and contrast enhancement methods that resulted high quality image, as well as the proposed modified deep learning model. From a forementioned experiments of the suggested procedure was found to be more efficient at improving the quality of fundus image than previous methods using a variety

**TABLE 6. Comparison of metrics evaluation of Proposed model with benchmarks Messidor.**

Measure	SVM	Logistic regression	Decision tree	Benchmark [28]	Our work
Accuracy	72%	70%	68%	91.3%	93.6%
Sensitivity	71%	70%	65%	84%	84%
PPV	68%	66%	65%	70.6%	76%

of uneven lighting with a low contrast gradient technique. The results are evaluated on two benchmark datasets, the Kaggle dataset and Messidor dataset, both are accessible free, the evaluation shown the efficacy of our approach. However, brightness and contrast parameters, play a crucial role in boosting the effectiveness of DR-based CAD systems in segmenting and classifying important NPDR features.

Our approach could be used to a wider range of eye disease. The mechanism is designed to learn the attentional weights associated with a single disorder. If there are several associated diseases, the design could be adapted and will have numerous outputs, each of which is optimized by a separate loss function to extract features of the condition. Despite our approach obtains good results, it still has limitations. With just supervision of image-level is used to train the network, making it difficult to detect accurate aberrant indications including Soft Exudates, Hard Exudates, Microaneurysms, and Hemorrhage. Moreover, it’s difficult to train the model to detect the Mild grade due to the similarity with the normal grade. Also, it is very poor features for early-stage DR detecting. Additionally, there is a solution it to use Adversarial Neural Network GAN to generate a new high quality/resolution sample. On the other side, this work has parameter dependency in the enhancement model. Such dependency might affect the performance stability according to the type of data. In order to handle this, an automatic model for enhancement can be used as future work. Finally, the illumination issue didn’t overcome in this work, an illumination correction method also will be used in the future.

**VI. CONCLUSION AND FUTURE WORKS**

Clinically, there is confirmed belief that developing the criterion of fundus image quality enhancement is an efficient factor to boost the outcomes of DR-based automated screening systems. This improvement helps reduce costs for screening programs, thereby increasing access to patients living in rural and urban areas. This article presented an enhancement approach of medical fundus image for DR grading. Initially, a segmentation method based on threshold is proposed to increase the DR disorder detection accuracy. The process begins by identifying the front and backdrop given image to remove the insignificant contents to improve positive classification accuracy by eliminating FP (false positives) and TN (true negatives) early on. Then a circular crop is applied on the image parallel with increasing contrast by gaussian blur algorithm. Finally, the resulted image is progressed as an input to a modified ResNet50 which achieved highest accuracy the state-of-the-art. The proposed scheme’s simplicity of execution and impressive computational performance

may be an effective enhancement system for superior medical image stores. Furthermore, the effectiveness of the presented approach can be evaluated in the future using other colored medical patterns and real time DR screening programs, in which most fundus images are derived from a wide variety of resolutions, contrasts, and ethnicities.

#### FUNDING STATEMENT

No specific funding received for this research.

#### CONFLICT OF INTEREST

Authors have no conflict to declare for this research.

#### ACKNOWLEDGMENT

This work was technically supported by the Artificial Intelligence and Data Analytics (AIDA) Laboratory, CCIS, Prince Sultan University, Riyadh, Saudi Arabia.

#### REFERENCES

- [1] T. Saba, "Recent advancement in cancer detection using machine learning: Systematic survey of decades, comparisons and challenges," *J. Infection Public Health*, vol. 13, no. 9, pp. 1274–1289, Sep. 2020.
- [2] S. A. Hassan, S. Akbar, A. Rehman, T. Saba, H. Kolivand, and S. A. Bahaj, "Recent developments in detection of central serous retinopathy through imaging and artificial intelligence techniques—A review," *IEEE Access*, vol. 9, pp. 168731–168748, 2021.
- [3] S. Akbar, S. A. Hassan, A. Shoukat, J. Alyami, and S. A. Bahaj, "Detection of microscopic glaucoma through fundus images using deep transfer learning approach," *Microsc. Res. Technique*, vol. 85, no. 6, pp. 2259–2276, Jun. 2022.
- [4] A. Shoukat, S. Akbar, S. A. E. Hassan, A. Rehman, and N. Aysha, "An automated deep learning approach to diagnose glaucoma using retinal fundus images," in *Proc. Int. Conf. Frontiers Inf. Technol. (FIT)*, Dec. 2021, pp. 120–125.
- [5] T. Saba, S. Akbar, H. Kolivand, and S. Ali Bahaj, "Automatic detection of papilledema through fundus retinal images using deep learning," *Microsc. Res. Technique*, vol. 84, no. 12, pp. 3066–3077, Dec. 2021.
- [6] A. Rocha, T. Carvalho, H. F. Jelinek, S. Goldenstein, and J. Wainer, "Points of interest and visual dictionaries for automatic retinal lesion detection," *IEEE Trans. Biomed. Eng.*, vol. 59, no. 8, pp. 2244–2253, Aug. 2012, doi: 10.1109/TBME.2012.2201717.
- [7] L. Rundo, A. Tangherloni, M. S. Nobile, C. Militello, D. Besozzi, G. Mauri, and P. Cazzaniga, "MedGA: A novel evolutionary method for image enhancement in medical imaging systems," *Expert Syst. Appl.*, vol. 119, pp. 387–399, Apr. 2019, doi: 10.1016/j.eswa.2018.11.013.
- [8] C. Solomon and T. Breckon, "Pixels," in *Fundamentals of Digital Image Processing*, 2010, pp. 49–83, doi: 10.1002/9780470689776.CH3.
- [9] S. K. Yadav, S. Kumar, B. Kumar, and R. Gupta, "Comparative analysis of fundus image enhancement in detection of diabetic retinopathy," in *Proc. IEEE Region 10 Humanitarian Technol. Conf.*, Dec. 2016, pp. 1–5.
- [10] A. M. Reza, "Realization of the contrast limited adaptive histogram equalization (CLAHE) for real-time image enhancement," *J. VLSI Signal Process. Syst. Signal, Image Video Technol.*, vol. 38, no. 1, pp. 35–44, 2004.
- [11] S. Yang, J. H. Oh, and Y. Park, "Contrast enhancement using histogram equalization with bin underflow and bin overflow," in *Proc. Int. Conf. Image Process.*, vol. 1, Sep. 2003, pp. 1–4.
- [12] T. Kumar and K. Verma, "A theory based on conversion of RGB image to gray image," *Int. J. Comput. Appl.*, vol. 7, no. 2, pp. 5–12, Sep. 2010, doi: 10.5120/1140-1493.
- [13] O. M. A. Hazaimah, K. M. O. Nahar, B. A. Naami, and N. Gharaibeh, "An effective image processing method for detection of diabetic retinopathy diseases from retinal fundus images," *Int. J. Signal Imag. Syst. Eng.*, vol. 11, no. 4, p. 206, 2018, doi: 10.1504/IJSISE.2018.10015063.
- [14] L. Zhou, Y. Zhao, J. Yang, Q. Yu, and X. Xu, "Deep multiple instance learning for automatic detection of diabetic retinopathy in retinal images," *IET Image Process.*, vol. 12, no. 4, pp. 563–571, Apr. 2018.
- [15] M. Leeza and H. Farooq, "Detection of severity level of diabetic retinopathy using bag of features model," *IET Comput. Vis.*, vol. 13, no. 5, pp. 523–530, Aug. 2019, doi: 10.1049/IET-CVI.2018.5263.
- [16] O. M. Al-Hazaimah, M. Al-Nawashi, and M. Sarace, "Geometrical-based approach for robust human image detection," *Multimedia Tools Appl.*, vol. 78, no. 6, pp. 7029–7053, Mar. 2019, doi: 10.1007/S11042-018-6401-Y.
- [17] I. Qureshi, J. Ma, and K. Shaheed, "A hybrid proposed fundus image enhancement framework for diabetic retinopathy," *Algorithms*, vol. 12, no. 1, p. 14, Jan. 2019.
- [18] S. Simon, "Retinal image enhancement and eye disease identification," in *Proc. Int. Conf. Syst., Energy Environ.*, 2019, pp. 1–7.
- [19] D. J. Hemanth, O. Deperlioglu, and U. Kose, "An enhanced diabetic retinopathy detection and classification approach using deep convolutional neural network," *Neural Comput. Appl.*, vol. 32, no. 3, pp. 707–721, Feb. 2020, doi: 10.1007/S00521-018-03974-0.
- [20] S.-I. Pao, H.-Z. Lin, K.-H. Chien, M.-C. Tai, J.-T. Chen, and G.-M. Lin, "Detection of diabetic retinopathy using bichannel convolutional neural network," *J. Ophthalmol.*, vol. 2020, Jun. 2020, Art. no. 9139713, doi: 10.1155/2020/9139713.
- [21] A. Shanthini, G. Manogaran, G. Vadivu, K. Kottilingam, P. Nithyakani, and C. Fancy, "Threshold segmentation based multi-layer analysis for detecting diabetic retinopathy using convolution neural network," *J. Ambient Intell. Humanized Comput.*, vol. 2021, pp. 1–15, Mar. 2021.
- [22] N. Gharaibeh, O. M. Al-hazaimah, A. Abu-Ein, and K. M. O. Nahar, "A hybrid SVM Naïve-Bayes classifier for bright lesions recognition in eye fundus images," *Int. J. Electr. Eng. Informat.*, vol. 13, no. 3, pp. 530–545, Sep. 2021.
- [23] K. He, X. Zhang, S. Ren, and J. Sun, "Deep residual learning for image recognition," in *Proc. IEEE Conf. Comput. Vis. Pattern Recognit. (CVPR)*, Jun. 2016, pp. 770–778.
- [24] C. Sinthanayothin, J. F. Boyce, T. H. Williamson, H. L. Cook, E. Mensah, S. Lal, and D. Usher, "Automated detection of diabetic retinopathy on digital fundus images," *Diabetic Med.*, vol. 19, no. 2, pp. 105–112, 2002.
- [25] M. D. Abramoff, J. M. Reinhardt, S. R. Russell, J. C. Folk, V. B. Mahajan, M. Niemeijer, and G. Quellec, "Automated early detection of diabetic retinopathy," *Ophthalmology*, vol. 117, no. 6, pp. 1147–1154, Jun. 2010.
- [26] B. Harangi, J. Toth, A. Baran, and A. Hajdu, "Automatic screening of fundus images using a combination of convolutional neural network and hand-crafted features," in *Proc. 41st Annu. Int. Conf. IEEE Eng. Med. Biol. Soc. (EMBC)*, Jul. 2019, pp. 2699–2702, doi: 10.1109/EMBC.2019.8857073.
- [27] P. Cao, F. Ren, C. Wan, J. Yang, and O. Zaiane, "Efficient multi-kernel multi-instance learning using weakly supervised and imbalanced data for diabetic retinopathy diagnosis," *Computerized Med. Imag. Graph.*, vol. 69, pp. 112–124, Nov. 2018, doi: 10.1016/j.compmedimag.2018.08.008.
- [28] S. Qummar, F. G. Khan, S. Shah, A. Khan, S. S. Shamsheerband, Z. U. Rehman, I. Ahmed Khan, and W. Jadoon, "A deep learning ensemble approach for diabetic retinopathy detection," *IEEE Access*, vol. 7, pp. 150530–150539, 2019.
- [29] Y.-W. Chen, T.-Y. Wu, W.-H. Wong, and C.-Y. Lee, "Diabetic retinopathy detection based on deep convolutional neural networks," in *Proc. IEEE Int. Conf. Acoust., Speech Signal Process. (ICASSP)*, Apr. 2018, pp. 1030–1034.
- [30] X. Li, X. Hu, L. Yu, L. Zhu, C.-W. Fu, and P.-A. Heng, "CANet: Cross-disease attention network for joint diabetic retinopathy and diabetic macular edema grading," *IEEE Trans. Med. Imag.*, vol. 39, no. 5, pp. 1483–1493, May 2019.
- [31] S. Sengupta, A. Singh, J. Zelek, and V. Lakshminarayanan, "Cross-domain diabetic retinopathy detection using deep learning," *Proc. SPIE*, vol. 11139, Sep. 2019, Art. no. 111390V, doi: 10.1117/12.2529450.
- [32] A. He, T. Li, N. Li, K. Wang, and H. Fu, "CABNet: Category attention block for imbalanced diabetic retinopathy grading," *IEEE Trans. Med. Imag.*, vol. 40, no. 1, pp. 143–153, Jan. 2021, doi: 10.1109/TMI.2020.3023463.

• • •