

Received August 5, 2020, accepted August 24, 2020, date of publication September 2, 2020, date of current version September 22, 2020.

Digital Object Identifier 10.1109/ACCESS.2020.3021343

A Brief Survey on Breast Cancer Diagnostic With Deep Learning Schemes Using Multi-Image Modalities

TARIQ MAHMOOD^{1,2}, JIANQIANG LI^{1,3}, (Senior Member, IEEE),
YAN PEI⁴, (Senior Member, IEEE), FAHEEM AKHTAR⁵,
AZHAR IMRAN¹, AND KHALIL UR REHMAN¹

¹Faculty of Information Technology, Beijing University of Technology, Beijing 100124, China

²Division of Science and Technology, University of Education, Lahore 54000, Pakistan

³Beijing Engineering Research Center for IoT Software and Systems, Beijing 100124, China

⁴Computer Science Division, University of Aizu, Aizuwakamatsu 965-8580, Japan

⁵Department of Computer Science, Sukkur IBA University, Sukkur 65200, Pakistan

Corresponding author: Yan Pei (peiyang@u-aizu.ac.jp)

This work was supported in part by the Beijing Municipal Science and Technology Project under Grant KM201910005028.

ABSTRACT Patients with breast cancer are prone to serious health-related complications with higher mortality. The primary reason might be a misinterpretation of radiologists in recognizing suspicious lesions due to technical issues in imaging qualities and heterogeneous breast densities which increases the false-(positive and negative) ratio. Early intervention is significant in establishing an up-to-date prognosis process which can successfully mitigate complications of disease with higher recovery. The manual screening of breast abnormalities through traditional machine learning schemes misinterpret the inconsistent feature-extraction process which poses a problem, i.e., patients being called-back for biopsies to eliminates the suspicions. However, several deep learning-based methods have been developed for reliable breast cancer prognosis and classification but very few of them provided a comprehensive overview of lesions segmentation. This research focusses on providing benefits and risks of breast multi-imaging modalities, segmentation schemes, feature extraction, classification of breast abnormalities through state-of-the-art deep learning approaches. This research also explores various well-known databases using "Breast Cancer" keyword to present a comprehensive survey on existing diagnostic schemes to open-up new research challenges for radiologists and researchers to intervene as early as possible to develop an efficient and reliable breast cancer prognosis system using prominent deep learning schemes.

INDEX TERMS Breast cancer, computer-aided-diagnosis, deep learning techniques, medical image analysis, lesions classification, segmentation.

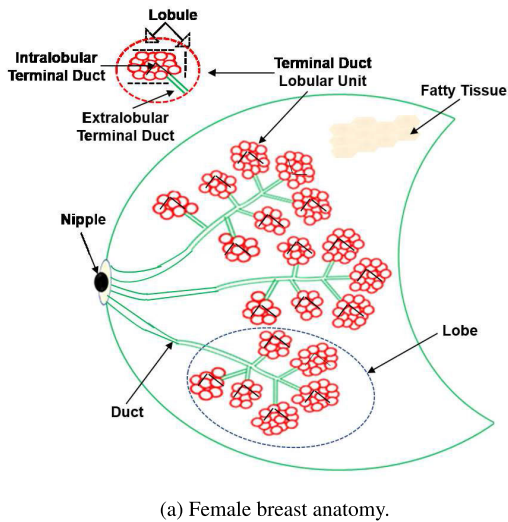
I. INTRODUCTION

Cancer is the second death-causing disease that affects worldwide women. Cancer is a disorder range of the lethal cell if left untreated leads to indolent lesions and mortality [1], [2]. Abnormal cells are created as a result of a genetic mutation that grows out of control and becomes cancerous due to the changes in its deoxyribonucleic acid [3], [4]. Benign (a noncancerous tumor) does not invade neighboring tissue while malignant (cancerous tumor) spread in multiple body

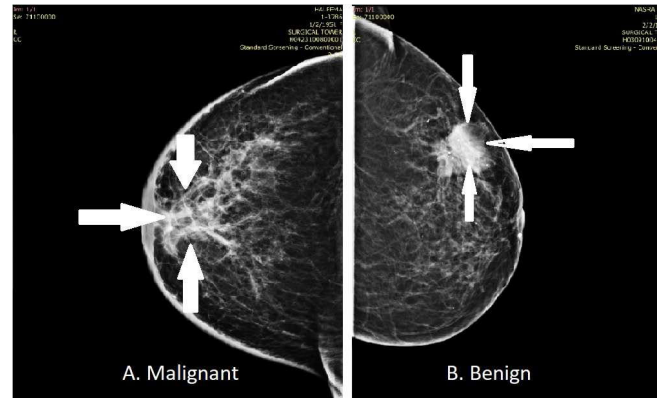
The associate editor coordinating the review of this manuscript and approving it for publication was Wentao Fan¹.

functions via the lymphatic system and elicits nutrients from the body tissues [5], [6]. The most dominant cancer types are lymphoma, sarcoma, carcinoma, leukemia, and melanoma. Carcinomas is the most widely diagnosed form of cancers.

The breast tissues are comprised of various connective tissue, blood vessels, lymph nodes, and lymph vessels. (Figure 1a) shows the anatomy of the female breast. It often establishes, when the breast tissues grow abnormally and cell division is not controlled that results in the formation of a tumor. The developed tumor can be invasive or non-invasive which usually starts in milk ducts or the lobules [7], [8]. Invasive cancer may start in lymph nodes which spreads



(a) Female breast anatomy.



(b) Malignant and Benign masses.

FIGURE 1. (a). Female breast anatomy including the nipple, lobes, lobules and ducts, which are embedded within a matrix of fatty tissue. (b). Breast mammographic images show malignant mass (left) and benign mass (right).

in different organs using blood vessels but cancerous cells often remain separated from the tumor [9], [10]. Moreover, breast cancer is classified into various subtypes based on their morphology, shape, and structure [11], [12].

Early identification of breast cancer can assist in the prognosis process which can successfully mitigate serious complications of the disease with higher recovery [13], [14]. Various medical multi-imaging modalities such as digital mammography breast X-ray images (DMG), Ultrasound sonograms (ULS), magnetic-resonance-imaging (MRI), Biopsy (Histological images), and computerized tomography (CT) are exercised for breast cancer screening and classification. The auto-detection of lesions, lesions volume and its contour in mammography images is a prominent sign which is most significant in detecting the distorted edge of the malignant and smooth edge of benign tumor. (Figure 1b) demonstrates the benign and malignant masses in a digital mammogram [15]–[17]. It truly helps radiologist's in investigating malignancy and quickly analyzing the lesions to forbid avoidable biopsies. Initially, the radiologists analyze the images manually and final decisions are suggested after the mutual consensus of other experts. The availability of many radiologists at the same time in under-developed countries is a key issue. Moreover, the precise analysis of the multi-class images depends upon the experiences and domain knowledge of the radiologist.

Furthermore, the initial identification of breast cancer needs comprehensive monitoring of biochemical indicators and imaging modalities. CAD systems can serve as a second option to resolve breast cancer multi-classification issues. It can serve as an inexpensive, voluntarily accessible, speedy, and consistent source of early diagnosis of breast cancer. It can also assist the radiologists in diagnosing breast cancer abnormalities which can significantly decrease the mortality ratio from 30% to 70% [18].

Recently, various machine learning (ML), artificial intelligence (AI), and neural network schemes are exercised for image processing. The key achievement of the CAD system is to build an authentic and reliable system that can limit experimental oversights and can assist in separating benign and malignant lesions with higher accuracy. These systems are used to enhance image quality for human judgment and to automate the readability process of images for better understanding and interpretation. Currently, various articles on breast cancer detections, segmentation, and classification using ML and AI techniques have been published [18]–[20]. Most of the previous studies emphasized ML schemes using binary classification for the detection of certain cancer like lung cancer, brain cancer, skin cancer, stomach cancer, kidney cancer, and breast cancer.

Jaffar *et al.* [21] and Khan *et al.* [22] proposed a novel deep-learning-based model for breast cancer screening and classification using mammographic images. Qiu *et al.* [23] proposed a technique based on deep learning methods that classify the breast masses without lesions segmentation and feature selection. Samala *et al.* [24] performed breast cancer binary classification by reducing the computational complexities of all types of mammographic images. Nascimento *et al.* [25] extracted the morphological features from ULS images using binary classification. Youk *et al.* [26] proposed a new ULS technique named as Elastography to differentiate the benign and malignant lesions of breast cancer. The authors [27], [28] developed deep-learning-based techniques for suspicious ROI segmentation and classification using MRI modalities. Rasti *et al.* [29] developed a robust DL model for ROI segmentation and breast tumor classification using segmented DCE-MRI images. De Nazar *et al.* [30] proposed a model by selecting the variable value of the threshold for the segmentation of breast masses. Choi *et al.* [31] designed a CAD model to extract the ROI before the breast cancer

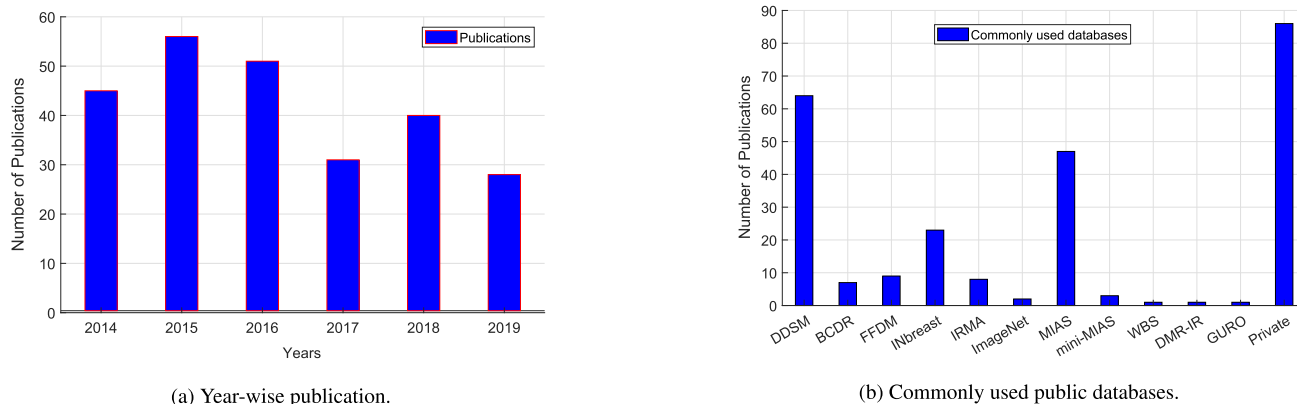


FIGURE 2. (a). Year-wise publication of articles with breast cancer keyword. (b). Distribution of public databases in the selected study used for breast cancer classification.

classification. The ROI extraction is the seclusion abnormal breast tissues from irrelevant regions that increase the accuracy and also the big number of images needed for training and testing. Casti *et al.* [32] used QDA-LDA model for auto-localization and classification of asymmetry ROI because it directly related to the accuracy of doctor's predicting and treatment Nahid *et al.* [33] proposed an approach that extracts ROI patches from HP images for the classification of invasive and noninvasive breast cancer by CNN. Bejnordi *et al.* [34] and Feng *et al.* [35] performed a biopsy to classify the breast WSIs into different categories through the deep-convolution neural network and achieves the highest accuracy in binary-classification of cancerous slides. Punitha *et al.* [36] used the depigmentation technique to overcomes the merging of the neighbor region problems that almost have similar properties. Strange *et al.* [37] focused on the classification and distribution of microcalcification based on the topological model and morphological aspects.

The key objective of this review to assists the researchers in developing a novel and robust CAD tool which is computationally efficient and can help radiologist during the classification of breast abnormalities. This comprehensive review has exploited key research directions based on various multi-image modalities, image segmentation approaches, feature extraction techniques, types of DL and ML algorithms, and performance parameters used to evaluate the classification models. Statistical analysis of CAD systems considering different aspects is also highlighted through graphical and tabular representations. Following are the key research findings:

As per literature, it is observed that there are huge variations in shapes of breast (abnormal) tissues, so the benchmarks can be taken off during the screening process. The micro-calcification morphology is another significant factor for defining ROI, which is based on the distance between each micro-calcification. A fixed-scale approach is based on the distance between individual calcification used for defining the micro-calcification cluster while the invariant-scale

is a pixel-level novel approach that visualizes the various morphology aspects (i.e., calcification cluster shape, size, density, and distribution) to the radiologist. Furthermore, histogram-based methods and selection of optimal threshold is an efficient approach for the segmentation and classification of masses and calcification. From literature, it is also evident that none of a study has implemented this approach before. A novel CAD system needs to be developed based on this approach to classify the calcification and masses. A content-based image retrieval is a new approach based on mammogram indexing and ROI patches classification. From literature, it is found that none of a study used indexing on ROI patches to classify calcification and mass using a mammogram. However, indexing and ROI classification-based CAD system needs to be developed with the help of expert radiologist to get precise results. Furthermore, some challenges faced by DL algorithms for breast cancer diagnostics are related to ultrasound images because of its low signal-to-noise ratio (SNR) comparative to others. However, echogram is a new ULS imaging technology, which is much cheaper for breast screening. So, the development of a new DL algorithm is a significant task to break through the echogram image analysis. The CT or MRI image modalities are spatial 3D data which are very large in size and need higher computation resources. However, the design of light models is an interesting research direction for training and inferencing.

After this introduction section, the rest of this paper is organized systematically and is as follows. Section II presents the searching process, CAD system for the detection of breast cancer abnormalities (masses and calcification). Section III explains the breast cancer digital repositories. Section IV discusses briefly machine learning schemes for breast lesions diagnostics. Section V discusses briefly deep learning schemes for breast lesions diagnostics. We make a discussion on the open subjects and perspective issues in the research of breast cancer in section VI. Finally, research is concluded and highlights future research directions and challenges in section VII.

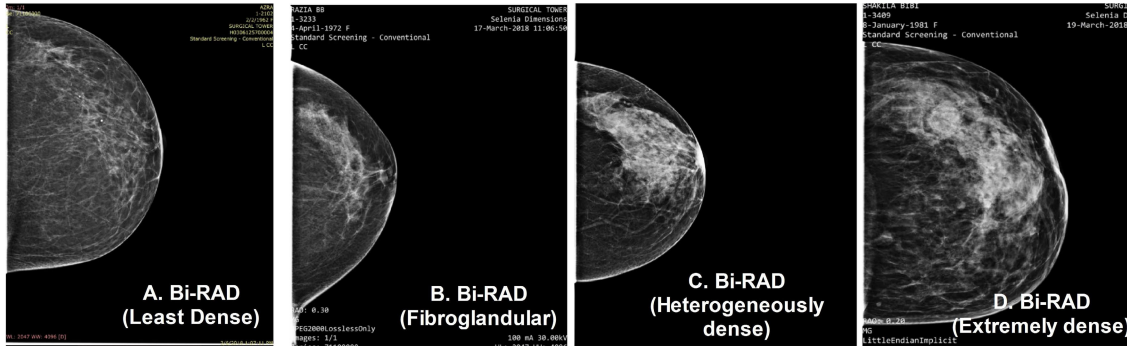


FIGURE 3. Bi-RADS breast composition categories. (a) Pre-dominantly fatty, (b) scattered fibroglandular, (c) heterogeneously dense, (d) extremely dense.

II. MATERIALS AND RESEARCH METHODOLOGY

This section explains the searching and selection criteria of articles relevant to breast tumor prognosis through deep learning techniques using different multi-image modalities. [38], [39].

A. SELECTION CRITERIA FOR RELEVANT STUDIES

The primary concern of this research is to find the answer to queries relevant to the classification of breast cancer through deep learning schemes using various multi-imaging modalities. The following queries are considered while designing this comprehensive study.

- 1) Types of imaging modalities recently used for breast cancer classification.
- 2) Types of the dataset (publicly and private) used to build deep learning classification models.
- 3) Types of DL and ML classifiers were recently used for breast cancer classification.
- 4) Challenges faced by the classifiers in accurately detecting masses.
- 5) Types of parameters used to evaluate breast cancer classifiers.

Based on above-mentioned research concerns, various well-known databases which include Science Direct, Web of Science, Scopus, MEDLINE via PubMed, Springer, IEEE Xplorer, Google Scholar, etc are explored using breast or breast cancer keyword in conjunction with mammography, ultrasound, MRI, CT scan, biopsy histopathological images for suspicious mass detection, diagnosis, processing, multi-classification through CAD, (ANN, CNN, KNN) DL schemes and (DT, NB, LR, SVM, RF, LDR) ML schemes, etc. Later, based on the scrutinizing and selection criteria mentioned above, 252 most relevant articles published between 2014 to 2019 are selected and its year-wise distribution is presented in (Figure 2a).

B. CAD SYSTEM FOR BREAST CANCER DIAGNOSES

Computer-aided-detection systems act as a second reader for the detection of lesions which may show the existence of breast cancer and radiologist made the final

decisions [40]–[42]. The primary aim of the CAD system is to diagnose the suspicious area of the breast and mark the regions of interests which can be lesions. Zemmal *et al.* [43] and Saraswathi *et al.* [44] revealed that CAD detection systems have enhanced the accuracy of the radiologist for the detection of breast cancer. This section discusses the methodologies for the screening of breast cancer through CAD.

1) BREAST CANCER SCREENING

Primary concerns of breast cancer are unknown but it exhibits serious complications based on gender, age, and genetic history of patients [19]. Early detection of the breast tumor is treatable due to its small size and can improve the surveillance of patients. Moreover, the proficient judgment and assessment of breast cancer based on breast density help the physicians for the detection of masses and calcification as shown in (Figure 3). Breast cancer screening based on the appearances of cancer symptoms recommended by the American Cancer Society is presented in (Table 1).

TABLE 1. Recommended mammography screening.

Age	Recommendations for Screening
40-44	To start breast screening yearlywise
45-54	Should be breast screening every year
55-above	If health is good, screening either after two year or yearly basis (women choice)

C. CURRENT MEDICAL IMAGING MODALITIES

Breast screening refers to the use of medical multi-image modalities for the detection of breast abnormalities, so the early diagnosing can prevent cancer from proliferating [45]. A variety of image modalities uses for breast cancer detection, however, few key factors such as FPs, cost-effectiveness, and workflow used for performance evaluation of image modality shown in (Figure 4a) In this section, we highlight a few current multi-image modalities used for breast cancer prediction through the CAD system as declared in (Figure 4b). The comparative analysis, ins and outs of different multi-image modalities are presented in (Table 2).

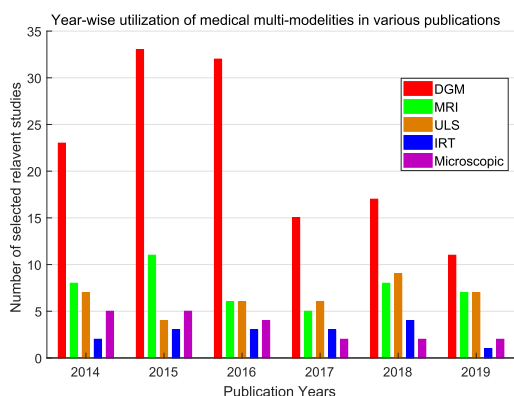
TABLE 2. Different medical multi-images modalities used for detection of breast cancer abnormalities.

Image Modalities	Applications	Strengths	Limitations
Mammography [30], [31], [55]–[65]	<ul style="list-style-type: none"> • First line of imaging modality for early stage diagnosing of Breast Cancer 	<ul style="list-style-type: none"> • Mammography screening is a low-cost, non-invasive, and comfortable examinations methods. • Effective tool use for the detection of calcification. • Calcification appears as white specks or shadow areas on a mammogram. • Double reading of mammogram increase in sensitivity and specificity. 	<ul style="list-style-type: none"> • Not suitable for dense breast cell because cancerous lesions or noncancerous can be misinterpreted. 10 to 30 % cancer cell not detected. • Radiation pass through the small masses causing high risk • Impure image contrast • Difficulty in visual perception for Radiologist.
Magnetic Resonance Imaging (MRI) [19], [56], [57], [66]	<ul style="list-style-type: none"> • Recommended for screening of dense breast abnormalities. • Investigate and measure the size of suspicious masses area observed in mammogram. 	<ul style="list-style-type: none"> • MRI is recommended for high risk breast cancer patient. • MRI recommended for inherited breast cancer patient with high sensitivity (78-98%) and low specificity (43-75 %). • Evaluate the size and location of suspicious area. 	<ul style="list-style-type: none"> • MRI is very difficult to understand due to several sections with pre & post-contrast injection. • More costly and not available easily like others. • High false-positive rates. • Highly skill radiologist may differentiate the malignant and benign lesion.
Ultrasound (Clinical BExam CBE) [19], [56], [57]	<ul style="list-style-type: none"> • Feasible for dense and soft breast tissue • To detect and discriminate the malignant and benign tissue and also avoid from unnecessary biopsy. 	<ul style="list-style-type: none"> • Can be used for biopsy guideline and identification of mass location. • Highly sensitive and Non-invasive • Feasible for dense cell in young women. 	<ul style="list-style-type: none"> • Much cancerous masses and calcification cannot be observed in Ultrasound. • Needs expert radiologist due to real-time examination of breast abnormalities. • Cost-effective and less sensitive than others.
Infrared Thermography (IRT) [55]	<ul style="list-style-type: none"> • Use for muscle tissue 	<ul style="list-style-type: none"> • Non-invasive 	<ul style="list-style-type: none"> • Impure image contrast • Difficulty in visual perception for radiologist due to image low quality and low resolution.

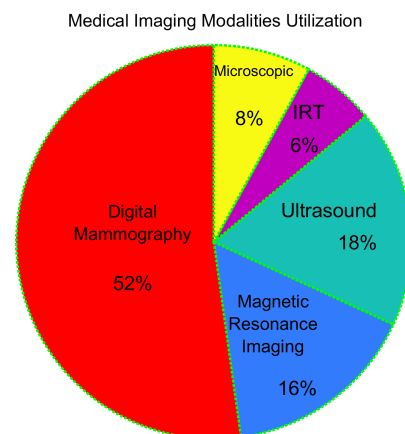
1) DIGITAL MAMMOGRAPHIC IMAGE (DMG)

Mammography is a low dose x-ray image modality used to classify the subtle changes in breast tissues using the CAD system. The x-ray beam easily travels in fibro-glandular tissues of the dense breast to examine the mass and calcification that is a prominent sign of breast cancer [46], [47]. The contrast between the mass and calcification is almost very less, morphologically diverse, and extremely irregular which is difficult to diagnose clinically. However, DMG images used two ways for breast cancer screening. In the cranial-caudal view, the complete breast with all glandular tissues is examined. The fatty tissues are visible in the dark strip and the nipple is depicted in the contour. Moreover, mediolateral oblique is the 90-degrees projection in which breast tissues are outside breast quadrant where axilla can be imaged [20], [21], [48]. The advantages and limitations of DMG for breast cancer diagnosing are presented in (Table 2). DMG images are distributed into three types such as: 1.) Screen film mammography (SFM), has primary advantages because it is directly printed on a huge film. The authors Khan *et al.* [22]

and Dhunge *et al.* [49] proposed a novel model for breast cancer screening, segmentation and classification (normal, abnormal, benign and malignant) using SFM. 2). Full-field digital mammogram (FFDM), most prominent technology has good image contrast, efficient processing, and easily available at publicly dataset. Carneiro *et al.* [50] design a model using FFDM to classify the segmented maps into normal and abnormal breast lesions. Qiu *et al.* [23] proposed a holistic approach to classifying the breast masses without lesion segmentation and feature selection. 3). Digital breast tomosynthesis (DBT), is the most advanced 3D technology that takes many breast images with different angles and integrates. Samala *et al.* [24] implements a model for breast mass classification by reducing the computation of all types of DMG, like DBT, SFM, and FFDM. Apart from the popularity of mammogram, in few cases, dense breast tissues remain invisible during the screening that leads to misinterpretation of the cancerous area that increases the FN ratio. In this case, the radiologist refers to the ULS, MRI, CT, or biopsy for better diagnosis.



(a) Year-wise utilizations of image modalities.



(b) Percentage utilizations of imaging modalities.

FIGURE 4. (a). Year-wise commonly used medical multi-image modalities for the diagnosing of breast cancer. (b). Different medical multi-image modalities used for different CAD system for early detection, segmentation and classification for breast cancer.

2) ULTRASOUND (ULS)

ULS is a noninvasive modality for fast visualization and diagnosing of breast tissue. ULS uses the high-frequency sound-waves for intrinsic analysis of breast tissues including chest wall without radiation immersion like in DMG and MRI [28]. Doctors often refer to ULS tests to examine the noninvasive breast cancer (mass or cyst) and also used to find breast abnormalities such, swelling, pain, and breast infection [51], [52]. Abdel-Nasser *et al.* [53] found that ULS is the best choice for diagnosing of dense, fatty, and thick breast tissues instead of using DMG. The detail of the advantages and disadvantages using ULS image are discussed in (Table 2). Nascimento *et al.* [25] extracts the morphological features from ultrasound image and perform the binary classification through deep learning method. Youk *et al.* [26] proposed Elastography, a newly developed ULS technique to differentiate the benign and malignant lesions based on tissue stiffness or hardness.

3) MAGNETIC RESONANCE IMAGING (MRI)

MRI is a diagnostics image modality that uses strong radio waves and magnetic fields to capture the 3D image of breast tissue and display it in a clear view than DMG, ULS [28]. The ins and outs of MRI for diagnosing of breast cancer as in (Table 2). Doctors usually refer to MRI to get detail information when cancer has been diagnosed. MRI machine takes many breast images with different angles and integrates. However, MRI leads to breast biopsy after diagnosing the suspicious regions. Amit *et al.* [27] developed a robust deep-learning-based model for suspicious ROI segmentation and classification of breast tumors using MRI images. R. Rasti *et al.* [29] extracted features from segmented ROI and feed into ANN, CNN for detection, and multiclassification of breast cancer. Bevilacqua *et al.* [54] developed the DL model for ROI segmentation and classification using segmented DCE-MRI images.

4) HISTOPATHOLOGICAL IMAGES (BIOPSY)

Biopsy imaging is a breast tissue analysis approach for the screening of breast tumor, therefore, many researchers use HP images for precise classification [34], [35]. Soft tissues are often taken from suspicious areas and fixed on microscope slides. The stained microscopic slides are examined by a pathologist and changed into WSIs (digital-color-images). The experts used approaches to take out cells from a suspicious region are fine-needle aspiration (FNA), core needle biopsy, vacuum-assisted biopsy, and surgical biopsy (excisional or incisional). Nahid *et al.* [33] classify breast cancer into several categories instead of binary classification and WSI color images permit the creation of many ROI images that train the model. Shibusawa *et al.* [51] extract ROI patches from HP images to classify the invasive and noninvasive breast cancer. Auto-classification of breast tumor through HP images has many advantages over DMG, ULS and MRI as in (Table 2).

D. CAD FEATURES FOR MASS AND CALCIFICATION DETECTION

There are mainly three early signs of breast cancer visible during the screening of mammogram images that are discussed comprehensively in this section.

1) CALCIFICATION

The detection of calcification is the primary foci of screening and has led to the development of CAD system [67], [68]. Calcification found in two types: 1). In Macro-calcification, a larger deposit of calcium in breast depending on age is foreseen, which is often non-cancerous [69]. 2). In Micro-calcification, there are small spots of calcium that appears in the form of cluster. In most of the cases, the number of calcium cluster are cancerous or malignancy. The microcalcification considered a malignant tumor and it seems like 3-5 clusters occupied in 1cm² area [70], [71]. The benign

TABLE 3. The details of publicly datasets was extracted in the relevant publications.

Dataset Name	Img type	Img format	Img mode	Img view	Img cat	img finding
MIAS (Mammographic Image Analysis Society)	DMG	.pgm	Digitized film mammography images	MLO	Nor, Ben, Mlg	All types of lesions and masses
DDSM (Digital Database for Screening Mammography)	DMG	.jpeg	Digitized film mammography images	CC, MLO	Nor, Ben, Mlg	All types of lesions and masses
WBC (Breast Cancer Wisconsin)	FNA	.csv	Digital mammography images	CC, MLO	Ben, Mlg	All types of lesions and masses
INbreast	DMG	.dicom	Digital mammography images	CC, MLO	Nor, Ben, Mlg	All types of lesions and masses
BCDR (Breast Cancer Digital Repository)	DMG	.tiff	Digitized film mammography images	CC, MLO	Nor, Ben, Mlg	All types of lesions and masses
Banco Web	DMG	.tiff	Digitized film mammography images	CC, MLO	Nor, Ben, Mlg	All types of lesions and masses
mini-MIAS	DMG	.pgm	Digital mammography images	CC, MLO	Nor, Ben, Mlg	All types of lesions and masses
BICBH	DMG	.tiff	Digital images	CC, MLO	Nor, Ben, Mlg	All types of lesions and masses
BreakHis(Breast Cancer Histopathological Database)	FAN	.png	Digital mammography images	CC, MLO	Ben, Mlg	All types of lesions and masses
CBIS-DDSM (Curated Breast Imaging Subset of DDSM)	DMG	.dicom	Digital images	CC, MLO	Nor, Ben, Mlg	All types of lesions and masses
PLCO Breast Dataset	.CSV	.sas	Digital mammography images	CC, MLO	Nor, Ben, Mlg	All types of lesions and masses
IRMA (Image Retrieval in Medical Applications)	DMG	.png	Digitalized x-ray film	CC, MLO	Ben, Mlg	Content based image retrieval

and malignant micro-calcifications are shown in **(Figure 1b)**. Strange *et al.* [37] developed the microcalcification topological structure at an invariant scale to classify benign and malignant calcification.

2) BREAST CANCER MASSES

Breast mass is a group of tissues occupied by lesions which are considered as a prominent sign of breast cancer. Mass could be malignant or benign based on a morphological structure like density, shape, and margin characteristics. The ROI segmentation process is based on the shape and size of masses [71]. Benign masses (cyst) are often found in oval, lobular, and round shapes having smooth boundaries while the malignant have irregular edges with ill-defined speculated margins. The radiologist may propose additional breast tests based on the size and shape of the masses. Abdel-Nasser *et al.* [72] proposed a mass segmentation technique based on mass size and shape to detect the ROI and breast abnormalities.

3) ARCHITECTURAL DISTORTION

Architectural distortion includes the healing of the previous biopsy after injury, so it is very difficult to diagnose the injured area. It can be malignant or benign cancer and commonly considered the third mammographic signs of breast cancer. De La Rosa Toro *et al.* [73] proposed the architectural distortion model to classify breast cancer abnormalities.

4) SPICULATE LESIONS

A lesion with ill-defined margin appears in star-shaped which is mostly found in malignant cases. The speculated lesions are characterized as benign when the low-density spicules occur in the loose structure and low-density area. Zwiggelaar *et al.* [74] use the linear structure of the spiculated lesions to identify the breast abnormalities.

III. BREAST CANCER DIGITAL REPOSITORIES

This review presented exploit some knowledge based on multi-image modalities and other information of the same patient that help in the reduction of false-positive results using auto-system. In all datasets, DMG and MRI images are used widely while ULS, IRT, and microscopic are used limited for breast cancer prediction. From literature, it is found that mammography databases play a significant role in training, testing, and evaluation of DL schemes. The comparison of public datasets based on origin, image size, image views, image format, image mode are presented in **(Table 3)**. Commonly publicly available datasets are BCDR [58], MIAS [59], DDSM [60], Banco Web, mini-MIAS [72], WBC [75], IRMA [76], INbreast [77], BICBH and BreakHis used extensively and their distribution declared in **(Figure 2b)**. The public datasets present a mixture of normal, benign, and malignant annotated images and also extensive variability of patients cases. Many existing studies use publicly databases [28], [45], [58], [78], [79] however, a few authors uses private [51], [80], [81] which collected from research centre or hospitals.

IV. MACHINE LEARNING MODELS FOR BREAST LESIONS DIAGNOSTICS

Mammography and fine needle-aspiration are well-known procedures used for breast lesions grading and infiltration of other body organs but both techniques suffer from false-(positive and negative) limitations due to misinterpretation by experts [82]. However, Machine Learning (ML) based on developing techniques helps in the intelligent automated identification of breast abnormalities, finding useful and hidden information that improves the tumor prognoses capability by reducing the diagnosis errors. Furthermore, ML-based techniques can provide judgment support to experts for an opportunity of the initial prognosis of breast tumors. Several machine learning techniques applied in the retrospective studies for the prediction of breast abnormalities, mass segmentation, and classification using pattern recognition [83], [84]. The most commonly used machine learning techniques discussed in this study are, Support Vector Machine (SVM), K-Nearest Neighbour (KNN), Random Forest (RF), Naive Bayes (NB), Decision Tree (DT), Logistic Regression (LR), Fuzzy Method, Linear Discriminant Analysis (LDA), AdaBoost. The contribution of each aforesaid ML techniques and comprehensive analysis are presented in (Table 5).

The Support Vector Machine (SVM) is a supervised machine learning (ML) classifier that provides high Accuracy (Acc), Sensitivity (SN), and Specificity (SP) in breast tumor classification as compared to other algorithms. SVM has a prominent advantage in theoretical research in recent years. SVM classifier is widely used for breast cancer identification, ROI segmentation, feature extraction [30], [31], [46], [58], [59], [68], [75], [85]–[88]. In this study, 63 publications used SVM classifiers for breast cancer diagnoses that are 27% of the selected studies. Ul Haq *et al.* [89] designed the SVM based model to classify and segment the malignant and benign candidates by using feature selection mRMR (Minimal-Redundancy Maximal-Relevance) algorithm and Chisquar FS algorithm. The results reveal that SVM shows high performance due to suitable features segmentation (18 features) from the WBC database and obtained 99.71% accuracy. Wajid and Hussain *et al.* [90] explored the SVM model to distinguish between breast abnormalities (mass and calcification) using data preprocessing techniques such as CLAHE, Histogram equalization, and obtained maximum 99% accuracy. In many studies, support vector machine works with the association of other classification techniques such TSVM [43], PSO-SVM [59], Linear Proximal SVM, Lagrangian-SVM, Smooth-SVM, Finite Newton-SVM [75], Successive-Enhancement Learning-based weighted Support-Vector-Machine (SELwSVM) [91] to attain more promising results.

K-Nearest Neighbor is one of the top ten algorithms because of its intuitiveness, simplicity, effectiveness, and a supervised ML technique. It widely used in breast cancer detection, segmentation and classification [51], [68], [87], [92], [93]. KNN focus on the correctness of classification by calculating neighboring distance using K-NN values. This

study consist of 21 KNN based publications which is 8% of the total reviewed studies. Ali *et al.* [94] employed the efficient tetrolet transform and KNN algorithm to classify breast cancer into cancerous and non-cancerous using mammograms. The tetrolet transforms decomposed the mammogram into sub-bands to extracts the energy-based features that serve as input to KNN classifier which obtained 92% accuracy. Raghavendra *et al.* [87] proposed KNN method for automatic identification of breast lesion and Gabor wavelet for feature extractions from a mammogram which achieved 98.69% accuracy.

Random Forest (RF) is a kind of bagging integration method that used a decision tree as an individual learner [58], [95], [96]. It performs more precisely on the test set than a single algorithm and has a certain advantage in anti-noise capability on other algorithms. This study consist of 16 publications that used RF that is 6% of total reviewed studies. Wang *et al.* [97] proposed an improved random-forest-based rule extraction method (IFGRE) which derives the interpretable and precise extraction rule for breast tumor diagnoses using WDBC and WOBC dataset. The patient data are registered by the SEER program such as sex, birth date, tumor site, diagnostic stage, tumor morphology. The experimental results show that IFGRE obtained 99% accuracy. Abdel-Nasser *et al.* [53] presented the Random Forest algorithms to segment and discriminate of breast masses using ultrasound modality. GLCM feature, binary pattern, and ROI extracted using five methods which obtained 97.33% accuracy and 99% AUC.

Naive Bayes (NB) classifier is a probabilistic machine learning algorithm based on the Bayes's Theorem. Naive Bayes extensively used in sentiment predication and classification of breast masses [58], [87]. NB randomly measures the probabilities of pattern recognition for a specific task that computes the results based on some observation. This review consists of 11 NB based articles that are 4% of the reviewed studies. Chen *et al.* [98] proposes a selective Navies Bayes (SNB) algorithm for efficient selection of attributes to classify the breast masses and improved the mass prediction accuracy. Abdara *et al.* [82] proposed the nested Ensemble (SV BayesNet and SV-Naive BayesNet 3-Meta Classifier) techniques that used stacking and voting method for automatic identification of benign tumor from malignant lesions. The proposed model improves the performance of the prognostic system and obtained 98.07% accuracy.

Decision Tree (DT) classification aims to estimate the discrete value of the objective functions. DT is a supervised machine learning method that has high rule induction ability and fast breast cancer classification speed [68], [87], [95], [96]. DT classifies the big data to discover the potential value after training the DT function. DTN uses a tree for mapping the relationship between classification attributes and results. In this review, 12 articles used DT classifier which is 5% of selected studies Suresh *et al.* [99] presented a hybrid model for forecasting of misclassified malignant lesions based on decision tree algorithm and radial-based function

that achieved overall 99% accuracy. Raghavendra *et al.* [87] developed a model to segment the breast masses automatically and used Gabor wavelet for feature extraction from breast images which achieved 96.52% accuracy.

Logistic Regression (LR) model is widely used for binary classifications and also in practical problems such as mass segmentation and classification of breast tumor [100], [101]. The LR function provides a universal and convenient method for the detection of breast cancer. This paper consists of 09 articles that used the LR model which is 4% of reviewed studies. Sultana and Jilani [102] used the LR model to predict the various classes of breast tumors by extracting hidden information pertaining to several types of attributes that achieved 97.18% accuracy and 0.99% AUC. Dhahri [103] developed ML techniques to discriminate the breast tumor based on fracture selection using WDBC datasets and achieved 92% accuracy.

Fuzzy method dividing the large numbers of objects into different classes based on their similarity. Classes are arranged based on similarities between objects in the same class. Different similarity criteria are based on the type of objects which include Euclidean distance and cosine similarity. Fuzzy-C Mean is one of the leading clustering methods which widely used for breast cancer classification [60], [61], [69], [104]. In this study, 12 publications used fuzzy (fuzzy c-mean) algorithms that are 5% of the total reviewed studies. Shrivastav *et al.* [105] designed a novel edge detection method based on a fuzzy rule base system. The proposed model consists of three steps, input variable (gradient vector), set rule (Gaussian and triangular membership-function), converting output (demulsification method) used to achieves the maximum accuracy. Mohammad and Al-Ani [106] developed Fuzzy based model for accurate segmentation of complicated medical images to get the required features and pattern which performs accurate segmentation by changing parameters.

Linear Discriminant Analysis (LDA) is a classic subspace-based and effective feature extraction method that is used to extract a feature vector from a suspicious breast region [68]. LDA is widely used for breast cancer prediction, face recognition, language processing, and other fields [32], [87], [107]. In this study, 14 articles applied the LDA classifier which is 6% of the selected studies. Mansour *et al.* [108] proposed a model BC-CAD that focus on tumor segmentation, ROI Localization, feature selection, characteristic extraction and grading of breast tumor using Histopathological images and achieved 96.70% accuracy.

AdaBoost cascading framework has a high reception and moderate error reception rate. In the cascading framework, front level classifiers are relatively simple in structure and use fewer features for classification [109]. AdaBoost filter the negative samples during sample discrimination, only positive samples are sent to the subsequent classifier for processing and negative samples are rejected directly. In this study, 6 articles used AdaBoost which is 4% of the reviewed literature. Zhen *et al.* [110] proposed a computational computer vision techniques deep-learning assisted efficient-Adaboost

(DLA-EABA) algorithm to characterize the breast masses, feature selection and extraction using multi-image modalities, and achieved 97.2% high-level accuracy.

In this study, some other supervised and unsupervised ML algorithms were also reviewed for breast masses prediction and classification. De La Rosa *et al.* [111] explored the Multiple Instance Learning (MIL) to discriminate the masses and calcification by extracting texture features and achieved 91.10% AUC. Mahersia *et al.* [112] presented Bayesian regularization Back-Propagation networks technique for auto-detection of breast masses which achieved 97.08% accuracy. Singh and Urooj *et al.* [65] proposed Adaptive differential Evolution Wavelet-Ann (Ada-DeWNN) model for texture feature characterization and feature extraction from ROI in mammogram which achieved 99% accuracy. Ribeiro *et al.* [81] developed the Optimum-Path Forest (OPF algorithm) for the identification and classification of masses present in the suspicious regions of the breast which achieved 99% accuracy. Nascimento *et al.* [113] developed Polynomial Classification Algorithm to classify the breast image into cancerous and non-cancerous based on texture point derived from ROI which achieved 98% AUC. Wu *et al.* [114] proposed Artificial Immune System (AIS) to discriminate against the breast tumor using texture, morphological feature extracted from ROI which achieved 96.67% accuracy.

V. DEEP LEARNING FOR BREAST LESIONS DIAGNOSTICS

Recent developments in computational techniques, significant advancement in image-processing technology, and prevalence of DMG images have opened the opportunity to resolve the early diagnosing of breast abnormalities using DL schemes [23], [115], [116]. The existing ML approaches are imperfect for precise detection of breast densities; however, the DL approaches to deliver the auspicious development in mass segmentation to overcome the false-positive ratio (FPR). Cai *et al.* [117] used well-known DCNN schemes to overcome the limitations of the CAD system for DMG diagnosing. This section comprehensively elaborates the study of DL schemes and (Figure 5) presents the analysis procedure of the CAD system for classification of breast abnormality.

A. IMAGE ACQUISITION

Many annotated images are required for the development of an efficient DL model which is difficult to meet practically; therefore manually splitting and labeling the picture, data-enhancement, preprocessing needs for implementations [118]. Initially, the capture mammogram is converted to a portable gray format that does not obliterate the data when it is compressed. The image itself has no label and semantics. It must be segmented and labeled manually before it is used. However, images collected in reality often have certain disadvantages that affect the quality of the feature extraction [119].

B. DEEP LEARNING IN IMAGE PRE-PROCESSING

With the rapid development of imaging technology, a massive number of medical images are available [64], [120].

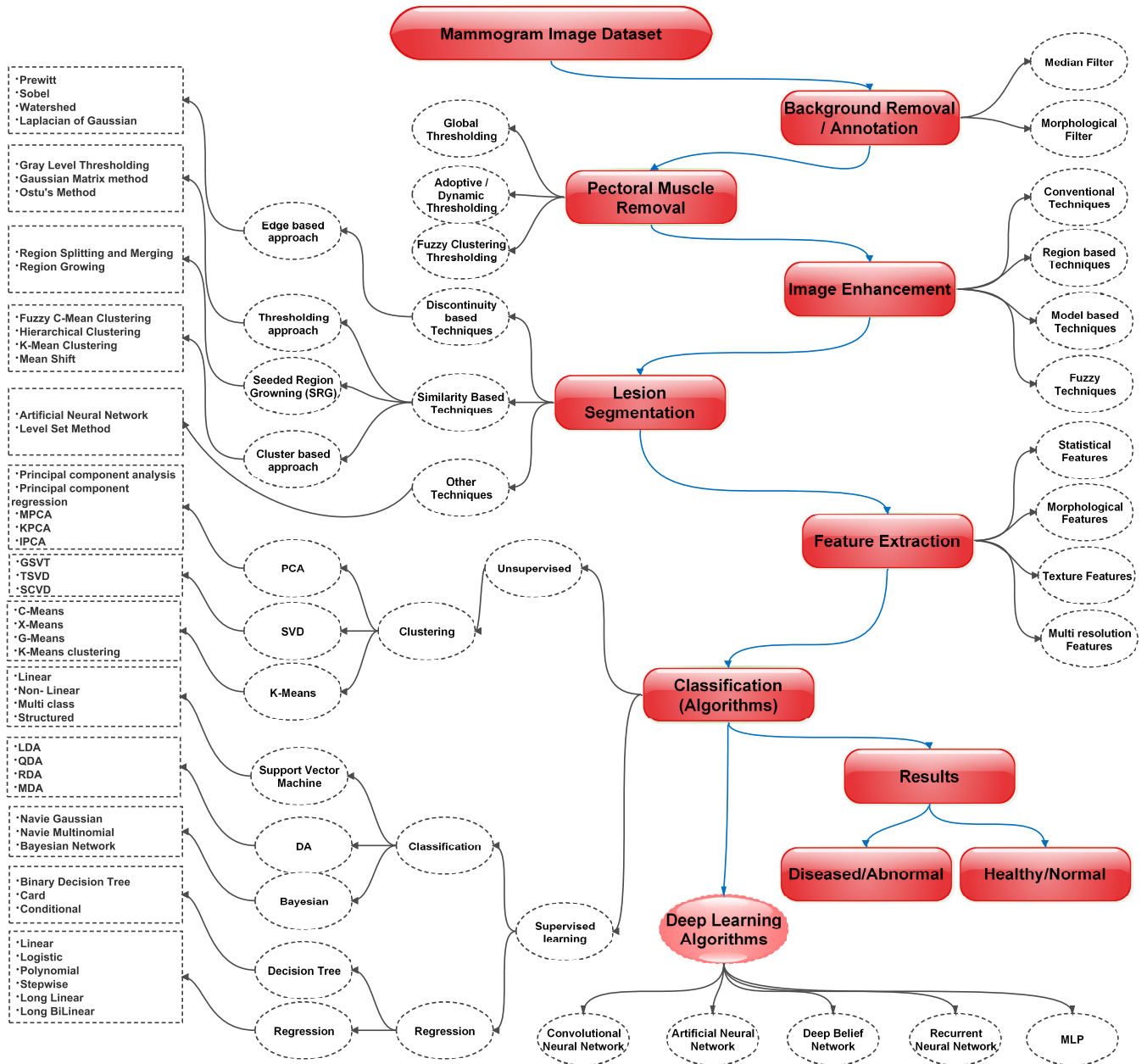


FIGURE 5. Analysis procedure of a CAD system for the classification of breast cancer abnormalities.

Preprocessing of medical images is an important task before training DL schemes that include augmentation, ROI segmentation, resizing, image enhancements, cropping, noise removing, and feature reduction.

The distribution of CAD tasks in which a total 93 of studies (out 252) performed multi-preprocessing task for detection of breast lesions are presented in (Figure 9b).

Ahn *et al.* [78] and Duggento *et al.* [121] adopted augmentation to training the model and performing class-label prediction. The massive number of medical images is needed for the training of DL schemes, the augmentation

approaches such as geometric transforms, patch extraction, synthetic minority over-sampling, and noise addition used to increase the instances of images artificially for precise results. Choi *et al.* [31] developed a CAD system to extracts the ROI before the breast cancer classification. The ROI extraction is the seclusion abnormal breast tissues from irrelevant regions that increase the accuracy and also increase the number of images needed for training and testing. Casti *et al.* [32] used the QDA-LDA model for auto-localization and classification of asymmetry ROI because it directly related to the accuracy of the doctor’s predicting and treatment.

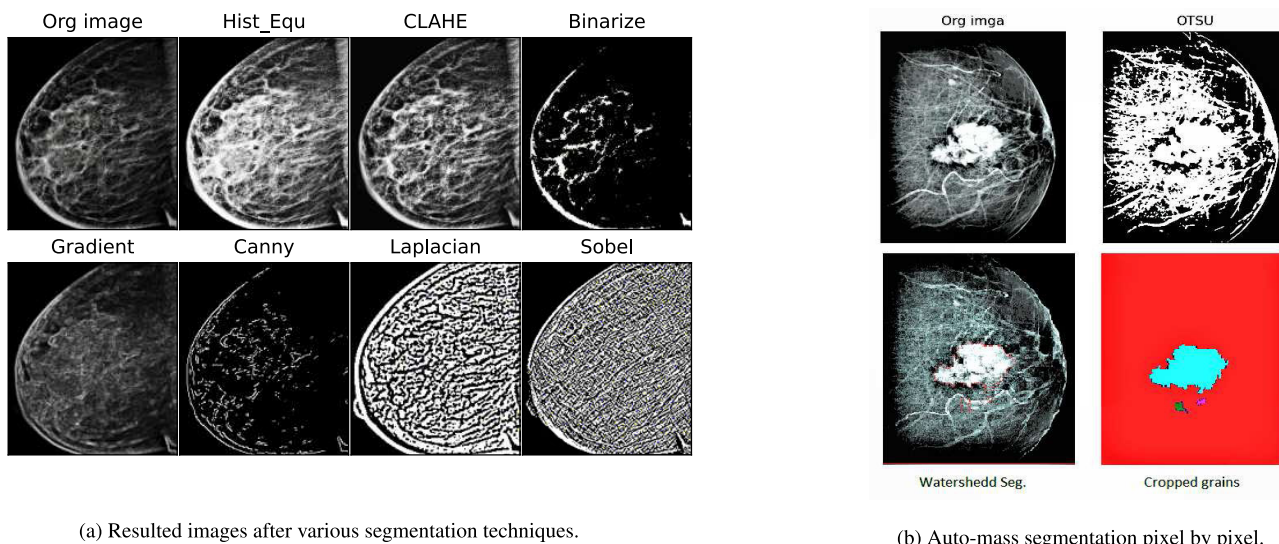


FIGURE 6. (a). Segmented version of breast tumor images employed to distinct breast region from the suspicious area that play prominent role in finding of calcification and mass with cleansing by edge detection, edge smoothness, removing noise, label removing and feature mapping. (b). Visualization of OSTU's thresholding and red contours denote automatic segmentation of breast mass region through watershed segmentation approach.

Wang *et al.* [107] used median filters for image smoothing to suppresses the noise and to reduce the edge blurring. Vijayarajeswari *et al.* [85] used mean filters to replace each pixel from its surrounding region. Peng *et al.* [64] used denoising filters to smooth the edges by denoise the edges of the image during the preprocessing.

C. DEEP LEARNING IN IMAGE SEGMENTATION

The breast segmentation involves removal of background region, pectoral muscles, labels, artifacts, and other defects add during image acquisition which disrupts the detection of breast abnormalities. The image segmentation split the digital mammography images into ROI patches to identify the breast abnormalities which is used for feature extraction as declared in (Figure 6a) and (Figure 6b). However, the bad segmentation leads to unprecise feature selection which provokes the wrong classification. The existing studies [59], [67] includes segmentation approaches such as threshold-based, split and merge, edge-based and region growing based presented in (Table 4). The mass segmentation includes the breast area segmentation based on intensity, texture, shape features and abnormalities segmentation.

Andropova *et al.* [28] and Oliver *et al.* [122] performs work on mass segmentation and computed the mass features with human intervention. The commonly used filters for contrast enhancement and noise reduction are mean, median, histogram equalization (HE), morphological method and contrast limited adaptive histogram equalization (CLAHE) that increase the readability of medical image as declared in (Figure 6a). De Oliveira [123] proposed SVM based method for mass classification based on the mass shape feature, texture feature, and intensity because it is not always possible

to extract the mass boundary clinically. Dhungel *et al.* [49] proposed a hybrid mass segmentation model comprises of DL module and TRW methods which decline the segmentation errors and provide precise results. Zhu *et al.* [124] proposed a multistage deep end-to-end learning model associated with FCN and CRF for the mass segmentation and ROI extraction in DMG.

1) REGION BASED SEGMENTATION APPROACH

Region-based segmentation approach based on pixel uniformity inhomogeneity region and similar features of the segmented area such as geometry, texture, and intensity. Liu and Zeng [86] used the region-growing approach for mass segmentation which required an initial seed point that merges all similar pixels within the mass region. The region-based segmentation formula presented in (Equation 1) and (Equation2).

$$R_1 + R_2 + R_3 + \dots + R_N = I \tag{1}$$

and

$$I - R_1 + R_2 + R_3 + \dots + R_N = \emptyset \tag{2}$$

Pratiwi *et al.* [120] proposed a model based on splitting techniques which divided the segmented image into sub-region until no further discrete regions are left. Jian *et al.* [125] proposed a merging segmentation approach that starts with seed point which increases the region by the accumulation of similar adjacent pixels. (Figure 7) shows the merging approach of the nearest pixel with the initial seed point. Punitha *et al.* [36] used the depigmentation technique to overcomes the merging of the neighbor region problems that

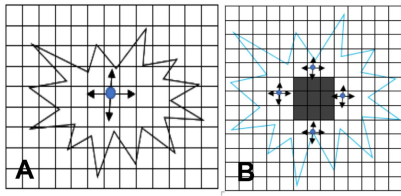


FIGURE 7. Region growing process: (A). initial seed point, (B). region growing processes with the possible number of grows.

almost have similar properties. (Figure 8) a, b, c, shows the splitting while d shows the similar merging region.

2) CONTOUR BASED SEGMENTATION APPROACH

In the Region-growing approach, an initial seed point is required that merges all similar pixels within the mass homogeneity region [62], [91]. The authors Diz et al. [58] and Wang et al. [107] proposed a method to detects the edges of the image which is nearest to the boundaries of segmented images. There are several edge-based image segmentation techniques such as GLCM, Logic filter, and Haralick descriptor. Peng et al. [64] perform the mass segmentation based on the CAD system to classify the breast lesions without considering the human intervention and initial seed point.

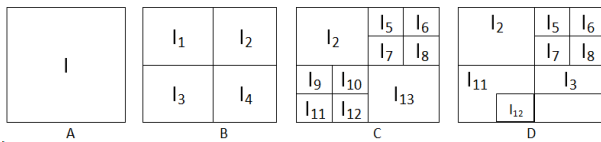


FIGURE 8. Region splitting process: (A). the initial image I containing all not identical pixels, (B). region I splitting into four sub-regions I2, I3 and I1, I4, (C). all sub-regions have identical pixels, (D). splitting the region I4 into I12.

3) THRESHOLD BASED SEGMENTATION APPROACH

It is a simplest approach used for foreground and backgrounds segmentations as declare in (Equations 3). Usually, the histogram-based method needs an optimal threshold value for the segmentation of objects. De Nazaré et al. [30] proposed a model by selecting the variable value of the threshold for the segmentation of breast masses.

$$\begin{aligned}
 & \text{if } I(x, y) \geq t, \text{ then} \\
 & \quad S(x, y) = 1 \\
 & \quad \text{else} \\
 & \quad S(x, y) = 0
 \end{aligned} \tag{3}$$

D. DEEP LEARNING IN IMAGE FEATURE EXTRACTION

Feature extraction is a classification step used for feature calculation of ROI with associated properties such as size, shape, homogeneity, and tissue density. The algorithm’s performance is based on features extraction and also enhance the classifier complexity with increasing the features to be

extracted. Mostly features are handcrafted based on radiologist experience however, auto-feature extraction of medical images is a common segment of CAD approach. Many feature selecting methods such as PCA, LDA, chi-square test, etc. used to reduce the redundancy and complexity of feature space. Similarly, the pathologists assign breast cancer grading by considering the cancerous features of the cell, nucleus size, nucleus shape, and cell division ratio [64]. The general comparison on feature extraction are presented in (Table 5).

Pak et al. [129] proposed a model that extracts histogram features to classify the lesions which include mean, standard deviation, skewness, entropy, and energy. It widely used some visual information in the image, such as color, shape, texture, and other information. Hamoud et al. [104] and Kallenberg et al. [130] extracted some textural features which include contrast, correlation, the sum of (average entropy, variance), entropy, homogeneity, maximum correlation coefficient, correlation, variance, inertia, inverse difference, entropy difference, variance difference. Sun et al. [131] used DLL techniques to extract geometric features such as size, circularity, sphericity, irregularity. Dhahbi et al. [92] used kinetics features to classify the lesions like uptake rate, wash-out rate, curve index, signal improve the ratio. Saraswathi and Srinivasan [44] used binary Object features to classify the calcification like are area, projection, centroid, thinness, and aspect ratio, perimeter, orientation. The overview of features extraction and features selections schemes explains in (Figure 5).

E. DEVELOPED MODELS FOR CLASSIFICATION OF BREAST ABNORMALITIES

Classification is a significant approach used for breast tissue detections and segmentations such as pectoral muscle, fibro-glandular tissue, and fatty tissue. The existing ML approaches are imperfect for precise classification of densities; however, the DL approaches to deliver the auspicious development in mass classification to overcome the false- positive ratio (FPR) [45]. However, the networks that work as feature extraction are trained with large datasets to perform data representation which refers to the classifier to achieve tasks. Ragab et al. [46] presented a novel DCNN approach for feature segmentation(Threshold and region-based) and ROI grading using digitized mammogram images. Ahn et al. [78] classified pre-segmented masses into dense and faty tissue using the transfer learning-based CNN method. Mammograms divided into patches using the data augmentation technique and achieved a 0.96% correlation coefficient. Kooi et al. [80] developed a deep conventional neural-network for the identification of the suspicious regions based on tissue densities and mass segmentation using a mammogram. Gaussian derivative filters are used for feature extraction that achieved 94% AUC, 92% accuracy. The most commonly used deep learning techniques are discussed in this review are, Convolutional Neural Network (CNN), Deep learning techniques (DL), Artificial Neural-Network (ANN).

TABLE 4. Strengths and limitations of various segmentation methods used for diagnosing of breast cancer abnormalities.

Methods	Method Descriptions	Strengths	Limitations
Edge Detection Methods [57], [126]	<ul style="list-style-type: none"> • EDM locates the point having minor or higher gray level changes and also reckon on discontinuity detection. • Edge-based approach used to point the sharp discontinuities and gaps in the medical image. • Recognition of human organs is the significant work of EDM. 	<ul style="list-style-type: none"> • EDM perceives easily and its working is best due to the finest contrast. • EDM is a structural approach to identify the edges with rapid intensity variation. • EDM is a manual suitable method that attains the finest image disproportional zone. • More convenient for ROI and its edges detection. 	<ul style="list-style-type: none"> • EDM is not suitable for unclear, undefined, and multiple edges images. • Causes less noise compared to other approaches. • Need some knowledge about the suspicious object property. • Noise sensitive and its working on low contract image is not good.
Histogram Thresholding Based Method [57], [127], [128]	<ul style="list-style-type: none"> • Histogram of the picture has numerous peaks that relate to a specific region. • Used to discriminate the foreground image most effectively from the background image. • Used for image complexity calculation and efficient working with low computation complexity. 	<ul style="list-style-type: none"> • Working well with complex image. • The threshold values selection depend on image pixel occupied by the specific area. • Threshold value needs information about intensity, size and object types exist in the image. • No need for image former information. 	<ul style="list-style-type: none"> • Histogram working is poor with noticeable peaks or with wide and even valleys. • Histogram does not imitate the realities. • It enables to guaranty about the contiguous partitioned regions. • Inefficient working with colour spectrum image.
Region Based Method [57]	<ul style="list-style-type: none"> • Seed points base pixel grouping in the homogeneous area. • Image subdivided with defined criteria like image intensity, color and texture into the similar area. 	<ul style="list-style-type: none"> • Efficient working with noise image. • Seed point is effective and substantial part for image segmentation. • Used for ROIs extraction and mass detection. 	<ul style="list-style-type: none"> • Seed point is more effective so the image segmentation depend on seed points. • Most expensive due to memory consumption and computation time.
Clustering Based Method [57]	<ul style="list-style-type: none"> • Categorization into specific cluster based on their characteristic and similarity. 	<ul style="list-style-type: none"> • Implementation of clustering approach is easy. 	<ul style="list-style-type: none"> • The cluster defining pattern is an issue.

Furthermore, the detailed contributions of each classifier are summarize in (Table 5).

Convolutional Neural Network (CNN) is a multi-layer supervised learning neural network extensively used for complex AI problems such as breast cancer prognoses, segmentation, classification, pattern recognition, and natural language processing [47], [78], [132], [133]. The structural design of CNN comes from the study of animal visual cortical cell activation. Training of Deep-CNN with a small amount of medical data using transfer learning and augmentation approaches is very challenging. Recently, CNN-based algorithms are developed by considering lesions description to enhance the abilities of experts to identify and precise analysis of the initial stage of breast cancer [36], [42], [116], [121], [124], [134]. The retrospective studies show that the CNN-based model has improved the accuracy and reduce the FPR for the detection of breast cancer. This review consist of 27 CNN-based publications applied for breast cancer prognosis which is out of 11% of selected studies. Benzebouchi *et al.* [135] present a novel

deep-learning-based CNN model for detection, localization of calcification, and breast masses using DDSM dataset and show remarkable performances for reducing of false-positive detection and obtained 97.89% accuracy. CNN also used with conjunction of several classifier such as Feed forward neural network (FFCN) [36], Fully-Complex Valued Relaxation Neural-Networks (FCRN) [44], Deep-CNN [62], [117], Transfer Learning-based CNN [78], Convolutional sparse autoencode (CSAE) [130], for breast tumor segmentation and achieved the high accuracy, specificity and sensitivity.

Deep learning (DL) is a core data analysis technology and has become mature in the field of data mining. DL technology resulted the promising performance in breast cancer recognition and classification [23], [49], [79], [118], [136]. The auto-feature extraction of lesions has great realistic significance so the DL algorithm is more effective for breast cancer identification. Recently, several deep learning models have been broadly categorized such as stacked denoising autoencoders (SDAE) [98], Principal component analysis-network (PCA-Net) [137] for feature extraction and segmentation.

TABLE 5. The systemic analysis on medical multi-image modalities for diagnosing of breast cancer abnormalities.

Imaging modality	#Image	#Classes	Method Used	Task Performed	Feature Extracted	Dataset Name	E. Matrix	Ref#
Digital Mammography	599	Mass, not mass	SVM	Automatic detection of Breast masses in mammographic images	Enhanced Image contrast by low pass filter and wavelet transform. Quality thresholding algorithm, segmenting the mass region, extracts shape, and texture feature.	DDSM	Acc=84.00, SN=92.39, SP=81.00, AUC=80.3	J.de Nazar et al. [30], 2015
Digital Mammography	429	masses, non-masses	SVM	Auto-detection and localization of mass suspicious regions	Texture and geometry feature extracted from segmented suspicious ROI through GLCM.	DDSM	SN=82.40,	X. Liu, et al. [86] 2015
Digital Mammography	2500	Normal, Abnormal	SVM	Classification of mammographic image to differentiate the normal and abnormal regions.	Manually image cropping. The statistical features such as mean, entropy and SD derived from ROI through DWT decomposition	DDSM	Acc=96	B. Sanae et al. [142], 2014
Digital Mammography	220	Normal, Benign, Malignant	SVM	Detection and classification of breast masses	The extraction of lesions occur manually and are categories in color, texture and shape by GLCM, HU Moments and central moments.	DDSM	Acc=89	N. Azizi, et al. [143], 2014
Digital Mammography	3404	Masses, Non Masses	SVM	Classification of lesions as mass or non mass	The classification and segmentation of suspicious areas using texture feature based on taxonomic diversity index and phylogenetic trees	DDSM	Acc=99.00, Sn=98.60, Sp=98.85	FSS de Oliveira et al. [123], 2015
Digital Mammography	200	mass, not mass (micro-calcification)	SVM	Detection of micro-calcification by cyclo-stationary signal analysis	Micro-calcification features detection based on cyclo-stationary signal analysis. Spectral-correlation is predicted for ROIs after 1D vectors conversion. Student t-test is working for feature selection	DDSM	Acc=94.44, SN=95.88, SP=93.10	Khalaf, A. F et al. [150] 2015
Digital Mammography	48, 200	mass, not mass (micro-calcification)	SVM	Detection of micro-calcification	HOS, DWT , WPD features for detection of micro-calcification are presented based on statistical analysis.	DDSM, MIAS	Acc=96,95 SN=98,96, SP=93,94, respectively	Khalaf, A. F et al. [151] 2015
Digital Mammography	303	Masses, Normal	SVM	Classification between mammographic masses and normal tissues	Various Feature such as texture, intensity, morphological, margin, and spiculation are extracted from the segmented ROI.	DDSM, Private	SN=93.2	J.Y. Choi et al. [31], 2015
Digital Mammography	—	Normal, Abnormal	SVM, MIL (Multiple Instances Learning)	Classification of breast lesions and micro-calcification.	Extraction of textural feature through GLCM, GLRLM	DDSM	AUC=75,74 global and 91,83 local respectively	G.Quellecet al [152],2016
Digital Mammography	1200	Fat areas, normal	SVM, SFFS	Detect and localize the fats areas, and define as benign, and malignant.	Detection, counting, segmentation, labeling and localize fat area pixel. Several features i.e shape, spiculation, contrast, calcification, texture, and density are computed.	DDSM	AUC=80.5	M.E. Elmannan et al. [67], 2014

Continued on Next Page ...

TABLE 5. (Continued.) The systemic analysis on medical multi-image modalities for diagnosing of breast cancer abnormalities.

Imaging modality	#Image	#Classes	Method Used	Task Performed	Feature Extracted	Dataset Name	E. Matrix	Ref#
Digital Mammography	—	cancerous, non-cancerous	AdaBoost-SVM	Diagnosing and classification of mass based on imblancing data-mining method.	Genetic model employed for preprocessing and reduction optimizing. Clustering-boundary handles the data imblancing and remove the noise.	DDSM	AUC=89	P. Li et al. [144], 2014
Digital Mammography	200	Normal, Abnormal(Malignant)	Semi-Supervised Support Vector Machine (TSVM)	Classification of normal and abnormal tissues in mammographic image	The detection of masses, its contour, and feature extraction using heterogenous families GLCM, HU Moments and central moments.	DDSM	Acc=93.10, Sn=83, Sp=89	N.Zemmal et al. [43], 2016
Digital Mammography	1318	Benign Malignant	CNN	detection and classification of lesion	ROI extraction through augmentation, re-scalings, and shear deformations	CBIS-DDSM	Acc=71.19, SN=84.40, SP=62.44 AUC=78.5	Duggento et al. [121], 2019
Digital Mammography	198	Masses, Normal	DCNN (Deep Convolutional Neural Network)	Mammographic image classification into mass and normal region	DCNN algorithms extracting generic features like edges or blob detectors that used in several task and to training dataset	DDSM	SN=89.90	Suzuki s. et al. [62], 2016
Digital Mammography	5257	Normal, Benign, Malignant	DCNN, SVM	DCNN and Alexnet is used for feature extraction and classification	Two segmentation approaches are used, ROI manually and splitting via threshold and region.	DDSM	Acc =87.20, AUC=94.00	Ragab, Dina A., et al. [46], 2019
Digital Mammography	300	Normal, Benign, Malignant	ACFNN and ACNN	Effectively detect, diagnose, and classify the breast tissues	Features extracted, mass geometry and size ie. circularity, mean, gradient, Fourier-description using CFS multivariate filter.	DDSM	Acc=94.99, SN=92.20, SP=95.30,	Abubacker et al. [60], 2016
Digital Mammography	400	Benign, Malignant	ANN	Improvement in CAD performance by utilization of unlabeled data through SSL	SSL algorithms use for labeled and unlabeled data collection. Data weighting, feature selection and data labeling used for efficient output.	DDSM	AUC= 84.10	Sun, Wen-qing, et al. [139], 2016
Digital Mammography	600	Benign, Malignant	Deep Neural Network	Breast abnormalities classification using mammographic images	Distinct features are extracted automatically through CNN	DDSM	Acc=96.7	Z. Jiao et al. [141], 2016
Digital Mammography	360	Normal, Abnormal	Polynomial Classification Algorithm	Classification of image into normal/binign or abnormal/malignant tissue	Multi-resolution features based analysis on texture points are derived from ROIthrough different wavelet functions.	DDSM	AUC=97.99	M.Z. Do Nascimento et al. [113], 2014
Digital Mammography	720	Normal, benign, Cancer	Multiple Instances Learning (MIL)	Classification to recognized benign and cancer tumor	Textural features Extraction from the anomaly detection of masses and micro-calcification.	DDSM	AUC=91.10	Ruben.S et al. [111], 2015
Digital Mammography	330	Normal, Abnormal (Benign, Malignant)	RBFNN (Radial Basis Function Neural Network)	Classification of Breast lesions as Normal/Benign and Abnormal/Malignant	In preprocessing, ROI selected by cropping and re-sizing of image. GLCM method used for Texture feature evaluation from the mammogram image	DDSM	Acc=94.00 SN=97.10 SP= 91.49	Pratiwi, Mellisa et al. [120]2015, 100

Continued on Next Page ...

TABLE 5. (Continued.) The systemic analysis on medical multi-image modalities for diagnosing of breast cancer abnormalities.

Imaging modality	#Image	#Classes	Method Used	Task Performed	Feature Extracted	Dataset Name	E. Matrix	Ref#
Digital Mammography	300	Benign, Malignant	FGMM (Fuzzy Gaussian Mixture Model)	Detect and classify the suspicious areas of mammographic images into cancerous and noncancerous	Intensity, shape, and texture feature are extracted	DDSM	Acc=93.01 SN=90.20 SP=96.02	Aminikhanghahi et al. [61], 2017
Digital Mammography	108	Benign, Malignant, Normal	Fuzzy C-Means (FCM)	Detection and classification of masses into benign, malignant, and normal tissue	Textural features extracted from the segmented areas through Zipf and inverse Zipf	DDSM	Acc=87, SN=90, SP=84	M.Hamoud et al. [104], 2015
Digital Mammography	252, 11553 cases	Normal, malignancy	KNN	Distinguish between normal/benign and abnormal/malignant breast tissues	Cervelat transform, skewness and kurtosis used for feature calculations and t-test ranking technique select the optimal feature	DDSM, Mini.MIAS	Acc=91.27 SN=1.35, AUC=98.9 84.10 respectively	Dhahbi S. et al. [92] 2015 96
Digital Mammography	220	Normal, benign, benign without callback	Random Forest	Auto-segmentation and classification of masses	Auto ROI segmentation, Mass shape (round, oval, lobular, and irregular) and mass margin (circumscribed, obscured, micro-lobulated, indistinct, and spiculated) are extracted.	DDSM, MIAS	Acc=98.00, SN=93.00, SP=97.00, AUC=95.05 respectively	M. Dong et al. [149], 2015
Digital Mammography	94 both dataset	Benign, Malignant	Quadratic Linear Analysis (QDA-LDA)	Auto-localization and classification of asymmetry cites of mammographic image	Bilateral masking used for enhancement of image.	DDSM, MIAS	Acc=79,75 Sn=83, 86, SP=75, 65 respectively	P.Casti et al. [32], 2017
Digital Mammography	322, 1459	Benign, Malignant	LDA linear discriminant analysis	Breast density classification into calcification and masses	The breast cancer classification based on 298 texture features calculated through statistical analysis method that influence on breast tissue	DDSM, MIAS	Acc=99.75, 91.58 respectively	N. et al. [153], 2014
Digital Mammography	322, 2604 cases	Benign, Malignant	Adaptive differential Evolution Wavelet-Ann (Ada-DeWNN)	Ada-DeWNN	GPZM moments & PZM moments are used for texture characterization and feature extraction from ROI area in mammogram.	DDSM, MIAS	Acc=89,87, SN=84,82, SP=92,90 AUC=93,92 respectively	Singh, S. P. et al [65], 2016
Digital Mammography	240, 106, 95, 58	Normal, Benign, Malignant	PL DT, RF, SVM	Differentiating of breast lesion into normal, benign and malignant	Curvet-transform, LBP and feature selection associated with statistical analysis. The features which are similar are remove through ANOVA that increase the performance of classifier.	DDSM, BCDR-FMR, BCDR-DMR, UCSB-BB respectively	AUC= 100 each	D.O.T. Bruno, et al. [96] 2016
Digital Mammography	300	Benign, Malignant	SVM	Auto-Classification and identification of breast density.	Fuzzy C Means are used to segmentation of various breast tissue. Several morphological and texture feature are extracted	MIAS	Acc=91.51, SN=87.33 AUC=93.63	K. Vaidehi et al. [146] 122

Continued on Next Page ...

TABLE 5. (Continued.) The systemic analysis on medical multi-image modalities for diagnosing of breast cancer abnormalities.

Imaging modality	#Image	#Classes	Method Used	Task Performed	Feature Extracted	Dataset Name	E. Matrix	Ref#
Digital Mammography	322	Normal, Abnormal	SVM	Classification of breast cancer abnormalities using fusion features (Local and global)	Chebyshev moments and GLCM feature used in Local while Gabor Laws texture and fractal dimensions used in global feature	MIAS	Acc=83.1, SN=92.71 AUC=93.46	Phadke, A. C et al. [154], 2016
Digital Mammography	110	circumscribed benign, spiculated malignant	SVM	Detection and diagnosing of breast lesions	Fractal method used for feature extraction based on contour information which measure the roughness of contour, edges and smoothness.	MIAS	Acc=99, AUC=99	Beheshti, S. M. A et al. [145]2014
Digital Mammography	322	Normal, Abnormal micro-calcification	SVM	Classification of ROI and micro-calcification as normal and abnormal	Haar, DB4, DT-CWT textural features extracted by wavelet transform from ROI. The space and frequency domain method used for segmentation and PCA characterization of micro-calcification	MAIS	Acc=96.30, SN=97.70, SP=89.90	P.B. Ribeiro et al. [125] 2015
Digital Mammography	95	Normal, Benign, Malignant	SVM	Classification into normal and abnormal tissue using fracture extraction through Hough transform.	Removing the label and unwanted marking, intensity based segmentation and hough transform used for arbitrary shapes detection like intensity, mean, variance, SD and entropy	MIAS	Acc =94.00	Vijaya, R et al. [85], 2019
Ultrasound	46	Benign, Malignant	SVM	auto-detection of tumor regions of breast	The 2-D ULS image filtered to reduce the speckle noise. Several features included in gray, texture, shape, position and gradient are extracted to enhance the efficiency of classification.	MIAS	Acc=98.90, SN=96.40, SP=98.50, AUC=99.70	Huang, Q et al. [155] 2015
Digital Mammography	70	Benign Malignant	SVM, (PSO-SVM), Extreme-Learning-Machine (ELM-ANN)	Breast mass classification into benign and malignant	ROI extraction, auto-mass segmentation, features selection and extractions, using particle PSO-SVM and SVM.	MIAS	Acc=89,90,96, SN=92,92,92 al., SP=87,89,94 AUC=92,93,96 respectively	Xie. w et al., [59], 2017
Digital Mammography	109	Normal, Benign, Malignant	SELwSVM	Classification of breast tissues into Normal, Benign and malignant mass	Gabor filter use for ROI detection and texture feature extraction i.e micro pattern, edges and fate areas	MIAS	Ave.68-100% Acc=	Khan, S et al. [91], 2017
Digital Mammography	57	Benign, Malignant	ANN	Classification of breast tumor as benign or malignant	segmentation carried by SFC, RG, CNN using contour, region and clustering. The shape, texture and intensity features derived using GA algorithm.	MIAS	Acc=91.00, Sn=100, SP=97.00, AUC=97.01	Rouhi, R. et al. [138] 2016
Digital Mammography	322	Benign, Malignant	ANN	Identification, diagnosing and classification of breast abnormalities.	The extraction performed by limiting the frequency components through WDA and NN. Wavelet decomposition analysis used to deriv feature.	MAIS	SN=68.80, SP=95, AUC=85	Mina, L. M et al. [147]2015

Continued on Next Page ...

TABLE 5. (Continued.) The systemic analysis on medical multi-image modalities for diagnosing of breast cancer abnormalities.

Imaging modality	#Image	#Classes	Method Used	Task Performed	Feature Extracted	Dataset Name	E. Matrix	Ref#
Digital Mammography	222	Normal, Benign, Malignant	ANN	Efficient detection and segmentation of lesions as benign and malignant	preprocessing and segmentation via SRG, noise removing using 2D median filter, enhance contrast and radiopaque artifacts. contrast, energy, moment and entropy are explored	MIAS	Acc=90 AUC=54 AUC=59	Peng W et al. [64], 2016
Digital Mammography	322	Normal, Benign, Malignant	FCRN and ANN	Classification of breast abnormalities as normal, benign and malignant	Features like Binary-object Features (area, perimeter, thickness,), RST-Invariant, Histogram, Texture and Spectral features are extracted	MIAS	Acc=98, SN=97 SP=100 AUC=94.70	D. Saraswathi et al. [44], 2014
Digital Mammography	480	Mass, Not mass	Bayesian regularization back-propagation networks, ANFIS techniques.	Auto-detection of breast lesions	The Gaussian density and classification ANSIF approach used for image detection, characterization and image enhancement.	MIAS	Ave. Acc=97.08, 95.42 respectively	H.Mahersia et al [112], 2016
Digital Mammography	322	Normal, Benign, Malignant	AdaBoost	Breast cancer detection and classification as benign and malignant	Mass and calcification characterization based on density, shape, boundary, and region using wavelet transform and skewness	MIAS	Acc=91.00 Sn=86.15, SP=94.00, AUC=90.03	F. Pak et al. [129]2015
Digital Mammography	40, 20	Benign, Malignant	Fuzzy C-Means (FCM)	The identification of masses and micro-calcification using clustering enhancement	The segmentation of macro-calcification on pathological images employed using LOG filter to overwhelmed the dependencies	MIAS, Private	Acc=95 94, SN=93 82, SP=64 65 respectively	Vivona, L. et al. [69] 2015
Digital Mammography	699	Benign, Malignant	LPSVM, LSVM, SSVM, PSVM, NSVM	Classification of breast tumor	Offline breast cancer diagnosing system was developed and utilized for classification of breast cancer.	WBS	Acc=97,95, 96,96,96 SN=98,96, 96,97,96 respectively	Azar, A.T. et al. [75] 2014
Digital Mammography	600 patches	normal, benign, malignant	Fisher, Linear Discriminant Analysis (FLDA)	Classification of breast Cancer	HE enhanced the contrast followed by NLm filtering performing adoptive smoothing and some features (statistical and frequency domain) extraction performed by LCP.	IRMA	Acc=94.67	Esener, I. I. et al. [76] 2015
Digital Mammography	200 img, 800 patches	malignant or nonmalignant	SVM	Classify image patches as malignant or non malignant	The extraction of fixed size ROI and remove the unwanted component, artifact, muscles and background by GLCM, DCT.	IRMA, DDSM	SN=97, 99 SP=96, 99 respectively	S.Sharma et al. [63], 2015
Digital Mammography	200 each DB	Normal, Abnormal	SVM, KNN, Decision Tree, LDA	Classify the lesions as normal, benign and malignant	HOG, DSIFT, LCP methods extract the rotation and scale invariant features of segmented tissue.	IRMA, DDSM	Acc=90.60	S. Ergin et al. [68], 2014
Digital Mammography	383 and 1953 patches	Normal, Abnormal	KNN	classifying ROI as normal or abnormal	Image divided in patches and similarity measures are computed through DWT method of each patches.	IRMA, MIAS	Acc=89.81 SN=92.85 AUC=97.13	Gardezi et al. [93], 2017

Continued on Next Page ...

TABLE 5. (Continued.) The systemic analysis on medical multi-image modalities for diagnosing of breast cancer abnormalities.

Imaging modality	#Image	#Classes	Method Used	Task Performed	Feature Extracted	Dataset Name	E. Matrix	Ref#
Digital Mammography	140	Benign, Malignant	SVM	Detection of micro-calcification clusters	Extraction and segmentation of Micro-calcification and Geometry feature extraction.	INbreast	SN=92, AUC=86.07	Liu x. et al. [77], 2015
Digital Mammography	322, 410	Benign, Malignant	SVM	Distinguishing between abnormalities as masses and calcification	CLAHE used for pre-processing, HE used for contrast adjustment and LESH detect any type of abnormalities and feature extraction.	INbreast, MIAS	Acc=99 AUC=99	S.K. Wajid et al [90], 2015
Digital Mammography	322, 410	Mass, Normal	SVM	Breast tissue and density classification.	ULDP is a feature extraction method that characterize the breast tissue and differentiate the breast masses	INbreast, Mini, MIAS	Acc=99,92, AUC=93,99 respectively	Abdel-Nasser et al. [72], 2015
Digital Mammography	410	low Dense, high dense	CNN	Classify the Breast density in to fatty, fibroglandular dense , heterogeneously dense and extremely-dense	Deep CNN as a radiomics approach to auto-extract high throughput,level, and abstract features which serves for classification breast densities	INbreast	Acc=96.80	Xu, Jingxu, et al. [116], 2018
Digital Mammography	410	Normal, Benign, Malignant	Alexnet Deep learning based CNN	The CAD system auto-detection, segmentation and classification of mass.	YOLO used mass detection from mammogram. FrCN is used for segmentation and finally classify the mass.	INbreast	Acc =89.91, SN=95.64 AUC=94.8 F-score=96	Mugahed A. et al. [42], 2018
Digital Mammography	322, 410	fatty, denser, glandular dense, extreme denser	GP, LCS, NB, DT,K-NN and SVM. GP	classification of breast density	Statistical features and local binary pattern are used for the classification of breast density	INbreast, MIAS	Acc=68,69,52, 68,58,70 (INbreast), Acc=70,65, 62,66,71,74 (MIAS)	F.Burling-Claridge et al. [156], 2016
Digital Mammography	116, 158	Benign, Malignant	Fully convolutional network and CRF	Breast mass detection, segmentation into benign, and malignant.	e2e FCN network used mass segmentation. Due to low contrast, image enhancement is used for extraction and resizing of ROI	INbreast, DDSM	Dice score =0.97	Zhu, W et al. [124], 2018
Digital Mammography	64	Normal, Benign, Malignant	Random Forest, Naive bayes, SVM_SMO	Dense and fatty breast tissue classification	Classification of mass and its types with GLCM and GLRLM	BSDR	Acc=78,83,61 SN=78,78,63 SP=78,71,63 AUC=83,90,61 respectively	Joana Diz et al [58], 2016
Digital Mammography	364	Benign, Malignant	Deep Learning Method	Characterization of micro-calcification cluster	The image contrast enhanced through the Sobel and Gauss filter for removing noise. The identification of micro-calcification using Hough transform and Threshold method.	BCDR	SN=92.89	Basile, T. M. A., et al. [79], 2019
Digital Mammography	736, 724	Masses , not masses	Deep Learning Method	Auto-classification of breast lesions	Contrast enhancement carried by cropping, augmentation, locally and globally. 17 hand crafted feature intensity, shape, textures are extracted from segmented masses.	BCDR-Fm, BCDR-DM AUC	AUC= 82.60	Arevalo, John et al. [118], 2016

Continued on Next Page ...

TABLE 5. (Continued.) The systemic analysis on medical multi-image modalities for diagnosing of breast cancer abnormalities.

Imaging modality	#Image	#Classes	Method Used	Task Performed	Feature Extracted	Dataset Name	E. Matrix	Ref#
IRT	63	Normal, Abnormal	SVM-RBF	Classification of breast cancer into normal and abnormal based on statistical and texture feature	cervelat transform used for auto-detection of abnormality. Statistical and textural, cervelat-domain-Energy, contrast, correlation, sum of squares: variance, inverse difference moment, sum-variance, sum-entropy, entropy, difference-variance, difference-entropy, feature are extracted .	DMR-IR	Acc=90.91 SN=81.82, SP=100	Ali, M. A et al. [157] 2015
IRT	63	Normal, Abnormal	KNN, SVM, NB	Classification into normal and abnormal pattern.	Texture feature extracted using GLCM and minimum variance quantization, dilation of image and erosion of image minimum variance quantization is used for data segmentation.	DMR-IR	Acc=92.5 SN=85.7, SP=90.9	Milosevic, M et al. [158] 2014
Digital Mammography	397	Dense, non-dense(fatty)	Transfer learning-based CNN model	Classify the breast mass into dense and fatty tissues	Mammogram divided into patches by data-augmentation. Local and global statistics are extracted	FFDM	Correlation coefficient 0.96	Ahn, Chul Kyun, et al. [78], 2017
Digital Mammography	219	Benign, Malignant	Transfer learning-based CNN model	Detection of lesions.	Feature extracted through transfer learning from pertained CNN.	FFDM	AUC=81.00	Huynh, Benjamin Q et al. [47], 2016
Digital Mammography, Ultrasound, MRI-DCI	880	benign solid, benign cystic, Malignant	CNN-based, CADx-bases, and fusion classifiers	Detection of lesions	Fusion of human engineering computer features and extracted through transfer learning from pertained CNN	FFDM	AUC=90.00 AUC=89.00 AUC=89.00 respectively	Andropova et al. [28], 2017
Digital Mammography	456	benign Malignant	CNN, SVM	BRCA1/2 mutation and BRCA1/2 gene-mutation carriers from the low-risk control group	Texture Analysis performed on each ROI for texture feature extraction based on HE, 31 gray-level co-occurrence matrix,32 fractal analysis and Fourier analysis characterize the mammographic patterns	FFDM	AUC=86.00	Li et al. [159], 2017
Digital Mammography	42	Benign, Malignant	Deep-learning-based Method	Classify the breast mass between malignant and benign	MLP is categorized the ROI extraction.	FFDM	AUC=79.00	Qiu, Y et al. [23], 2017
Digital Mammography	73,128	cancerous, non-cancerous	CNN	Predict Breast density using visual analogy scale scores	The Breast density based on visual area-based methods, Boyd categories, VAS, and semiautomated thresholds (Cumulus)	PROCAS	AUC=61.00	Ionescu, Georgia V., et al. [134], 2019
Digital Mammography	410	Benign, Malignant	Cascade of deep learning, random forest models	Breast mass detection, segmentation and classification into benign and malignant.	Mass detection using m-DBN. GMM, RF, DL and mass refinement by bayesian optimization segmentation.	PROCAS	Acc=85.00, SN=98.00, SP=70.00	Dhungel et al. [49], 2017

Continued on Next Page . . .

TABLE 5. (Continued.) The systemic analysis on medical multi-image modalities for diagnosing of breast cancer abnormalities.

Imaging modality	#Image cases	#Classes	Method Used	Task Performed	Feature Extracted	Dataset Name	E. Matrix	Ref#
Digital Mammography	90 cases	Benign, Malignant	SVM	To predict the near-term risk of breast cancer	Near-term lesions detection by feature analysis like bilateral spatial, texture and morphological features	Private	AUC=75.40	Sun, W. et al. [160] 2014
Ultrasound	138	Benign tumor, Malignant tumor	SVM	Discrimination of benign and malignant tumors using phase-based textural descriptor.	PC method are efficiently seizure the vital structural alteration among benign and malignant tumors.	Private	Acc=87.00, SN=86.96, SP=87.00, AUC=89.40	Cai, L et al. [88]2016
Ultrasound	120	Benign, Malignant	SVM	Discrimination of breast lesions	44 feature contains 5 texture (Histogram, MRF, GLRLM, GLCM, Tamura), 9 morphological ((F40-F44), Model based and Descriptor features for every ROI are extracted to discriminate the masses	Private	Acc=96.08, SN=96.10, SP=91.20, AUC=94.44	K.M. Prabu-sankarla et al. [161]2015
Ultrasound	105	Benign, Malignant	SVM	Axillary lymph node meta-stasis classification using signed distant-transfer-feature	The manual segmented lymph node describing the entire lymph node and internal hilum surfaces.	Private	SN=95.00, SP=95.00, AUC=95.00	Chmielewski, A. et al. [148] 2015
IRT	22	Normal, Abnormal	SVM	Classifying the thermograph in normal and abnormal	Image is segmented through cervelat transform. Statistical and texture feature are extracted.	Private	Acc=86.36, SN=81.82, SP=90.91	Francis, S. V et al. [162] 2014
Ultrasound	210	Benign, Malignant	SVM, artificial immune system (AIS) algorithm	Discrimination of breast tumors between benign and malignant.	30-features including Textural and shape (morphological) related feature from ROI are extracted to discriminate between benign and malignant tissues	Private	Acc=96.67, SN=95.67, SP=96.77, AUC=98.27	Wu, W. J. al el. [114] 2015
Digital Mammography	990	Benign Malignant	DCNN	Automatic deselection, analysis and classification of calcification	feature extracted through handcraft and deep-learning-based method. Calcification are attained by data-augmentation	Private	Acc=88.59, SN=88.43, SP=86.89, AUC=93.9	Duggento et al. [117], 2019
Digital Mammography	200,000	Dense, non-dense(fatty)	Transfer learning-based CNN algorithms	CCNN employed to classify the dense tissue and non-dense tissue.	Breast density predication based on histogram of pixel intensity measure with SoftMax. Difference in pixel intensity appear dark in fat tissue as compared to fibro-glandular.	Private	AUC=93.40	Wu, N et al. [163], 2018
Digital Mammography	45000	Malignant lesions, benign abnormalities	Deep convolutional neural network	Detection of tumor as malignant and benign	Detection and classification of suspicious areas. Distance transform used for mass segmentation, its background, contour and edges. Gaussian derivative filter used for feature extraction.	Private	Acc=92.20	Kooi, T., et al. [80], 2017

Continued on Next Page ...

TABLE 5. (Continued.) The systemic analysis on medical multi-image modalities for diagnosing of breast cancer abnormalities.

Imaging modality	#Image	#Classes	Method Used	Task Performed	Feature Extracted	Dataset Name	E. Matrix	Ref#
Digital Mammography	1874	Benign, Malignant	Deep-learning-based Method (SSL algorithm)	Diagnosing of breast cancer lesions	21 features i.e mass density, area, circularity, semi-axis ratio, longest-radial length, mean-intensity, intensity-variation and irregularity of ROI are extracted using GLCM, PCA, LDA, MDS.	Private	Acc=82.04 SN=80.90 SP= 71.99 AUC= 88.18	Sun, W. et al. [131], 2016
Digital Mammography	42	Normal, Benign, Malignant	FF back propagation Network and cascade forward back propagation ANN	Breast cancer detection and diagnosing	Features (GLCM) extracted from the know mammogram images and are stored in the knowledge base	Private	Acc=87.5	Saini S, Vijay R et al. [41], 2015
Ultrasound	200	Benign, Malignant	Back Propagation-ANN	Classification of breast masses based on features	Bi-clustering discover the local-diagnostic pattern that used to process and originate hidden features in training data consist on distance measurement	Private	Acc=94.00 SN=94.40, SP=93.60	Chen Y. et al. [52] 2016
Digital Mammography	120	mass, without mass	Optimum-Path Forest (OPF algorithm)	Identification and classification of masses presents in of breast suspicious areas	Gaussian-mixture model and k-Means clustering used for textural features extractions (regularity, roughness, softness) from images	Private	Acc=99	Ribeiro P. B et al. [81], 2015
Digital Mammography	482	Benign, Malignant	Fisher LDA, Extreme learning machine (ELM-ANN)	Detection of breast tumor	Median filter is used to enhance the contrast and to noise reduction. The tumor features are derived through DWT, textural, morphological operation, region growing and edge segmentation.	Private	Acc= 83.00,	Wang Z, et al. [107] 2014 107
Ultrasound	54, 18 Cases	Benign, Malignant	Binary-LR (tumor-mapping algorithm)	Mapping of similar regions for detection of tumor to increase the efficiency of clinical practice	Extraction of similar region according to nipple. The location, texture, morphological, quantitative intensity used for distinction of similar and dissimilar region.	Private	Acc=88.39	Lo, C. M., Chan et al. [164] 2016
Ultrasound	93	mass, non-mass	KNN	Diagnoses of non-mass lesions appearing as hypoechoic areas on ultrasound image.	The diagnoses carried through core needle biopsy and vacuum assisted. Excisional biopsy predicted after first diagnoses	Private	SN=87.80, SP=89.50, AUC=93.00	Shibusawa, M et al. [51] 2016
Ultrasound	156	Benign, Malignant	Linear Logistic Regression	Classification breast tumour based on tumor size	The pixel intensity histograms and textural feature are automatically extracted that are categorized according to equivalent breast density	Private	Acc=81.40, SN=82.30, SP=80.50, AUC=85.20	Moon, W. K et al. [100], 2017
Ultrasound	59	Benign, Malignant	Random Fores	Detection and discrimination of tumors between benign and malignant	ULS image faces speckle noise and low contrast that effect on ROI textural feature. SR based method improve GLCM, LBP, HE, PLS which help in tumor classification	Private	AUC=99.00	Abdel-Nasser et al. [53] 2017

Continued on Next Page ...

TABLE 5. (Continued.) The systemic analysis on medical multi-image modalities for diagnosing of breast cancer abnormalities.

Imaging modality	#Image	#Classes	Method Used	Task Performed	Feature Extracted	Dataset Name	E. Matrix	Ref#
Ultrasound	283	Benign, Malignant	DT, ANN, RF and SVM	Differentiation of benign tumor from worrisome masses	Several features use as input for ML methods and the bottom-up feature selection used to invention the best feature set.	Private	Acc=78.50, AUC=83.00	Shan, J. et al. [95]2016
Ultrasound	246 Cases	Benign, Malignant	Adaptive Boosting	Differentiating of solid breast lesions in benign and malignant	Feature are extracted to routinely estimating masses and coarseness, shape are auto-exerted to find lesion manually based on pathologists interpretation.	Private	SN=90.00, SP= 97.50, AUC=98.00	Venkatesh S. S et al. [109]2015
Ultrasound	69	Benign, Malignant	Binary LR	CAD classify the malignant tumor acting as a second viewer	The textural features, speckle, gray scale dissimilarities between ultrasound image, were limited by changing pixels into intensity-invariant.	Private	Acc=83.60, SN=75.90, SP=88.02	Lo, C. M et al. [101], 2015
Digital Mammography	22000	scattered density, heterogeneously dense	CNN-based AlexNet model, ANN	Distinguishing the Breast density between scattered density and heterogeneously dense	Auto-extraction of ROI from suspicious mass. HE and statistical feature extraction to enhance the performance.	ImageNet	AUC=98.82	Mohamed, A. A et al. [45], 2017
Digital Mammography	493, 668, 394	Extreme Denser, Less Denser	Convolutional sparse auto-encoder (CSAE))	Auto segmentation and feature scoring of breast density	Pixel-wise image labeling through CSAE and characterization of textural patterns for predicting of breast cancer.	Dutch Breast Cancer screening.	AUC=61, AUC=54, AUC=59 respectively	Kallenberget at al. [130], 2016

Sun *et al.* [131] explored the deep learning-based model (SSL algorithms) to extract the GLCM and geometric features such as size, circularity, sphericity, irregularity of ROI, and yields the remarkable performance which obtained 82.4% accuracy. In this study, 20 deep learning-based publications are proposed which is out of 8% of the selected study.

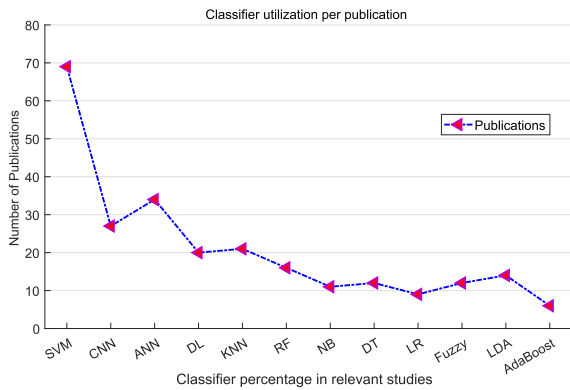
Furthermore, a human brain is composed of billions of interconnected neurons that receive, transfer, process and responds to the information using a chemical reaction. Similarly, an artificial neural network (ANN) is composed of a set of artificial neurons inspired by the biological neural network. ANN achieves promising outcomes in the delineation of high-resolution multi-image modalities in breast cancer prediction, mass segmentation, localization, and classification [44], [95], [138], [139]. Murtaza *et al.* [140] developed a computationally cost-effective, ensemble breast cancer classification-network (EBRC-Net) for breast cancer diagnoses at initial stage using histopathology images (BreakHis dataset) and obtained 97.74% accuracy. Six ML classifiers applied for feature extraction, however, false predictions reduced using three misclassification reduction models that show remarkable results. This study consist of 32 ANN-based publications which is 14% of the total selective studies. In many articles, ANN works with the association of other classification techniques such

Back Propagation-ANN [52], Fuzzy-feed forward back-propagation neural-network (ACFNN) [60], Radial-Basis Function Neural-Network (RBFNN) [120], Probabilistic Neural-Network (PNN) [87], GA optimized ANN [54], to achieve the accurate and efficient performance. From literature, it is investigated that the ANN and SVM are widely used for breast cancer classification as declared in (Figure 9a).

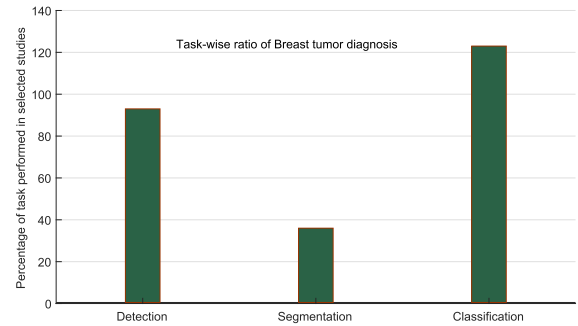
F. PERFORMANCE METRICS ANALYSIS

After successfully training the dataset, test images are served as input to the classifier to evaluate its performance. In breast cancer diagnosing, the malignant or abnormal lesions are positive class samples while the benign or normal is a negative class sample. The popular metrics used for breast cancer classification as declared in (Figure 10a).

- True Positive → Diagnosed correctly as Malignant
TP = tumor present + result positive
- True Negative → Diagnosed correctly as Benign
TN = tumor absent + result negative
- False Positive → Benign misclassify as Malignant
FP = tumor absent + result positive
- False Negative → Malignant misclassify as Benign
FN = tumor present + result negative

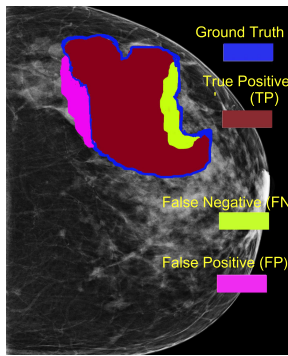


(a) Classifier used in publication.

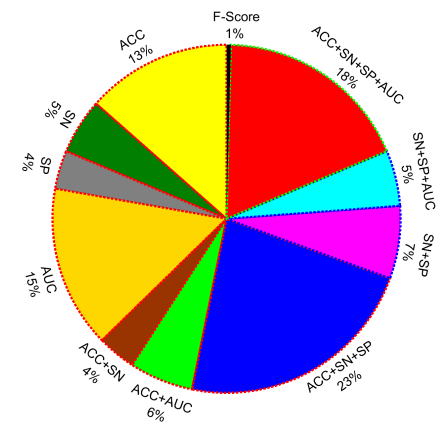


(b) Tumor diagnosing process using breast multi-modalities

FIGURE 9. (a). Distribution of publications between different classifiers for breast cancer classification. (b). Different CAD system task investigated by the selected studies.



(a) Pixel-wise distribution of performance metrics.



(b) Percentage of commonly used performance metrics.

FIGURE 10. (a). Pixel wise description of true-positive, false-positive, and false-negative comparison with ground truth. (b). Percentage of performance metrics used in selected studies.

Accuracy metric is a proportion to the number of correctly classified instances in both abnormal patient or true positives and normal patients or true negatives. The comparison between different metrics for classification of breast cancer is presented in (Figure 10b). The 34 (out of 252) articles only calculates the accuracy and achieved the results between 100% to 74.92% [68], [141]–[143].

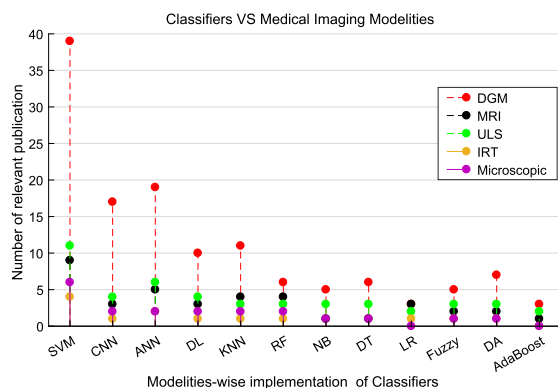
Sensitivity presents correctly diagnosed positive instances which is positive. It means that how many breast cancer patients are accurately diagnosed with total abnormal patient [31], [62], [86]. 13 (out of 252) studies calculate only sensitivity and achieved the performance between 98% to 82.4%.

Specificity presents correctly diagnosed negative instance as correct [79], [117]. It means that how many patients do not have breast cancer and are accurately diagnosed. 09 (out of 252) studies calculates the only sensitivity and achieved the results between 98.26% to 62.90%. 38 (out of 252) studies calculates the only AUC and achieved the results between 98.82 % to 73% [67], [113], [144]. 01 study calculates the F-Score [42] and achieved the results of 96.84%. 09 studies

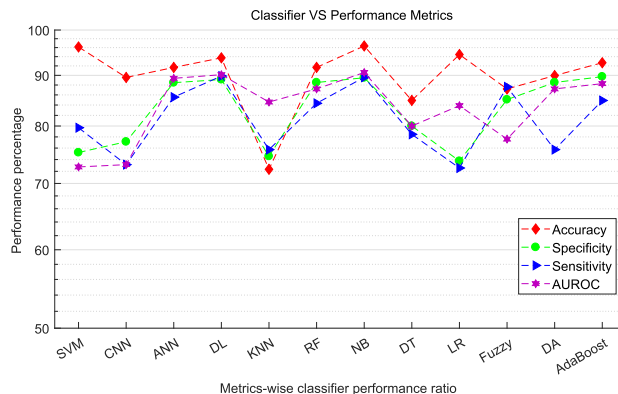
calculates both Acc and SN [77], [95]. 07 studies calculate both Acc and AUC [64], [90], [145]. 07 studies calculates both Acc and SN [75], [146]. 17 studies calculate both SN and SP [32], [63]. 57 studies calculates the Acc, SN, and SP [43], [60], [61], [104], [123]. 13 studies calculate the SN, SP, and AUC [51], [147], [148]. 46 studies calculates the Acc, SN, SP and AUC [58], [59], [149].

VI. DISCUSSIONS

Breast cancer is a fatal disease that increases the mortality rate in women. Early intervention and clinical management can improve the diagnostic process. Based on its seriousness, large numbers of articles have been published as shown in (Figure 9a). So, it is problematic to summarize all research work related to abnormality segmentation using DL techniques in a single article. However, this research delivers a holistic approach where we tried to summarize the available breast databases, preprocessing approaches, segmentation approaches, development of DL models, performance metrics, and state-of-the-art findings of breast cancer



(a) Utilization of imaging modalities per classifiers.



(b) Performance ratio of classifier.

FIGURE 11. (a). Statistics of medical imaging modalities per classifiers used for breast cancer classification. (b). Performance evaluation of various selected study classifiers by using the independent test dataset.

segmentation and classification. The contribution of DL models for breast cancer prediction helped doctors significantly by providing the second opinion for the establishment of the final decision, which enhanced the satisfaction and confidence of the patients. The scarcity of experts and doctors in under-developed countries was a key issue, however, the CAD-based diagnostic system provided timely feedback which helped in improving the diagnostic process with a declining mortality rate. However, as a result of a comprehension survey from the current literature, our study suggested that the mammographic image is the most effective and reliable tool used for early breast lesions prognoses. It attained more prominent attention in providing significant information for early diagnosing of breast abnormal tissues which are helpful for possible treatment arrangements. Mammogram has soft tissue contrast that helps the doctors in revealing the location and magnitude of breast tumor due to distinct absorption of low radiation rate between normal and abnormal tissues.

The primary motivation behind this study was to assist researchers and doctors in the development of a robust CAD system which is computationally efficient and reliable for early prognosis of breast abnormalities. But, there exist several serious complications and challenges during their clinical implementation. The details of the existing up-to-date work on breast abnormalities segmentation and classification is illustrates in (Table 5). This study also shows that recent ML approaches can be limited for a particular kind of breast density and cannot be generalized to a worldwide population. However, the DL method uses hybrid and semi-supervised approaches to extract significant information for the segmentation and classification of breast lesions. Besides, to limit human intervention, the development of a fully automated CAD system is significant for masses segmentation. From literature, it is also found that the automated DL method needs higher computation resources which makes it unfavorable in a practical environment. Although, all of the techniques need a massive amount of annotated images for training

and validating outcomes. The statistics of medical imaging modalities per classifiers used for breast cancer classification are shown in (Figure 11a). The availability of labeled medical images with image level and pixel-level annotation is a key issue because the image annotations from experts and doctors is a complex, expensive and time-consuming task.

Furthermore, from literature, it is also found that the development of DL approaches from limited medical images is an open research challenge, however, DL techniques often use a data augmentation approach to enhance the database. Due to the complex structure of the female breast, the availability of different medical images of the same patient in the publicly available database is another research problem as shown in (Figure 9b).

Apart from the building of an automatic DL model, financial support for the management and construction of the medical database is another research challenge. Besides, confidentiality and copyright issues for the availability of medical images is also a complex and difficult process. Furthermore, this study summarizes the recommendations to enhance the performance of DL approaches in segmentation and classification of breast abnormalities using multi-images modalities and are as follow:

- Usage of preprocessing techniques to improve the image contrast like CLAHE, OTSU filters.
- Usage of invariant-scale approach for defining of ROI.
- Usage of context-based approach for ROI patches classification.
- Usage of histogram-based approach for the selection of the optimal value of threshold by using simple peak information for image segmentation.
- Usage of image cropping and down-sampling for more precise computation.
- Usage of augmentation approach to enrich the database.
- Usage of multi-image modalities of the same patient to enhance the reliability of the model.
- Usage of 3D image modalities database, if available such as US-SWE.

- Usage of context and patient information in a multi-imaging modality.
- Usage of the available well-labeled database.
- Usage of ELM, TL, classification approaches for obtaining a promising outcome.
- Usage of interpretability of model-layer data to extract features.
- Usage of appropriate validation techniques comparative to the available dataset.
- Usage of recent libraries for the implementation of DL approaches such as PyTorch, Caffe, TensorFlow, Keras, MatLab.

VII. CONCLUSION

In this study, we systematically compared the strengths, limitations, and performance of recent DL and ML schemes by analyzing medical multi-image modalities as shown in (Figure 11b). From this study, it is also evident that with the advancement of DL approaches the process of breast abnormalities segmentation and classification is improved which truly assisted radiologists and researchers. Researchers often prefer to use public databases rather than private because of the fact that public databases contain a huge amount of records and are comprised of a mixture of normal, benign, and malignant cases. In addition, they also provide multi-modalities of images of the same patients. Preprocessing is one of the most important steps that include augmentation, ROI segmentation, resizing, noise removing, image enhancements, and cropping. It is executed to remove irregularities in the images before the establishment of a training process for a DL scheme. Moreover, this research comprehensively examines the benefits and risks of existing literature for the development of a robust and reliable CAD system to limit the computational and time complexities related to the development of breast cancer diagnostic system. ML approaches are found imperfect for precise segmentation of densities; however, DL approaches helped in minimizing false-positive ratio (FPR) in the segmentation of masses. DL approaches need a huge amount of annotated images for training; therefore, to cope with the data scarcity issue, data augmentation is often adopted. Furthermore, this research also highlights significant research directions to appropriately select the DL technique, image-modality, and database for the segmentation of breast mass and calcification.

REFERENCES

- [1] F. Bray, J. Ferlay, I. Soerjomataram, R. L. Siegel, L. A. Torre, and A. Jemal, "Global cancer statistics 2018: GLOBOCAN estimates of incidence and mortality worldwide for 36 cancers in 185 countries," *CA, Cancer J. Clinicians*, vol. 68, no. 6, pp. 394–424, Nov. 2018.
- [2] E. R. Fearon, "Human cancer syndromes: Clues to the origin and nature of cancer," *Science*, vol. 278, no. 5340, pp. 1043–1050, Nov. 1997.
- [3] Z. Momenimovahed and H. Salehiniya, "Epidemiological characteristics of and risk factors for breast cancer in the world," *Breast Cancer Targets Therapy*, vol. Volume 11, pp. 151–164, Apr. 2019.
- [4] T. Donnem, A. R. Reynolds, E. A. Kuczynski, K. Gatter, P. B. Vermeulen, R. S. Kerbel, A. L. Harris, and F. Pezzella, "Non-angiogenic tumours and their influence on cancer biology," *Nature Rev. Cancer*, vol. 18, no. 5, pp. 323–336, May 2018.
- [5] J. Braithwaite, "What is cancer?" *Lancet*, vol. 131, no. 3383, pp. 1287–1289, 1888.
- [6] O. Collins, "Last year's virus, this year's cancer treatment," *BU Well*, vol. 3, no. 1, pp. 3–4, 2018.
- [7] S. Kaye, "Breast cancer and ovarian cancer: State of the art treatment approaches," *Eur. J. Cancer Supplements*, vol. 6, no. 4, p. 29, 2008.
- [8] F. L. Greene, "Breast," in *AJCC Cancer Staging Manual*. New York, NY, USA: Springer, 2002, pp. 223–240.
- [9] C. L. Akay, C. Albarracin, T. Torstenson, R. Bassett, E. A. Mittendorf, M. Yi, H. M. Kuerer, G. V. Babiera, I. Bedrosian, K. K. Hunt, and R. F. Hwang, "Factors impacting the accuracy of intra-operative evaluation of sentinel lymph nodes in breast cancer," *Breast J.*, vol. 24, no. 1, pp. 28–34, Jan. 2018.
- [10] M. Ishii, I. Kimijima, and M. Suzuki, "Invasive and non-invasive breast cancer can be distinguished from normal mammary gland or benign breast tumor by apparent diffusion coefficient in magnetic resonance imaging," *Cancer Res.*, vol. 69, no. 2, p. 4011, 2009.
- [11] S. Tuzlali, "Pathology of breast cancer," in *Breast Disease: Diagnosis and Pathology*, vol. 1. Cham, Switzerland: Springer Nature, 2019, pp. 201–220.
- [12] M. E. Lopez and O. O. Olutoye, "Breast embryology, anatomy, and physiology," in *Endocrine Surgery in Children*. Berlin, Germany: Springer, 2018, pp. 365–376.
- [13] M. Tarique, F. ElZahra, A. Hateem, and M. Mohammad, "Fourier transform based early detection of breast cancer by mammogram image processing," *J. Biomed. Eng. Med. Imag.*, vol. 2, no. 4, pp. 17–32, Aug. 2015.
- [14] F. A. Spanhol, L. S. Oliveira, C. Petitjean, and L. Heutte, "Breast cancer histopathological image classification using convolutional neural networks," in *Proc. Int. Joint Conf. Neural Netw. (IJCNN)*, Jul. 2016, pp. 2560–2567.
- [15] *Factors That Affect Prognosis and Treatment*. Accessed: Aug. 24, 2020. [Online]. Available: <https://www.komen.org/BreastCancer/FactorsthatAffectTreatmentOptions.html>
- [16] E. L. Henriksen, J. F. Carlsen, I. M. Vejborg, M. B. Nielsen, and C. A. Lauridsen, "The efficacy of using computer-aided detection (CAD) for detection of breast cancer in mammography screening: A systematic review," *Acta Radiol.*, vol. 60, no. 1, pp. 13–18, Jan. 2019.
- [17] P. Sahni and N. Mittal, "Breast cancer detection using image processing techniques," in *Advances in Interdisciplinary Engineering*. Singapore: Springer, 2019, pp. 813–823.
- [18] I. Dankwa-Mullan, M. Rivo, M. Sepulveda, Y. Park, J. Snowdon, and K. Rhee, "Transforming diabetes care through artificial intelligence: The future is here," *Population Health Manage.*, vol. 22, no. 3, pp. 229–242, Jun. 2019.
- [19] G. Litjens, T. Kooi, B. E. Bejnordi, A. A. A. Setio, F. Ciompi, M. Ghafoorian, J. A. W. M. van der Laak, B. van Ginneken, and C. I. Sánchez, "A survey on deep learning in medical image analysis," *Med. Image Anal.*, vol. 42, no. 9, pp. 60–88, Dec. 2017.
- [20] S. Duraisamy and S. Emperumal, "Computer-aided mammogram diagnosis system using deep learning convolutional fully complex-valued relaxation neural network classifier," *IET Comput. Vis.*, vol. 11, no. 8, pp. 656–662, Dec. 2017.
- [21] M. Arfan, "Deep learning based computer aided diagnosis system for breast mammograms," *Int. J. Adv. Comput. Sci. Appl.*, vol. 8, no. 7, pp. 90–286, 2017.
- [22] M. H.-M. Khan, "Automated breast cancer diagnosis using artificial neural network (ANN)," in *Proc. 3rd Iranian Conf. Intell. Syst. Signal Process. (ICSPIS)*, Dec. 2017, pp. 54–58.
- [23] Y. Qiu, S. Yan, R. R. Gundreddy, Y. Wang, S. Cheng, H. Liu, and B. Zheng, "A new approach to develop computer-aided diagnosis scheme of breast mass classification using deep learning technology," *J. X-Ray Sci. Technol.*, vol. 25, no. 5, pp. 751–763, Oct. 2017.
- [24] R. K. Samala, H.-P. Chan, L. M. Hadjiiski, M. A. Helvie, K. H. Cha, and C. D. Richter, "Multi-task transfer learning deep convolutional neural network: Application to computer-aided diagnosis of breast cancer on mammograms," *Phys. Med. Biol.*, vol. 62, no. 23, pp. 8894–8908, Nov. 2017.
- [25] C. D. L. Nascimento, S. D. D. S. Silva, T. A. D. Silva, W. C. D. A. Pereira, M. G. F. Costa, and C. F. F. Costa Filho, "Breast tumor classification in ultrasound images using support vector machines and neural networks," *Res. Biomed. Eng.*, vol. 32, no. 3, pp. 283–292, Oct. 2016.
- [26] J. H. Youk, H. M. Gweon, and E. J. Son, "Shear-wave elastography in breast ultrasonography: The state of the art," *Ultrasonography*, vol. 36, no. 4, pp. 300–309, Oct. 2017.

- [27] G. Amit, R. Ben-Ari, O. Hadad, E. Monovich, N. Granot, and S. Hashoul, "Classification of breast MRI lesions using small-size training sets: Comparison of deep learning approaches," in *Proc. Med. Imag., Comput.-Aided Diagnosis*, vol. 10134, 2017, pp. 374–379.
- [28] N. Antropova, B. Q. Huynh, and M. L. Giger, "A deep feature fusion methodology for breast cancer diagnosis demonstrated on three imaging modality datasets," *Med. Phys.*, vol. 44, no. 10, pp. 5162–5171, Oct. 2017.
- [29] R. Rasti, M. Teshnehlab, and S. L. Phung, "Breast cancer diagnosis in DCE-MRI using mixture ensemble of convolutional neural networks," *Pattern Recognit.*, vol. 72, pp. 381–390, Dec. 2017.
- [30] J. de Nazaré Silva, A. O. de Carvalho Filho, A. C. Silva, A. C. de Paiva, and M. Gattass, "Automatic detection of masses in mammograms using quality threshold clustering, correlogram function, and SVM," *J. Digit. Imag.*, vol. 28, no. 3, pp. 323–337, Jun. 2015.
- [31] J. Y. Choi, "A generalized multiple classifier system for improving computer-aided classification of breast masses in mammography," *Biomed. Eng. Lett.*, vol. 5, no. 4, pp. 251–262, Dec. 2015.
- [32] P. Casti, A. Mencattini, M. Salmeri, A. Ancona, M. Lorusso, M. L. Pepe, C. D. Natale, and E. Martinielli, "Towards localization of malignant sites of asymmetry across bilateral mammograms," *Comput. Methods Programs Biomed.*, vol. 140, pp. 11–18, Mar. 2017.
- [33] A.-A. Nahid, F. B. Ali, and Y. Kong, "Histopathological breast-image classification with image enhancement by convolutional neural network," in *Proc. 20th Int. Conf. Comput. Inf. Technol. (ICCIT)*, Dec. 2017, pp. 1–6.
- [34] B. E. Bejnordi, G. Zuidhof, M. Balkenhol, M. Hermsen, P. Bult, B. van Ginneken, N. Karssemeijer, G. Litjens, and J. van der Laak, "Context-aware stacked convolutional neural networks for classification of breast carcinomas in whole-slide histopathology images," *J. Med. Imag.*, vol. 4, no. 4, pp. 1–8, 2017.
- [35] Y. Feng, L. Zhang, and Z. Yi, "Breast cancer cell nuclei classification in histopathology images using deep neural networks," *Int. J. Comput. Assist. Radiol. Surg.*, vol. 13, no. 2, pp. 179–191, Feb. 2018.
- [36] S. Punitha, A. Amuthan, and K. S. Joseph, "Benign and malignant breast cancer segmentation using optimized region growing technique," *Future Comput. Informat. J.*, vol. 3, no. 2, pp. 348–358, Dec. 2018.
- [37] H. Strange, Z. Chen, E. R. E. Denton, and R. Zwiiggelaar, "Modelling mammographic microcalcification clusters using persistent mereotopology," *Pattern Recognit. Lett.*, vol. 47, pp. 157–163, Oct. 2014.
- [38] B. Kitchenham, O. P. Brereton, D. Budgen, M. Turner, J. Bailey, and S. Linkman, "Systematic literature reviews in software engineering—A systematic literature review," *Inf. Softw. Technol.*, vol. 55, no. 6, pp. 919–920, 2013.
- [39] V. Alves, N. Niu, C. Alves, and G. Valença, "Requirements engineering for software product lines: A systematic literature review," *Inf. Softw. Technol.*, vol. 52, no. 8, pp. 806–820, Aug. 2010.
- [40] *Screening and Early Detection of Breast Cancer*. Accessed: Aug. 24, 2020. [Online]. Available: <https://ww5.komen.org/breastcancer/earlydetectionampscreening.html>
- [41] S. Saini and R. Vijay, "Mammogram analysis using feed-forward back propagation and cascade-forward back propagation artificial neural network," in *Proc. 5th Int. Conf. Commun. Syst. Netw. Technol.*, Apr. 2015, pp. 1177–1180.
- [42] M. A. Al-antari, M. A. Al-masni, M.-T. Choi, S.-M. Han, and T.-S. Kim, "A fully integrated computer-aided diagnosis system for digital X-ray mammograms via deep learning detection, segmentation, and classification," *Int. J. Med. Informat.*, vol. 117, pp. 44–54, Sep. 2018.
- [43] N. Zemmal, N. Azizi, and M. Sellami, "CAD system for classification of mammographic abnormalities using transductive semi supervised learning algorithm and heterogeneous features," in *Proc. 12th Int. Symp. Program. Syst. (ISPS)*, Apr. 2015, pp. 1–9.
- [44] D. Saraswathi and E. Srinivasan, "A CAD system to analyse mammogram images using fully complex-valued relaxation neural network ensemble classifier," *J. Med. Eng. Technol.*, vol. 38, no. 7, pp. 359–366, Oct. 2014.
- [45] A. A. Mohamed, W. A. Berg, H. Peng, Y. Luo, R. C. Jankowitz, and S. Wu, "A deep learning method for classifying mammographic breast density categories," *Med. Phys.*, vol. 45, no. 1, pp. 314–321, Jan. 2018.
- [46] D. A. Ragab, M. Sharkas, S. Marshall, and J. Ren, "Breast cancer detection using deep convolutional neural networks and support vector machines," *PeerJ*, vol. 7, pp. 1–23, Jan. 2019.
- [47] B. Q. Huynh, H. Li, and M. L. Giger, "Digital mammographic tumor classification using transfer learning from deep convolutional neural networks," *J. Med. Imag.*, vol. 3, no. 3, pp. 1–5, 2016.
- [48] J. Arevalo, F. A. González, R. Ramos-Pollán, J. L. Oliveira, and M. A. G. Lopez, "Convolutional neural networks for mammography mass lesion classification," in *Proc. 37th Annu. Int. Conf. IEEE Eng. Med. Biol. Soc. (EMBC)*, Aug. 2015, pp. 797–800.
- [49] N. Dhungel, G. Carneiro, and A. P. Bradley, "A deep learning approach for the analysis of masses in mammograms with minimal user intervention," *Med. Image Anal.*, vol. 37, pp. 114–128, Apr. 2017.
- [50] G. Carneiro, J. Nascimento, and A. P. Bradley, "Automated analysis of unregistered multi-view mammograms with deep learning," *IEEE Trans. Med. Imag.*, vol. 36, no. 11, pp. 2355–2365, Nov. 2017.
- [51] M. Shibusawa, R. Nakayama, Y. Okanami, Y. Kashikura, N. Imai, T. Nakamura, H. Kimura, M. Yamashita, N. Hanamura, and T. Ogawa, "The usefulness of a computer-aided diagnosis scheme for improving the performance of clinicians to diagnose non-mass lesions on breast ultrasonographic images," *J. Med. Ultrason.*, vol. 43, no. 3, pp. 387–394, Jul. 2016.
- [52] Y. Chen and Q. Huang, "An approach based on biclustering and neural network for classification of lesions in breast ultrasound," in *Proc. Int. Conf. Adv. Robot. Mechatronics (ICARM)*, Aug. 2016, pp. 597–601.
- [53] M. Abdel-Nasser, J. Melendez, A. Moreno, O. A. Omer, and D. Puig, "Breast tumor classification in ultrasound images using texture analysis and super-resolution methods," *Eng. Appl. Artif. Intell.*, vol. 59, pp. 84–92, Mar. 2017.
- [54] V. Bevilacqua, A. Brunetti, M. Triggiani, D. Magaletti, M. Telegrafo, and M. Moschetta, "An optimized feed-forward artificial neural network topology to support radiologists in breast lesions classification," in *Proc. Genetic Evol. Comput. Conf. Companion (GECCO Companion)*, 2016, pp. 1385–1392.
- [55] K. Kerlikowske, D. Grady, S. M. Rubin, C. Sandrock, and V. L. Ernster, "Efficacy of screening mammography. A meta-analysis," *JAMA, J. Amer. Med. Assoc.*, vol. 273, no. 2, pp. 149–154, Jan. 1995.
- [56] D. C. Slawson and M. L. Coates, "Efficacy of screening mammography," *J. Family Pract.*, vol. 40, no. 6, pp. 602–603, 1995.
- [57] A. Jalalian, S. Mashohor, R. Mahmud, B. Karasfi, M. I. B. Saripan, and A. R. B. Ramli, "Foundation and methodologies in computer-aided diagnosis systems for breast cancer detection," *EXCLI J.*, vol. 16, pp. 113–137, Feb. 2017.
- [58] J. Diz, G. Marreiros, and A. Freitas, "Applying data mining techniques to improve breast cancer diagnosis," *J. Med. Syst.*, vol. 40, no. 9, pp. 1–7, Sep. 2016.
- [59] W. Xie, Y. Li, and Y. Ma, "Breast mass classification in digital mammography based on extreme learning machine," *Neurocomputing*, vol. 173, pp. 930–941, Jan. 2016.
- [60] N. F. Abubacker, A. Azman, S. Doraisamy, and M. A. A. Murad, "An integrated method of associative classification and neuro-fuzzy approach for effective mammographic classification," *Neural Comput. Appl.*, vol. 28, no. 12, pp. 3967–3980, Dec. 2017.
- [61] S. Aminikhanghahi, S. Shin, W. Wang, S. I. Jeon, and S. H. Son, "A new fuzzy Gaussian mixture model (FGMM) based algorithm for mammography tumor image classification," *Multimedia Tools Appl.*, vol. 76, no. 7, pp. 10191–10205, Apr. 2017.
- [62] S. Suzuki, X. Zhang, N. Homma, K. Ichiji, N. Sugita, Y. Kawasumi, T. Ishibashi, and M. Yoshizawa, "Mass detection using deep convolutional neural network for mammographic computer-aided diagnosis," in *Proc. 55th Annu. Conf. Soc. Instrum. Control Engineers Jpn. (SICE)*, Sep. 2016, pp. 1382–1386.
- [63] S. Sharma and P. Khanna, "Computer-aided diagnosis of malignant mammograms using Zernike moments and SVM," *J. Digit. Imag.*, vol. 28, no. 1, pp. 77–90, Feb. 2015.
- [64] W. Peng, R. V. Mayorga, and E. M. A. Hussein, "An automated confirmatory system for analysis of mammograms," *Comput. Methods Programs Biomed.*, vol. 125, pp. 134–144, Mar. 2016.
- [65] S. P. Singh and S. Urooj, "An improved CAD system for breast cancer diagnosis based on generalized pseudo-Zernike moment and ada-DEWNN classifier," *J. Med. Syst.*, vol. 40, no. 4, pp. 1–13, Apr. 2016.
- [66] R. M. Mann et al., "Breast MRI: Eusobi recommendations for women's information," *Eur. Radiol.*, vol. 25, no. 12, pp. 3669–3678, 2015.
- [67] M. Tan, J. Pu, and B. Zheng, "Optimization of breast mass classification using sequential forward floating selection (SFFS) and a support vector machine (SVM) model," *Int. J. Comput. Assist. Radiol. Surgery*, vol. 9, no. 6, pp. 1005–1020, Nov. 2014.
- [68] S. Ergin and O. Kilinc, "A new feature extraction framework based on wavelets for breast cancer diagnosis," *Comput. Biol. Med.*, vol. 51, pp. 171–182, Aug. 2014.

- [69] L. Vivona, D. Cascio, F. Fauci, and G. Raso, "Fuzzy technique for microcalcifications clustering in digital mammograms," *BMC Med. Imag.*, vol. 14, no. 1, pp. 1–18, Dec. 2014.
- [70] Z. Chen, H. Strange, A. Oliver, E. R. E. Denton, C. Boggis, and R. Zwiggelaar, "Topological modeling and classification of mammographic microcalcification clusters," *IEEE Trans. Biomed. Eng.*, vol. 62, no. 4, pp. 1203–1214, Apr. 2015.
- [71] G. Rahbar, A. C. Sie, G. C. Hansen, J. S. Prince, M. L. Melany, H. E. Reynolds, V. P. Jackson, J. W. Sayre, and L. W. Bassett, "Benign versus malignant solid breast masses: US differentiation," *Radiology*, vol. 213, no. 3, pp. 889–894, Dec. 1999.
- [72] M. Abdel-Nasser, H. A. Rashwan, D. Puig, and A. Moreno, "Analysis of tissue abnormality and breast density in mammographic images using a uniform local directional pattern," *Expert Syst. Appl.*, vol. 42, no. 24, pp. 9499–9511, Dec. 2015.
- [73] H. de la Rosa Toro and M. M. Fernández, "Architectural distortion of the breast: Diagnostic and management algorithm," in *Proc. Eur. Congr. Radiol. (ECR)*, 2018, p. C-0166.
- [74] R. Zwiggelaar, T. C. Parr, J. E. Schumm, I. W. Hutt, C. J. Taylor, S. M. Astley, and C. R. M. Boggis, "Model-based detection of spiculated lesions in mammograms," *Med. Image Anal.*, vol. 3, no. 1, pp. 39–62, Mar. 1999.
- [75] A. T. Azar and S. A. El-Said, "Performance analysis of support vector machines classifiers in breast cancer mammography recognition," *Neural Comput. Appl.*, vol. 24, no. 5, pp. 1163–1177, Apr. 2014.
- [76] I. I. Esener, S. Ergin, and T. Yüksel, "A new ensemble of features for breast cancer diagnosis," in *Proc. 38th Int. Conv. Inf. Commun. Technol., Electron. Microelectron. (MIPRO)*, May 2015, pp. 1168–1173.
- [77] X. Liu, M. Mei, J. Liu, and W. Hu, "Microcalcification detection in full-field digital mammograms with PFCM clustering and weighted SVM-based method," *EURASIP J. Adv. Signal Process.*, vol. 2015, no. 1, pp. 1–13, Dec. 2015.
- [78] C. K. Ahn, C. Heo, H. Jin, and J. H. Kim, "A novel deep learning-based approach to high accuracy breast density estimation in digital mammography," in *Proc. Med. Imag., Comput.-Aided Diagnosis*, vol. 10134, 2017, pp. 691–697.
- [79] T. M. A. Basile, A. Fanizzi, L. Losurdo, R. Bellotti, U. Bottigli, R. Dentamaro, V. Didonna, A. Fausto, R. Massafra, M. Moschetta, P. Tamborra, S. Tangaro, and D. La Forgia, "Microcalcification detection in full-field digital mammograms: A fully automated computer-aided system," *Phys. Medica*, vol. 64, pp. 1–9, Aug. 2019.
- [80] T. Kooi, G. Litjens, B. van Ginneken, A. Gubern-Mérida, C. I. Sánchez, R. Mann, A. den Heeten, and N. Karsssemeijer, "Large scale deep learning for computer aided detection of mammographic lesions," *Med. Image Anal.*, vol. 35, pp. 303–312, Jan. 2017.
- [81] P. B. Ribeiro, L. A. Passos, L. A. D. Silva, K. A. P. da Costa, J. P. Papa, and R. A. F. Romero, "Unsupervised breast masses classification through optimum-path forest," in *Proc. IEEE 28th Int. Symp. Comput.-Based Med. Syst.*, Jun. 2015, pp. 238–243.
- [82] M. Abdar, M. Zomorodi-Moghadam, X. Zhou, R. Gururajan, X. Tao, P. D. Barua, and R. Gururajan, "A new nested ensemble technique for automated diagnosis of breast cancer," *Pattern Recognit. Lett.*, vol. 132, pp. 123–131, Apr. 2020.
- [83] Y. Liu, L. Ren, X. Cao, and Y. Tong, "Breast tumors recognition based on edge feature extraction using support vector machine," *Biomed. Signal Process. Control*, vol. 58, pp. 1–8, Apr. 2020.
- [84] A. Sakai, Y. Onishi, M. Matsui, H. Adachi, A. Teramoto, K. Saito, and H. Fujita, "A method for the automated classification of benign and malignant masses on digital breast tomosynthesis images using machine learning and radiomic features," *Radiol. Phys. Technol.*, vol. 13, no. 1, pp. 27–36, Mar. 2020.
- [85] R. Vijayarajeswari, P. Parthasarathy, S. Vivekanandan, and A. A. Basha, "Classification of mammogram for early detection of breast cancer using SVM classifier and Hough transform," *Measurement*, vol. 146, pp. 800–805, Nov. 2019.
- [86] X. Liu and Z. Zeng, "A new automatic mass detection method for breast cancer with false positive reduction," *Neurocomputing*, vol. 152, pp. 388–402, Mar. 2015.
- [87] U. Raghavendra, U. R. Acharya, H. Fujita, A. Gudigar, J. H. Tan, and S. Chokkadi, "Application of Gabor wavelet and locality sensitive discriminant analysis for automated identification of breast cancer using digitized mammogram images," *Appl. Soft Comput.*, vol. 46, pp. 151–161, Sep. 2016.
- [88] L. Cai, X. Wang, Y. Wang, Y. Guo, J. Yu, and Y. Wang, "Robust phase-based texture descriptor for classification of breast ultrasound images," *Biomed. Eng. OnLine*, vol. 14, no. 1, pp. 1–21, Dec. 2015.
- [89] A. Ul-Haq, J. Li, M. H. Memon, J. Khan, and S. Ud Din, "A novel integrated diagnosis method for breast cancer detection," *J. Intell. Fuzzy Syst.*, vol. 38, no. 2, pp. 2383–2398, Feb. 2020.
- [90] S. K. Wajid and A. Hussain, "Local energy-based shape histogram feature extraction technique for breast cancer diagnosis," *Expert Syst. Appl.*, vol. 42, no. 20, pp. 6990–6999, Nov. 2015.
- [91] S. Khan, M. Hussain, H. Aboalsamh, and G. Bebis, "A comparison of different Gabor feature extraction approaches for mass classification in mammography," *Multimedia Tools Appl.*, vol. 76, no. 1, pp. 33–57, Jan. 2017.
- [92] S. Dhahbi, W. Barhoumi, and E. Zagrouba, "Breast cancer diagnosis in digitized mammograms using curvelet moments," *Comput. Biol. Med.*, vol. 64, pp. 79–90, Sep. 2015.
- [93] S. J. S. Gardezi, I. Faye, J. M. S. Bornot, N. Kamel, and M. Hussain, "Mammogram classification using dynamic time warping," *Multimedia Tools Appl.*, vol. 77, no. 3, pp. 3941–3962, Feb. 2018.
- [94] A. A. Ali, S. Mishra, and B. Dappuri, "Breast cancer classification using tetrolet transform based energy features and k-nearest neighbor classifier," in *Recent Trends and Advances in Artificial Intelligence and Internet of Things*. Cham, Switzerland: Springer, 2020, pp. 39–46.
- [95] J. Shan, S. K. Alam, B. Garra, Y. Zhang, and T. Ahmed, "Computer-aided diagnosis for breast ultrasound using computerized BI-RADS features and machine learning methods," *Ultrasound Med. Biol.*, vol. 42, no. 4, pp. 980–988, Apr. 2016.
- [96] D. O. T. Bruno, M. Z. do Nascimento, R. P. Ramos, V. R. Batista, L. A. Neves, and A. S. Martins, "LBP operators on curvelet coefficients as an algorithm to describe texture in breast cancer tissues," *Expert Syst. Appl.*, vol. 55, pp. 329–340, Aug. 2016.
- [97] S. Wang, Y. Wang, D. Wang, Y. Yin, Y. Wang, and Y. Jin, "An improved random forest-based rule extraction method for breast cancer diagnosis," *Appl. Soft Comput.*, vol. 86, pp. 1–35, Jan. 2020.
- [98] L. Chen, Z. Zhang, J. Cao, and X. Wang, "A novel method of combining nonlinear frequency spectrum and deep learning for complex system fault diagnosis," *Measurement*, vol. 151, pp. 1–18, Feb. 2020.
- [99] A. Suresh, R. Udendhran, and M. Balamurgan, "Hybridized neural network and decision tree based classifier for prognostic decision making in breast cancers," *Soft Comput.*, vol. 24, no. 11, pp. 7947–7953, Jun. 2020.
- [100] W. K. Moon, I.-L. Chen, J. M. Chang, S. U. Shin, C.-M. Lo, and R.-F. Chang, "The adaptive computer-aided diagnosis system based on tumor sizes for the classification of breast tumors detected at screening ultrasound," *Ultrasonics*, vol. 76, pp. 70–77, Apr. 2017.
- [101] C.-M. Lo, W. K. Moon, C.-S. Huang, J.-H. Chen, M.-C. Yang, and R.-F. Chang, "Intensity-invariant texture analysis for classification of BI-RADS category 3 breast masses," *Ultrasound Med. Biol.*, vol. 41, no. 7, pp. 2039–2048, Jul. 2015.
- [102] J. Sultana and A. K. Jilani, "Predicting breast cancer using logistic regression and multi-class classifiers," *Int. J. Eng. Technol.*, vol. 7, no. 4.20, pp. 22–26, 2018.
- [103] H. Dhahri, I. Rahmany, A. Mahmood, E. Al Maghayreh, and W. Elkilani, "Tabu search and machine-learning classification of benign and malignant proliferative breast lesions," *BioMed Res. Int.*, vol. 2020, pp. 1–10, Feb. 2020.
- [104] M. Hamoud, H. F. Merouani, and L. Laimeche, "The power laws: Zipf and inverse zipf for automated segmentation and classification of masses within mammograms," *Evolving Syst.*, vol. 6, no. 3, pp. 209–227, Sep. 2015.
- [105] U. Shrivastav, S. K. Singh, and A. Khamparia, "A novel approach to detect edge in digital image using fuzzy logic," in *Proc. 1st Int. Conf. Sustain. Technol. Comput. Intell.* Singapore: Springer, 2020, pp. 63–74.
- [106] B. A. Mohammed and M. S. Al-Ani, "Digital medical image segmentation using fuzzy C-means clustering," *UHD J. Sci. Technol.*, vol. 4, no. 1, pp. 51–58, 2020.
- [107] Z. Wang, G. Yu, Y. Kang, Y. Zhao, and Q. Qu, "Breast tumor detection in digital mammography based on extreme learning machine," *Neurocomputing*, vol. 128, pp. 175–184, Mar. 2014.
- [108] R. F. Mansour, "A robust deep neural network based breast cancer detection and classification," *Int. J. Comput. Intell. Appl.*, vol. 19, no. 1, pp. 1–19, 2020.

- [109] S. S. Venkatesh, B. J. Levenback, L. R. Sultan, G. Bouzghar, and C. M. Sehgal, "Going beyond a first reader: A machine learning methodology for optimizing cost and performance in breast ultrasound diagnosis," *Ultrasound Med. Biol.*, vol. 41, no. 12, pp. 3148–3162, Dec. 2015.
- [110] J. Zheng, D. Lin, Z. Gao, S. Wang, M. He, and J. Fan, "Deep learning assisted efficient AdaBoost algorithm for breast cancer detection and early diagnosis," *IEEE Access*, vol. 8, pp. 96946–96954, 2020.
- [111] R. Sanchez de la Rosa, M. Lamard, G. Cazuguel, G. Coatrieux, M. Cozic, and G. Quellec, "Multiple-instance learning for breast cancer detection in mammograms," in *Proc. 37th Annu. Int. Conf. IEEE Eng. Med. Biol. Soc. (EMBC)*, Aug. 2015, pp. 7055–7058.
- [112] H. Mahersia, H. Boulehmi, and K. Hamrouni, "Development of intelligent systems based on Bayesian regularization network and neuro-fuzzy models for mass detection in mammograms: A comparative analysis," *Comput. Methods Programs Biomed.*, vol. 126, pp. 46–62, Apr. 2016.
- [113] M. Z. D. Nascimento, A. S. Martins, L. A. Neves, R. P. Ramos, E. L. Flores, and G. A. Carrizo, "Classification of masses in mammographic image using wavelet domain features and polynomial classifier," *Expert Syst. Appl.*, vol. 40, no. 15, pp. 6213–6221, Nov. 2013.
- [114] W.-J. Wu, S.-W. Lin, and W. K. Moon, "An artificial immune system-based support vector machine approach for classifying ultrasound breast tumor images," *J. Digit. Imag.*, vol. 28, no. 5, pp. 576–585, Oct. 2015.
- [115] J. Xing, Z. Li, B. Wang, Y. Qi, B. Yu, F. G. Zanjani, A. Zheng, R. Duits, and T. Tan, "Lesion segmentation in ultrasound using semi-pixel-wise cycle generative adversarial nets," *IEEE/ACM Trans. Comput. Biol. Bioinf.*, Mar. 2020, pp. 1–10.
- [116] J. Xu, C. Li, Y. Zhou, L. Mou, H. Zheng, and S. Wang, "Classifying mammographic breast density by residual learning," *CoRR*, vol. abs/1809.10241, pp. 1–11, Sep. 2018.
- [117] H. Cai, Q. Huang, W. Rong, Y. Song, J. Li, J. Wang, J. Chen, and L. Li, "Breast microcalcification diagnosis using deep convolutional neural network from digital mammograms," *Comput. Math. Methods Med.*, vol. 2019, pp. 1–10, Mar. 2019.
- [118] J. Arevalo, F. A. González, R. Ramos-Pollán, J. L. Oliveira, and M. A. G. Lopez, "Representation learning for mammography mass lesion classification with convolutional neural networks," *Comput. Methods Programs Biomed.*, vol. 127, pp. 248–257, Apr. 2016.
- [119] J. S. Suri, Y. Sun, and R. Janer, "Method for breast screening in fused mammography," U.S. Patent 10 363 010, Jul. 30, 2019, pp. 1–38.
- [120] M. Pratiwi, Alexander, J. Harefa, and S. Nanda, "Mammograms classification using gray-level co-occurrence matrix and radial basis function neural network," *Procedia Comput. Sci.*, vol. 59, pp. 83–91, Jan. 2015.
- [121] A. Duggento, M. Aiello, C. Cavaliere, G. L. Cascella, D. Cascella, G. Conte, M. Guerri, and N. Toschi, "An ad hoc random initialization deep neural network architecture for discriminating malignant breast cancer lesions in mammographic images," *Contrast Media Mol. Imag.*, vol. 2019, pp. 1–9, May 2019.
- [122] A. Oliver, J. Freixenet, J. Martí, E. Pérez, J. Pont, E. R. E. Denton, and R. Zwiggehaar, "A review of automatic mass detection and segmentation in mammographic images," *Med. Image Anal.*, vol. 14, no. 2, pp. 87–110, Apr. 2010.
- [123] F. S. S. de Oliveira, A. O. de Carvalho Filho, A. C. Silva, A. C. de Paiva, and M. Gattass, "Classification of breast regions as mass and non-mass based on digital mammograms using taxonomic indexes and SVM," *Comput. Biol. Med.*, vol. 57, pp. 42–53, Feb. 2015.
- [124] W. Zhu, X. Xiang, T. D. Tran, G. D. Hager, and X. Xie, "Adversarial deep structured nets for mass segmentation from mammograms," in *Proc. IEEE 15th Int. Symp. Biomed. Imag. (ISBI)*, Apr. 2018, pp. 847–850.
- [125] W. Jian, X. Sun, and S. Luo, "Computer-aided diagnosis of breast microcalcifications based on dual-tree complex wavelet transform," *Biomed. Eng. online*, vol. 11, no. 1, pp. 1–12, 2012.
- [126] S. Chen, J.-C. Chien, and H. Jin, "Metadata-driven method and apparatus for constraining solution space in image processing techniques," U.S. Patent Appl. 10/068 317, Sep. 4, 2018, pp. 1–52.
- [127] V. P. Ananthi, P. Balasubramaniam, and P. Raveendran, "A thresholding method based on interval-valued intuitionistic fuzzy sets: An application to image segmentation," *Pattern Anal. Appl.*, vol. 21, no. 4, pp. 1039–1051, Nov. 2018.
- [128] B. Lei and J. Fan, "Image thresholding segmentation method based on minimum square rough entropy," *Appl. Soft Comput.*, vol. 84, pp. 1–12, Nov. 2019.
- [129] F. Pak, H. R. Kanan, and A. Alikhassi, "Breast cancer detection and classification in digital mammography based on non-subsampled contourlet transform (NSCT) and super resolution," *Comput. Methods Programs Biomed.*, vol. 122, no. 2, pp. 89–107, Nov. 2015.
- [130] M. Kallenberg, K. Petersen, M. Nielsen, A. Y. Ng, P. Diao, C. Igel, C. M. Vachon, K. Holland, R. R. Winkel, N. Karssemeijer, and M. Lillholm, "Unsupervised deep learning applied to breast density segmentation and mammographic risk scoring," *IEEE Trans. Med. Imag.*, vol. 35, no. 5, pp. 1322–1331, May 2016.
- [131] W. Sun, T.-L. Tseng, J. Zhang, and W. Qian, "Enhancing deep convolutional neural network scheme for breast cancer diagnosis with unlabeled data," *Comput. Med. Imag. Graph.*, vol. 57, pp. 4–9, Apr. 2017.
- [132] A. S. Becker, M. Marcon, S. Ghafoor, M. C. Wurnig, T. Frauenfelder, and A. Boss, "Deep learning in mammography: Diagnostic accuracy of a multipurpose image analysis software in the detection of breast cancer," *Investigative Radiol.*, vol. 52, no. 7, pp. 434–440, Jul. 2017.
- [133] A. Esteva, A. Robicquet, B. Ramsundar, V. Kuleshov, M. DePristo, K. Chou, C. Cui, G. Corrado, S. Thrun, and J. Dean, "A guide to deep learning in healthcare," *Nature Med.*, vol. 25, no. 1, pp. 24–29, Jan. 2019.
- [134] G. V. Ionescu, M. Fergie, M. Berks, E. F. Harkness, J. Hulleman, A. R. Brentnall, J. Cuzick, D. G. Evans, and S. M. Astley, "Prediction of reader estimates of mammographic density using convolutional neural networks," *J. Med. Imag.*, vol. 6, no. 3, pp. 1–15, 2019.
- [135] N. E. Benzebouchi, N. Azizi, and K. Ayadi, "A computer-aided diagnosis system for breast cancer using deep convolutional neural networks," in *Computational Intelligence in Data Mining*, vol. 711. Singapore: Springer, 2019, pp. 583–593.
- [136] F. Y. Zhou, L. P. Jin, and J. Dong, "Review of convolutional neural network," *Chin. J. Comput.*, vol. 40, no. 6, pp. 1229–1251, Jun. 2017.
- [137] J. Shi, J. Wu, Y. Li, Q. Zhang, and S. Ying, "Histopathological image classification with color pattern random binary hashing-based PCANet and matrix-form classifier," *IEEE J. Biomed. Health Informat.*, vol. 21, no. 5, pp. 1327–1337, Sep. 2017.
- [138] R. Rouhi and M. Jafari, "Classification of benign and malignant breast tumors based on hybrid level set segmentation," *Expert Syst. Appl.*, vol. 46, pp. 45–59, Mar. 2016.
- [139] W. Sun, T.-L. Tseng, J. Zhang, and W. Qian, "Computerized breast cancer analysis system using three stage semi-supervised learning method," *Comput. Methods Programs Biomed.*, vol. 135, pp. 77–88, Oct. 2016.
- [140] G. Murtaza, L. Shuib, A. W. A. Wahab, G. Mujtaba, and G. Raza, "Ensembled deep convolution neural network-based breast cancer classification with misclassification reduction algorithms," *Multimedia Tools Appl.*, vol. 79, nos. 25–26, pp. 18447–18479, Jul. 2020.
- [141] Z. Jiao, X. Gao, Y. Wang, and J. Li, "A deep feature based framework for breast masses classification," *Neurocomputing*, vol. 197, pp. 221–231, Jul. 2016.
- [142] B. Sanae, E. M. Samira, A. K. Mounir, and F. Youssef, "Statistical block-based DWT features for digital mammograms classification," in *Proc. 9th Int. Conf. Intell. Syst., Theories Appl. (SITA)*, May 2014, pp. 1–7.
- [143] N. Azizi, N. Zemmam, M. Sellami, and N. Farah, "A new hybrid method combining genetic algorithm and support vector machine classifier: Application to CAD system for mammogram images," in *Proc. Int. Conf. Multimedia Comput. Syst. (ICMCS)*, Apr. 2014, pp. 415–420.
- [144] P. Li, T. Bi, J. Huang, and S. Li, "Breast cancer early diagnosis based on hybrid strategy," *Bio-Medical Mater. Eng.*, vol. 24, no. 6, pp. 3397–3404, 2014.
- [145] S. M. A. Beheshti, H. AhmadiNoubari, E. Fatemizadeh, and M. Khalili, "An efficient fractal method for detection and diagnosis of breast masses in mammograms," *J. Digit. Imag.*, vol. 27, no. 5, pp. 661–669, Oct. 2014.
- [146] A. Oliver, J. Freixenet, and R. Zwiggehaar, "Automatic classification of breast density," in *Proc. IEEE Int. Conf. Image Process.*, vol. 2, Jun. 2005, pp. 1258–1261.
- [147] L. M. Mina and N. A. Mat Isa, "Breast abnormality detection in mammograms using artificial neural network," in *Proc. Int. Conf. Comput., Commun., Control Technol. (ICCT)*, Apr. 2015, pp. 258–263.
- [148] A. Chmielewski, P. Dufort, and A. M. Scaranelo, "A computerized system to assess axillary lymph node malignancy from sonographic images," *Ultrasound Med. Biol.*, vol. 41, no. 10, pp. 2690–2699, Oct. 2015.

- [149] M. Dong, X. Lu, Y. Ma, Y. Guo, Y. Ma, and K. Wang, "An efficient approach for automated mass segmentation and classification in mammograms," *J. Digit. Imag.*, vol. 28, no. 5, pp. 613–625, Oct. 2015.
- [150] A. F. Khalaf and I. A. Yassine, "Spectral correlation analysis for microcalcification detection in digital mammogram images," in *Proc. IEEE 12th Int. Symp. Biomed. Imag. (ISBI)*, Apr. 2015, pp. 88–91.
- [151] A. F. Khalaf and I. A. Yassine, "Novel features for microcalcification detection in digital mammogram images based on wavelet and statistical analysis," in *Proc. IEEE Int. Conf. Image Process. (ICIP)*, Sep. 2015, pp. 1825–1829.
- [152] G. Quellec, M. Lamard, M. Cozic, G. Coatrieux, and G. Cazuguel, "Multiple-instance learning for anomaly detection in digital mammography," *IEEE Trans. Med. Imag.*, vol. 35, no. 7, pp. 1604–1614, Jul. 2016.
- [153] N. Vázquez, G. Bueno, O. Déniz, J. Dorado, J. A. Seoane, A. Pazos, and C. Pastor, "Breast density classification to reduce false positives in CADe systems," *Comput. Methods Programs Biomed.*, vol. 113, no. 2, pp. 569–584, Feb. 2014.
- [154] A. C. Phadke and P. P. Rege, "Fusion of local and global features for classification of abnormality in mammograms," *Sādhanā*, vol. 41, no. 4, pp. 385–395, Apr. 2016.
- [155] Q. Huang, F. Yang, L. Liu, and X. Li, "Automatic segmentation of breast lesions for interaction in ultrasonic computer-aided diagnosis," *Inf. Sci.*, vol. 314, pp. 293–310, Sep. 2015.
- [156] F. Burling-Claridge, M. Iqbal, and M. Zhang, "Evolutionary algorithms for classification of mammographic densities using local binary patterns and statistical features," in *Proc. IEEE Congr. Evol. Comput. (CEC)*, Jul. 2016, pp. 3847–3854.
- [157] M. A. S. Ali, G. I. Sayed, T. Gaber, A. E. Hassanien, V. Snasel, and L. F. Silva, "Detection of breast abnormalities of thermograms based on a new segmentation method," in *Proc. Federated Conf. Comput. Sci. Inf. Syst. (FedCSIS)*, Oct. 2015, pp. 255–261.
- [158] M. Milosevic, D. Jankovic, and A. Peulic, "Thermography based breast cancer detection using texture features and minimum variance quantization," *EXCLI J.*, vol. 13, pp. 1204–1215, Nov. 2014.
- [159] H. Li, M. L. Giger, B. Q. Huynh, and N. O. Antropova, "Deep learning in breast cancer risk assessment: Evaluation of convolutional neural networks on a clinical dataset of full-field digital mammograms," *J. Med. Imag.*, vol. 4, no. 4, pp. 1–6, 2017.
- [160] M. Tan, B. Zheng, P. Ramalingam, and D. Gur, "Prediction of near-term breast cancer risk based on bilateral mammographic feature asymmetry," *Acad. Radiol.*, vol. 20, no. 12, pp. 1542–1550, Dec. 2013.
- [161] K. M. Prabusankaral, P. Thirumoorthy, and R. Manavalan, "Assessment of combined textural and morphological features for diagnosis of breast masses in ultrasound," *Hum.-Centric Comput. Inf. Sci.*, vol. 5, no. 1, pp. 1–17, Dec. 2015.
- [162] S. V. Francis, M. Sasikala, and S. Saranya, "Detection of breast abnormality from thermograms using curvelet transform based feature extraction," *J. Med. Syst.*, vol. 38, no. 4, pp. 1–9, Apr. 2014.
- [163] N. Wu, K. J. Geras, Y. Shen, J. Su, S. Gene Kim, E. Kim, S. Wolfson, L. Moy, and K. Cho, "Breast density classification with deep convolutional neural networks," in *Proc. IEEE Int. Conf. Acoust., Speech Signal Process. (ICASSP)*, Apr. 2018, pp. 6682–6686.
- [164] C.-M. Lo, S.-W. Chan, Y.-W. Yang, Y.-C. Chang, C.-S. Huang, Y.-S. Jou, and R.-F. Chang, "Feasibility testing: Three-dimensional tumor mapping in different orientations of automated breast ultrasound," *Ultrasound Med. Biol.*, vol. 42, no. 5, pp. 1201–1210, May 2016.



TARIQ MAHMOOD received the M.S. degree in computer science from the University of Lahore, Lahore, Pakistan, and the M.Sc. degree in information technology from the University of Education at Lahore, Lahore. He is currently pursuing the Ph.D. degree with the Beijing University of Technology, Beijing, China, under the supervision of Dr. J. Li. His research interests include machine learning, image processing, data mining, WSNs, and cloud computing.



JIANQIANG LI (Senior Member, IEEE) received the B.S. degree in mechatronics from the Beijing Institute of Technology, Beijing, China, in 1996, and the M.S. and Ph.D. degrees in control science and engineering from Tsinghua University, Beijing, in 2001 and 2004, respectively. He worked as a Researcher with the Digital Enterprise Research Institute, National University of Ireland, Galway, from 2004 to 2005. From 2005 to 2013, he worked with NEC Laboratories, China, as a Researcher, and the Department of Computer Science, Stanford University, as a Visiting Scholar, from 2009 to 2010. He joined the Beijing University of Technology, Beijing, in 2013, as a Beijing Distinguished Professor. He has over 100+ publications including one book and 40+ journal articles, and holds 58 international patent applications (27 of them have been granted in China, USA, or Japan). His research interests include Petri nets, enterprise information systems, business processes, data mining, information retrieval, semantic Web, privacy protection, and big data. He served as PC members of multiple international conferences and organized the IEEE workshop on medical computing. He served as a Guest Editor to organize a special issue on information technology for enhanced healthcare services in computers in the industry.



YAN PEI (Senior Member, IEEE) was born in Shenyang, China. He received the B.E. and M.E. degrees from Northeastern University, Shenyang, and the Ph.D. degree in engineering from Kyushu University, Fukuoka, Japan. He was a software engineer and the software project manager of Chinese and German IT industries for several years before entering academic society. He is currently working as an Associate Professor with the University of Aizu. His research interests include evolutionary computation, machine learning, and software engineering. He serves as the chair and an organizing committee member for many international conferences sponsored by the IEEE, ACM, and other international associations. He is also serving as editors for many international journals. He received several awards such as the Best Paper Awards from the ICGEC 2012, FC 2018, and FC 2019. He is a Senior Member of the IEEE SMC, IEEE CIS, and the Japanese Society for Evolutionary Computation.



FAHEEM AKHTAR received the B.S. degree in computer science from Hamdard University, Karachi, Pakistan, in 2008, the M.S. degree in computer science from the National University of Computer and Emerging Sciences FAST Karachi, Pakistan, in 2011, and Ph.D. degree from the School of Software Engineering, Beijing University of Technology, Beijing, China. He is associated with the Department of Computer Science, Sukkur IBA University, as an Assistant Professor. His research interests include ubiquitous computing, wireless sensor networks, Internet security, data mining, machine learning, neural networks, and big data.



AZHAR IMRAN received the B.S. degree in software engineering and the M.S. degree in computer science from the University of Sargodha, Pakistan, in 2012 and 2016, respectively. He is currently pursuing the Ph.D. degree with the Beijing University of Technology, Beijing, China. From 2012 to 2017, he worked as a Lecturer with the Department of Computer Science, University of Sargodha. His research interests include machine learning, image processing, medical imaging, and data mining.



KHALIL UR REHMAN received the M.S. degree in software engineering from the SZABIST Islamabad, Pakistan. He is currently pursuing the Ph.D. degree in software engineering with the Beijing University of Technology. His research interests include software engineering, machine learning, deep learning, big data, the SEO, and pattern recognition.

...