

Received March 12, 2020, accepted March 28, 2020, date of publication April 2, 2020, date of current version April 30, 2020.

Digital Object Identifier 10.1109/ACCESS.2020.2985064

Evaluation of Motor Neuron Injury in ALS by Different Parameters of Diffusion Tensor Imaging

YONG SANG¹ AND JINGFENG XU²

¹Department of Physical Education, Qufu Normal University, Rizhao 276826, China

²Office of Academic Affairs, Weifang Vocational College, Weifang 261041, China

Corresponding author: Yong Sang (sang_yong1981@sina.com.cn)

ABSTRACT Amyotrophic lateral sclerosis (ALS) is a neurodegenerative disease involving upper and lower motoneurons selectively. The injury of lower motoneurons is closely related to the onset, progression and prognosis of ALS. Therefore, the assessment of the injury of lower motoneurons is of great significance to ALS. Diffusion tensor imaging (DTI) is a new imaging method improved and developed on the basis of diffusion weighted imaging. It uses the anisotropic principle of diffusion movement of water molecules to quantify it from multiple directions, so as to reflect the changes of fine structure and function of living tissues. It can be more objective to find the damage of the upper motor neurons, help the early diagnosis of ALS, and objectively monitor and evaluate the development and treatment of ALS. In this paper, the research and application of different parameters of diffusion tensor imaging to evaluate the motor neuron injury in ALS were studied. Patients with motor neuron injury in ALS were collected as case group and healthy volunteers as control group. The diagnostic value of different parameters of axial DTI in ALS was discussed. The FA and MD values of the pyramidal tract in ALS patients have obvious changes compared with those in healthy people. It can objectively and quantitatively evaluate the pathological changes of the pyramidal tract in ALS patients, and provide valuable information for the diagnosis of ALS. The FA value is more sensitive, and the posterior limb of the internal capsule may be the best place to evaluate the damage of the pyramidal tract. In a word, DTI can objectively and quantitatively evaluate the lesions of pyramidal tract, provide valuable information for the diagnosis of ALS, and hope to provide help for the establishment, diagnosis, evaluation, prognosis, scientific research and drug test of ALS motor nerve injury.

INDEX TERMS Diffusion tensor imaging (DTI), amyotrophic lateral sclerosis (ALS), motor neuron injury (MN), evaluation parameters.

I. INTRODUCTION

Amyotrophic lateral sclerosis (ALS) is one of the most common motor neuron diseases in adults, which is more common than middle age [1], [2]. It selectively involves upper and lower motor neurons. The cause of ALS involves many factors such as heredity, immunity, nutritional disorders, trace elements, poisoning and so on, but the pathogenesis is not fully clear at present [3]–[5]. The damage of upper motor neuron (UMN) usually starts from the cortex of motor area and premotor area, followed by the degeneration of motor fibers in pyramidal tract and the proliferation of neuroglia [6]–[8]. The damage of lower motor neuron (LMN) mostly involves brain stem and spinal cord anterior horn cells. There are complex interactions between UMN and LMN in ALS. LMN damage is an important pathophysiological process in ALS.

The associate editor coordinating the review of this manuscript and approving it for publication was Wei Wei¹.

LMN damage is closely related to the severity and progress of ALS. The evaluation of LMN damage can help diagnosis, clinical classification, prognosis, and evaluate the efficacy of drug trials, which is of great significance to clinical and scientific research [9]–[12]. It was found that early diagnosis of ALS and prevention of glutamate excitotoxicity damage to neurons by exerting too much force are of great significance for prolonging the survival period of patients in the early and middle stages of the disease. At the same time, due to the poor prognosis of the disease, the average life span after symptoms is about 2-5 years, and other treatable diseases need to be excluded, so it is urgent to make a diagnosis in the early stage of the disease [13]–[15]. At present, the pathological changes of lower motor neurons can be judged by objective indexes such as electromyography, nerve and muscle biopsy, while the pathological changes of upper motor neurons depend on clinical examination, but the signs of upper motor neurons found in clinical examination are more

scattered, or accompanied by serious damage of lower motor neurons [16]–[18]. The subjective influence of the examinee is great, and it is often difficult to determine whether there is upper motor neuron involvement. Therefore, in the current clinical practice, it is urgent to objectively evaluate the sensitive technology of upper motor neuron damage in this disease.

Diffusion tensor imaging (DTI) is a new imaging method based on diffusion weighted imaging (DWI), which is mainly used to observe the movement of water molecules in tissues. Under the physiological condition of human body, the diffusion movement of water molecules in all directions of three-dimensional space is not only affected by the characteristics of cell itself, but also by various barriers such as axon myelin, the interaction between water molecules and protein macromolecules, and the state of basement membrane [19], [20]. As a result, the diffusion coefficient of water molecules in some directions is easier than that in other directions. For example, in myelinated nerve fibers, the diffusion coefficient of water molecules in the direction parallel to the fiber bundle is usually greater than that perpendicular to the fiber bundle. This kind of diffusion with strong direction dependence is called diffusion anisotropy, which is the key of DTI imaging. The size and direction of water diffusion, the biochemical characteristics of tissues and the structure of tissues can fundamentally affect the diffusion ability of water. Therefore, DTI can evaluate the pathophysiological changes of the central nervous system, and it is a real quantitative method to display the microscopic physical characteristics of tissues [21]–[23].

In the brain of ALS patients, there may be some changes in microenvironment, such as cell structure instability, membrane destruction caused by demyelination and Wallerian degeneration of axon, extracellular space enlargement caused by reactive proliferation of glial cells, changes in ionic environment, blood flow block secondary to changes in cell structure and function, and axonal flow decline. All of these can reduce the ability of brain tissue to limit the diffusion of water molecules, increase the diffusion ability of water molecules and change the diffusion anisotropy, which can be directly displayed in. In recent years, some related researches have been carried out on the role of DTI in the discovery of the damage of upper motor neurons in ALS, but these researches mostly analyze the DTI parameters in isolation. The overall experimental flow is shown in Figure 1. Transcranial magnetic stimulation (TMS) motor evoked potential (MEP), which can evaluate the function of central and peripheral motor pathways, may be helpful to find the dysfunction of upper motor neurons in ALS, and combine it with DTI for research. In this study, we will combine it to explore the significance of evaluating the injury of motor neurons in ALS prospectively.

II. EVALUATION OF MOTOR NEURON DAMAGE IN ALS BY DIFFUSION TENSOR IMAGING

Electromyography can sensitively detect the damage of lower motor neurons in ALS patients. However, up to now, there is

no accepted objective index to evaluate the damage of motor neurons, or pyramidal tract, on ALS. With the development of neuroimaging technology, more and more attention has been paid to the role of diffusion tensor imaging (DTI) in the evaluation of pyramidal tract injury in ALS patients. The purpose of this study is to explore the value of DTI in the diagnosis of ALS.

A. ORIGIN AND TRANSMISSION OF AMYOTROPHIC LATERAL SCLEROSIS (ALS)

1) PATHOLOGY OF ALS

The main pathological changes of ALS were degeneration of spinal cord anterior horn cells, brain stem motor nucleus cells, motor cortex cells and pyramidal tract. In addition, parts outside the motor system are also affected to varying degrees. Microscopically, the pyramidal cells in the fifth layer of the motor cortex decreased, accompanied by active gliosis, and the remaining Betz cells shrank and dendritic degeneration. Degeneration of pyramidal tract leads to pallor of myelin sheath, especially in the posterior limb of internal capsule [24], [25]. The prevalence of ALS was global, and the prevalence rate was 4-6 / 100 thousand. The annual incidence rate was 0.4 - 1.76 million, and the mortality rate was 2/100 thousand. In China, most of ALS are sporadic, only 5% - 10% of ALS are familial. There is no difference between them in clinical manifestations. There are many theories about the etiology and mechanism of ALS, but they are not completely clear. There are genetic mechanism, excitatory amino acid toxicity mechanism, mitochondrial dysfunction mechanism, signal pathway neurotrophic factor defect mechanism, virus infection, environmental factors and so on [26]–[28]. As a result, motor neuron necrosis secondary axon and myelin destruction, glial cell proliferation and denervated muscular atrophy.

Whether ALS originated from upper motor neuron or lower motor neuron is still controversial. In the neuron neuron hypothesis, there has been a debate about the two ways of progression: the paraaxonal damage and the reverse axonal damage. The former holds that ALS first appears the involvement of the upper motor neurons, which propagates along the axons of the pyramidal cells of the cortex to the anterior horn cells of the spinal cord. The latter thought that ALS had lower motor neuron dysfunction in the early stage. This functional change may start from the distal end of peripheral nerve (presynaptic nerve endings, neuromuscular joints or distal axons), and gradually progress to the proximal end [29], [30]. The longest and largest motor axons were first affected. Later, more axons were involved in the proximal part, which may be related to the distal metabolic changes of motor nerve and the decrease of axoplasmic transport. The hypothesis of reverse axon damage can well explain why the distal part of ALS patients, such as hand or foot muscles, is often involved first, but it can not explain the onset of bulbar disease or the early involvement of paravertebral muscles innervated by the same segment of distal muscles [31], [32]. Another cell-cell hypothesis holds that ALS originates from the upper and

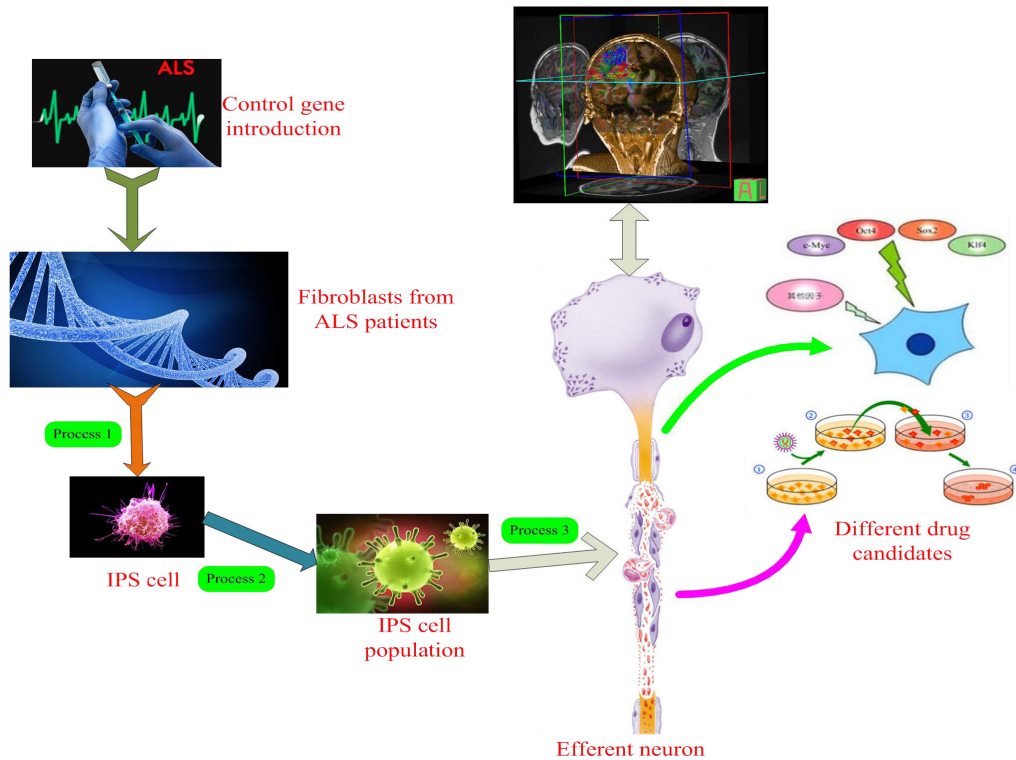


FIGURE 2. ALS motor neurologist.

used in clinic. Although the application of electromyography is of great value in the diagnosis of ALS, the early misdiagnosis rate of ALS is still very high in clinic, which is mainly due to the lack of objective means to evaluate UMN damage; the main method to evaluate UMN damage is the physical examination of nervous system, especially in the early stage of the disease or when LMN damage is the main sign [39], [40]. Therefore, it is necessary to find an objective and quantitative method to evaluate UMN damage.

Many imaging techniques have been used for ALS evaluation, such as conventional MR imaging, magnetization transfer technology, MR spectroscopy, single photon emission computed tomography, positron emission computed tomography, etc. The conventional MR manifestations of ALS include: low signal band along the gyrus of the anterior central gyrus, which is believed to be related to iron deposition; high signal on T2WI due to pyramidal tract degeneration; atrophy of the anterior central gyrus and expansion of the central sulcus due to the decrease of cortical motoneurons [41]. It is worth noting that the high signal of the posterior limb of the internal capsule can also appear in the normal people, and only when it is higher than the cortical signal can it have diagnostic value. Some scholars recommend that patients with suspected ALS should be routinely scanned with proton density weighted imaging sequence. If high signal is found in the posterior limb of the internal capsule, it can reliably indicate pyramidal tract degeneration. On MR T2 and FLAIR images, it is sometimes found that the more extensive areas of the pyramidal tract (including the subcortical white matter

of the anterior central gyrus) show high signal intensity [42], [43]. Prospective studies have shown that flair is more likely to show high signal in the area of pyramidal tract outside the posterior limb of the internal capsule than other sequences, but in some normal people, flair also shows high signal in the area of pyramidal tract, so the interpretation of the results should be carefully combined with clinical judgment. This group of data shows that the course of disease in patients with T2WI high signal is relatively short (average 8.5 months). Whether there is an internal relationship between the universality of the abnormal signal range and the course of disease remains to be further studied.

Although there are many reports about Mr application in ALS, the expression in El Escorial diagnostic standard is “there is no neuroimaging test that can determine the diagnosis of ALS”, that is to say, neuroimaging test is only used to exclude the possibility of other diagnosis. However, the research of imaging, especially the development of MR-DTI, provides a new way to evaluate the function of pyramidal tract in ALS patients.

B. CORRELATION BETWEEN DIFFUSION TENSOR IMAGING (DTI) AND CLINICAL INDEXES

1) APPLICATION VALUE OF DTI IN ALS

DTI is a new technology developed on the basis of diffusion weighted imaging, as shown in Figure 3. It provides an objective quantitative method to show the strength and direction of water dispersion in three-dimensional space. Diffusion

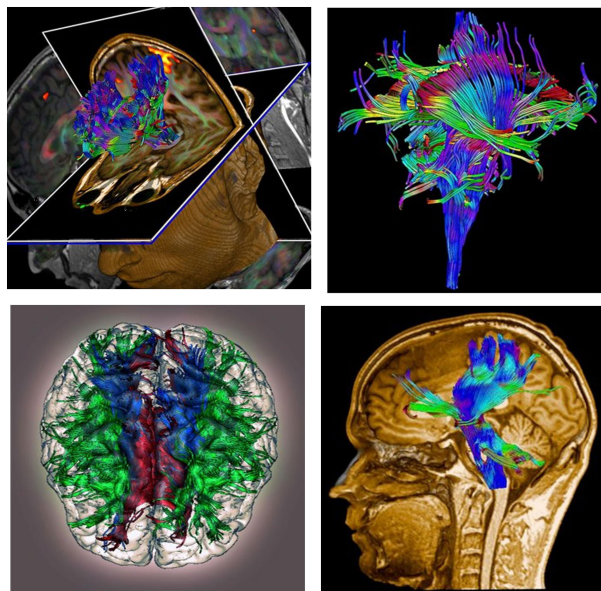


FIGURE 3. DTI schematic diagram.

tensor imaging (DTI) is a new technology improved and developed by using diffusion weighted imaging technology. DTI is not a plane process. It decomposes the signal data of dispersion anisotropy in three-dimensional perspective, so as to make the microstructure display more precisely. Diffusion needs to be displayed by tensor, and scanning uses multiple gradient field directions, now it uses 6-55 directions. Under the physiological condition of human body, due to the influence of cell characteristics and various barriers such as axonal myelin sheath, the diffusion of water molecules in some directions is easier than that in other directions [44]–[46]. This kind of diffusion with strong direction dependence is called diffusion anisotropy, which is the key of DTI imaging. DTI is a non-invasive imaging method, which uses the diffusion movement of water molecules and applies diffusion sensitive gradient pulse to reflect the diffusion changes of water molecules in three-dimensional and multi-directional space. FA is the most commonly used parameter for quantitative analysis of anisotropy. Its range is 0-1. 0 represents the maximum isotropic diffusion (such as cerebrospinal fluid), and 1 represents the maximum anisotropic diffusion. ADC is used to reflect the diffusion speed and range of water molecules. When the axons or (and) myelin sheath of the white matter tract are involved in various lesions, the FA value of the involved area will be reduced to some extent, while the ADC value will be increased to some extent [47], [48].

In the data of this group, at the level of the posterior limb of the internal capsule, the FA value of ALS group was significantly lower than that of the control group; the ADC value was significantly higher than that of the control group, but there was no significant decrease in FA value. The posterior 3 / 4 of the posterior limb of the internal capsule is

the place where the fibers are dense under the pyramidal tract. In the normal human body, the water molecules have high anisotropy. It has been confirmed from the micro level that the integrity of axon cell membrane is the most important factor affecting the diffusion anisotropy in nerve tissue; secondly, the integrity of myelin sheath is also one of the factors affecting the anisotropy. The decrease of FA value in the posterior limb of the internal capsule reflects the destruction of the barrier restricting the free movement of water molecules in this area, which is consistent with the “axonal degeneration and pallor of myelin sheath” observed by pathology. The increase of ADC value can only be observed after the destruction of cell membrane integrity and the enlargement of extracellular space, which can be explained by the pathological changes of UMN. The degeneration and deletion of axons lead to the expansion of extracellular space, thus increasing the diffusivity, while the accompanying glial proliferation will reduce the diffusivity; the axonal degeneration leads to the expansion of extracellular space filled by proliferating glial, maintaining the cell density of ALS pyramidal tract, which may be the reason that there is no significant change in ADC value of ALS group. Therefore, FA value is a sensitive index to evaluate the lesions of pyramidal tract.

The main pathological changes of ALS were degeneration of spinal cord anterior horn cells, brain stem motor nucleus cells, motor cortex cells and pyramidal tract.

There were no significant changes in FA and ADC values in the subcortical white matter of the anterior central gyrus, the center of the semicircular circle and the periventricular white matter in ALS group, but p values were smaller than those in the non pyramidal tract. Among them, in the subcortical white matter of anterior central gyrus, the FA value of ALS group decreased; in the subcortical white matter of anterior central gyrus and periventricular white matter, the ADC value increased. Although pathological studies show that the white matter fibers of pyramidal tract above the level of the posterior limb of the internal capsule are relatively not easy to be involved, the pathological changes after the involvement are the same (axonal degeneration, demyelination, glial hyperplasia) [49], [50]. However, because the white matter in subcortical area is not closely arranged with the posterior limb of the internal capsule, and the anisotropy of the former is not as high as the posterior limb of the internal capsule, the FA and ADC values caused by UMN damage are not significantly different from those of the posterior limb of the internal capsule.

2) DIFFUSION TENSOR IMAGING PARAMETERS

There are two kinds of quantization parameters in DTI. The first type is the average dispersion rate, which refers to the average dispersion intensity in all directions of a single element, independent of the dispersion direction [51], [52]. The commonly used parameter is the average diffusion coefficient (ADC), which represents the diffusion range of water molecules in unit time. It reflects the diffusion capacity of water molecules W . the larger the ADC value is, the stronger

the diffusion energy of water molecules is. The second is the anisotropy index, which reflects the direction of water dispersion. There are many parameters for quantitative analysis of anisotropy, such as anisotropic fraction (FA), relative anisotropy (RA), volume ratio index (VR), etc., FA is the most commonly used. FA refers to the proportion of anisotropic components of water molecules in a single element to the total dispersion tensor. The value is between 0 and 1. 0 represents the maximum isotropic dispersion (such as pure water), and 1 represents the maximum anisotropic dispersion under the assumption. The larger the FA, the stronger the anisotropic dispersion of water molecules, indicating that the degree of myelination is high, the fiber consistency is high, the number of axons is large and the arrangement is close; the lower the FA, the stronger the isotropic dispersion of water molecules, reflecting axonal and / or myelin development disorders, axonal fibrosis and myelin decomposition. By measuring the DTI parameters above, we can evaluate the white matter fiber bundle quantitatively and judge the extent and scope of white matter fiber bundle damage caused by various diseases [53].

As a new MRI method, DTI has been used in the study of brain tumors, congenital brain development, and leukoencephalopathy. At present, the research of DTI mainly adopts the method of setting ROI (region of interest). What is DTI? It refers to selecting a region from the image, and sending a region is the focus of image analysis. When ROI is set in FA image and ADC image respectively, FA value and ADC value corresponding to the target area can be displayed. In the DTI study of ALS, the setting of ROI is mainly concentrated in the cone bundle walking area. The researchers believe that the change of DTI image in patients with chemical s is the result of the individual difference of the anatomical structure of the fiber bundle and / or the pathological change of ALS. The decrease of FA value and the increase of ADC value indicate the absence of structural disorder restricting the movement of water molecules, which is related to the degeneration of neurons and the loss of myelin sheath.

In recent years, with the in-depth study of ALS, it has been recognized that HS is a kind of multiple system degenerative disease mainly affected by motor system. Researchers have extended the research site of DTI to extrapyramidal tract. Some studies have shown that the FA value of other white matter fiber bundles, such as pride vein body and Hao Chen, is also reduced to some extent in the myelin sheath. In the diagnosis of ALS, DTI is not specific. Any disease that affects axon, myelin sheath, neuroglia and other structural changes in brain tissue can lead to the decrease of FA value and the increase of ADC value. At present, DTI technology is not mature, and no uniform parameter value has been formed to determine whether the UN m is damaged. In different ALS patients, although the age, course, ALSFRS, disease progression speed and diagnosis certainty are different, ADC changes are not obvious, so ADC values and the above indicators do not show significant correlation. ALSFRS is an international standard to evaluate the severity of ALS patients.

The lower the score is, the more serious the impairment of motor neuron function is. FA value is the most commonly used parameter for quantitative analysis of anisotropy. The degeneration of axon changes the anisotropic diffusion of water molecules along the direction parallel to the nerve fiber dimension, and FA value decreases. Although axonal degeneration is accompanied by glial hyperplasia, this pathological change can not repair axonal damage, that is, anisotropic diffusion can not return to the pre pathological state, FA value is still reduced, and ADC value may not change significantly at this time. Therefore, it can be concluded that FA value is a sensitive quantitative index to evaluate ALS patients in vivo.

III. DATA AND METHODS

A. RESEARCH OBJECT

From August 2014 to December 2019, 14 patients (case group) with ALS diagnosed in our hospital were collected, 6 males and 8 females, aged 40-70 years, with a median age of 59.5 years. The course of disease was 5-24 months, the median course was 12 months; 8 cases were from limb weakness, 6 cases were from drinking water and choking cough, dysphagia; 12 cases showed obvious muscle atrophy. All patients met the diagnostic criteria of El Escorial. Another 11 normal adults were selected as the control group, 5 males and 6 females, aged 48-72 years, with a median age of 54 years, which matched the age and gender of the case group ($P > 0.05$). There was no history of taking drugs affecting the nervous system in the near future. The patients with weak strength, amyotrophy, fascicular tremor or bulbar palsy, hyperreflexive clonus and positive pathological reflexes were found in clinical manifestations. There was no previous history of sensory motor polyneuropathy, median neuropathy, abnormal albuminemia, malignant tumor, carpal tunnel syndrome, autoimmune disease, hyperthyroidism, diabetes, hypertension, cerebrovascular disease, and no electromyography of active drugs in contact with nervous system showed motor neuron damage in medulla oblongata, neck, chest and ilium segments in different regions. There was no abnormal CSF in some patients without block. All subjects were examined by DTI sequence.

B. INSTRUMENTS AND METHODS

The patients who were included in the trial according to the above criteria were scored for clinical function. After informed consent, all the subjects underwent brain scan, transcranial magnetic stimulation, motor evoked potential, examination and evaluation of the relevant parameters. The diagnosticians were not aware of the clinical conditions of the subjects.

1) Clinical function score: ① ALS function score, 40 points in total, the lower the score, the more serious the neurological impairment; ② disease progression rate: calculated according to formula $(40 - \text{ALS function score}) / \text{course of disease}$; ③ pyramidal tract score: according to the range of pyramidal tract in

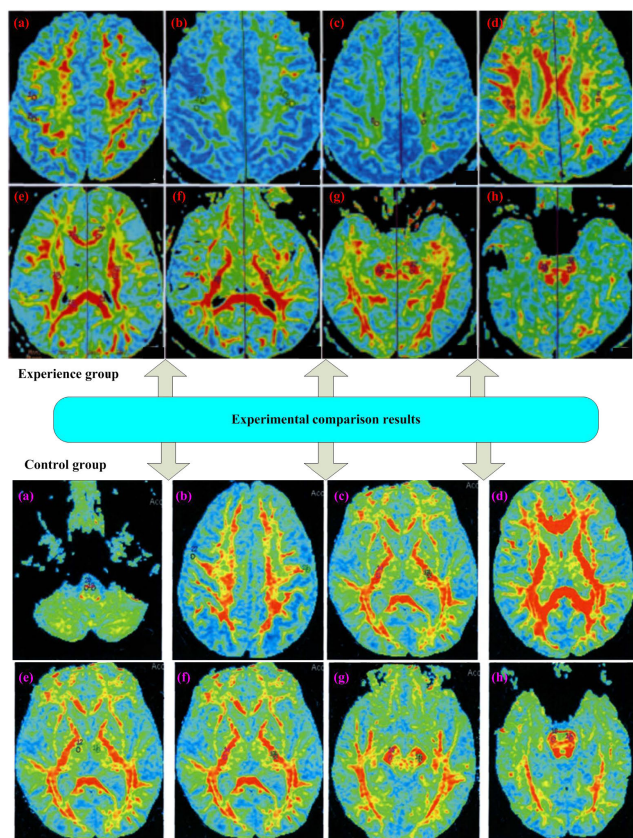


FIGURE 4. Diffusion tensor imaging of axial scan of patients' head. (a: Subcortical white matter of anterior central gyrus, b: semicircular center, c: periventricular white matter, d: knee and pressure of corpus callosum, e: thalamus, f: posterior limb of internal capsule, g: cerebral foot, h: pons).

medulla oblongata and limbs, 1 point will be scored for each part or multiple parts, 5 points in total.

2) DTI and evaluation method: GE1.5T double gradient superconducting MRI system was used. Conventional MRI includes transverse flair t1 w1, DW-EPI, 13 diffusion sensitive gradient directions, 2nex and scanning time of 3 minutes and 50 seconds. The above inspection adopts the same layer with thickness of 6mm and interval of 1.6mm.

The DTI images were analyzed and processed with functool 2.0 software of AW4.0 workstation, and the average diffusion coefficient and partial anisotropy graphs were constructed. 8 regions of interest (ROI) with an area of 20-30mm² were selected to measure the FA and MD (mean diffusivity) values of bilateral ROI. The DTI image processing results of the experimental group and the control group are shown in Figure 4 respectively.

C. IMAGE PROCESSING AND DATA ANALYSIS

After collecting the original data, it is transmitted to aw4.2 workstation for post-processing. Using functool image processing software, EPI correction was carried out first to determine the reconstruction range, and then the fractional anisotropy (FA), relative anisotropy (RA) and anisotropy index (AI) parameter maps were constructed and measured

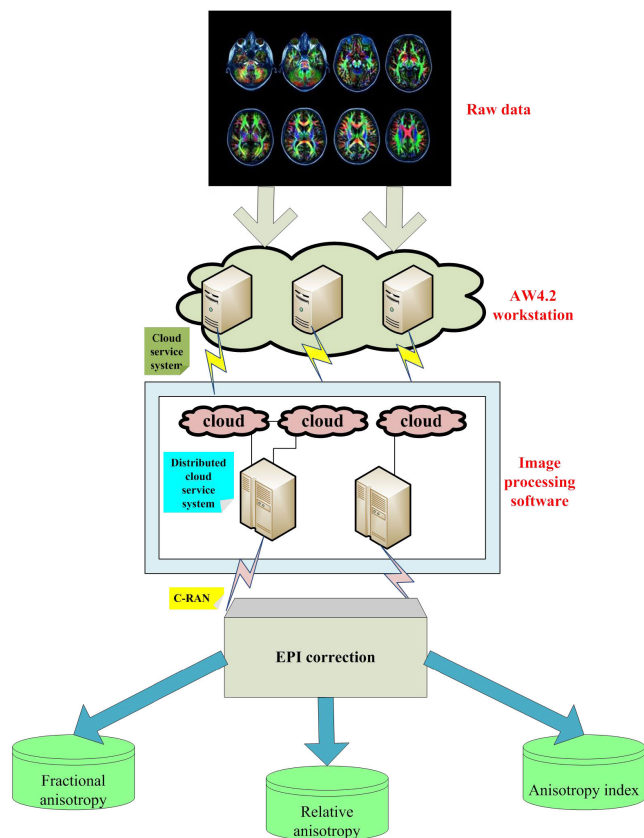


FIGURE 5. Image processing and data analysis.

by computer automatically, as shown in Figure 5. For the case group and the control group, refer to the DTI color coding map, and set ROI respectively in bilateral anterior central gyrus cortex, posterior central gyrus cortex, anterior central gyrus cortex white matter, posterior central central cortex white matter, semicircular center, radial crown, lateral ventricular white matter, knee of corpus callosum, pressure of corpus callosum, posterior limb of internal capsule, foot of midbrain, pons and medulla oblongata cone. The area is 20-25mm². Measure the FA value, Ra value and AI value of 26 ROI. Measure each parameter three times, and take the average value.

D. STATISTICAL ANALYSIS

Using SPSS18.0 statistical software, the measurement data are expressed in $x \pm s$ test was used for the comparison of count data. If there is no significant difference in FA value, Ra value and AI value between the left and right sides of ROI in the same group, the left and right side data will be combined and then statistical analysis will be performed. The data of each group were tested for normality and homogeneity of variance, and the data accorded with normality; when the data variance was homogeneous, two independent sample t-tests were used to compare the two groups, and when the variance was uneven, t' tests were used. P < 0.05 was statistically significant.

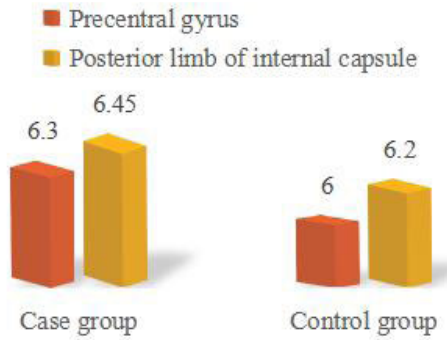


FIGURE 6. Comparison of MD values between case group and control group.

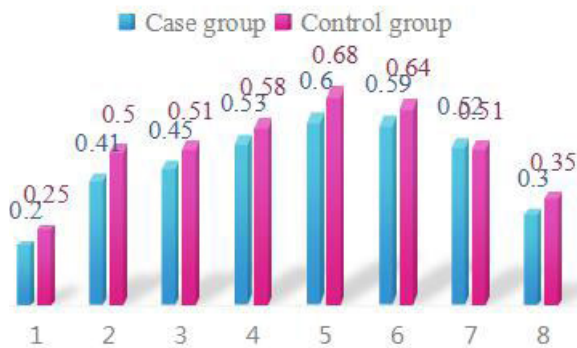


FIGURE 7. Comparison of FA values of each ROI in the walking area of the vertebral tract between the case group and the control group. (1: Anterior central gyrus cortex, 2: subcortical white matter of anterior central gyrus, 3: semioval center, 4: periventricular white matter, 5: posterior limb of internal capsule, 6: cerebral foot, 7: thalamus).

IV. EXPERIMENTAL RESULTS AND DISCUSSION

A. ANALYSIS OF EXPERIMENTAL RESULTS

Diffusion tensor refers to the anisotropic diffusion of water molecules, or the diffusion characteristics of inhomogeneous tissues. In DTI imaging, the key factor determining diffusion tensor is to apply diffusion gradient in at least six non collinear directions, and obtain a diffusion weighted image in each gradient direction, so as to obtain a group of diffusion weighted images. FA is the most commonly used parameter for quantitative analysis of anisotropy, which represents the anisotropy of tissue fibers and the ratio of diffusion anisotropy to the whole diffusion. The range of FA is 0-1, 0 represents the diffusion of the maximum isotropic percussion, and 1 represents the diffusion of the maximum anisotropy. MD is used to reflect the range of free diffusion of water molecules in a unit time, and to evaluate the limited degree of water molecules movement. The increase of MD means the limited degree is small, and the decrease of MD means the limited degree is large. When the axons and myelin sheath of the white matter tract are involved in various lesions, the (fractional anisotropy) FA value of the involved area will be reduced to some extent, while the MD value will be increased to some extent, as shown in Figure 6 and Figure 7.

Compared with the control group, FA value of subcortical white matter of anterior central gyrus in group A and B decreased, MD value increased, FA value of cortex of anterior

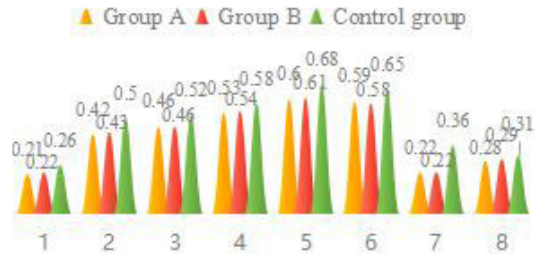


FIGURE 8. FA and MD values of each region of interest in groups a, B and control. (1: Anterior central gyrus cortex, 2: subcortical white matter of anterior central gyrus, 3: semioval center, 4: periventricular white matter, 5: posterior limb of internal capsule, 6: cerebral foot, 7: thalamus).

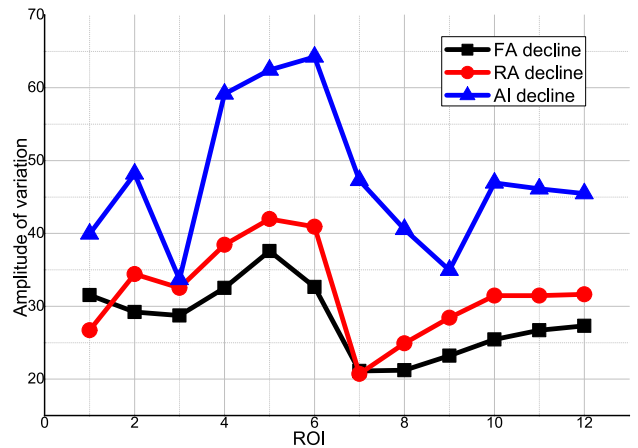


FIGURE 9. Comparison of the change range of different parameters between case group and control group.

central gyrus, semicircular center, white matter around lateral ventricle, posterior limb of internal capsule, cerebral foot, medulla oblongata and thalamus decreased, and the change trend is shown in Table 1 and Figure 8.

1) COMPARISON OF FA, RA AND AI VALUES OF ROI BETWEEN TWO GROUPS

Compared with the control group, the FA, RA and AI values of all ROI in the case group were decreased (P < 0.01), and the FA values of the central posterior cortex were decreased, as shown in Table 2.

2) COMPARISON OF THE CHANGE RANGE OF DIFFERENT INDICATORS IN EACH ROI

Select the indicators with differences between the ROI of the case group and the control group, and compare the differences between the mean value of the case group and the mean value of the control group, as shown in Table 3 and Figure 9. In the case group, the value of ROI and FA decreased by more than 30% in 4 cases, by more than 30% in 8 cases, and by more than 30% in 12 cases. The change range of each index in the crown was more obvious.

3) SENSITIVITY COMPARISON OF INDICATORS WITH DIFFERENCES IN EACH ROI

When the FA, RA and AI values of the case group are lower than the lower limit of 95% confidence interval of the

TABLE 1. FA and MD values of each region of interest in groups a, B and control.

	Group A	Group B	Control group	P value
FA value				
Cortex of anterior central gyrus	0.23±0.02	0.24±0.01	0.28±0.02	0.001
Subcortical white matter of anterior central gyrus	0.44±0.06	0.45±0.03	0.52±0.03	0.001
Semioval Center	0.48±0.03	0.48±0.05	0.54±0.02	0.010
Periventricular white matter	0.55±0.02	0.56±0.04	0.6±0.02	0.011
Posterior limb of internal capsule	0.62±0.03	0.63±0.02	0.7±0.02	0.012
Cerebral peduncle	0.6±0.02	0.61±0.01	0.66±0.03	0.012
Pons	0.55±0.08	0.57±0.06	0.55±0.06	0.734
Medulla oblongata	0.23±0.05	0.24±0.03	0.36±0.03	0.012
Knee of corpus callosum	0.59±0.03	0.72±0.07	0.72±0.05	0.579
Pressure of corpus callosum	0.74±0.08	0.74±0.12	0.8±0.03	0.162
Thalamus	0.29±0.03	0.3±0.02	0.33±0.01	0.014
MD value				
Cortex of anterior central gyrus	8.15±0.36	8.26±1.25	7.63±0.61	0.183
Subcortical white matter of anterior central gyrus	6.37±0.53	6.41±0.34	6.15±0.27	0.052
Semioval Center	6.65±0.42	6.56±0.45	0.73±0.59	0.878
Periventricular white matter	6.36±0.13	6.55±0.56	6.58±0.46	0.312
Posterior limb of internal capsule	6.53±0.43	6.66±0.44	6.34±0.27	0.088
Cerebral peduncle	7.28±0.55	7.31±0.78	7.36±0.79	0.969
Pons	6.55±0.31	6.51±0.75	7.01±0.97	0.113
Medulla oblongata	7.41±0.75	7.63±0.52	7.72±0.89	0.892
Knee of corpus callosum	0.23±0.02	0.23±0.02	0.23±0.02	0.256
Pressure of corpus callosum	0.23±0.02	0.23±0.02	0.23±0.02	0.182
Thalamus	0.23±0.02	0.23±0.02	0.23±0.02	0.989

control group, they are regarded as abnormal values, and the sensitivity of each index is compared, as shown in Table 4 and Figure 10. The sensitivity of FA and RA was more than 80%

TABLE 2. Comparison of DTI parameters of different ROI between case group and control group.

ROI	FA value		RA value		AI value	
	t	P	t	P	t	P
1	-6.12	<0.02	-5.39	<0.02	-6.22	<0.02
2	-2.04	<0.02	-2.76	<0.02	-2.24	<0.02
3	-	<0.02	-6.29	<0.02	-7.97	<0.02
4	-6.34	<0.02	-8.82	<0.02	-3.92	<0.02
5	-9.96	<0.02	-	<0.02	-9.38	<0.02
6	-	<0.02	-	<0.02	-8.32	<0.02
7	-	<0.02	-7.16	<0.02	-	<0.02
8	-8.92	<0.02	-5.38	<0.02	-8.16	<0.02
9	-5.33	<0.02	-7.35	<0.02	-6.98	<0.02
10	-7.79	<0.02	-8.28	<0.02	-4.93	<0.02
11	-7.98	<0.02	-7.89	<0.02	-6.92	<0.02
12	-5.39	<0.02	-5.49	<0.02	-4.96	<0.02

TABLE 3. Comparison of the change range of different parameters between case group and control group (%).

ROI	FA decline	RA decline	AI decline
1	31.53	26.72	39.94
2	29.21	34.41	48.18
3	28.74	32.52	33.69
4	32.52	38.44	59.16
5	37.57	41.98	62.45
6	32.65	40.91	64.24
7	21.12	20.72	47.28
8	21.23	24.92	40.57
9	23.21	28.42	34.96
10	25.45	31.46	46.95
11	26.72	31.47	46.12
12	27.31	31.63	45.47

in 10 ROIs, more than 80% in 8 ROIs, and 100% in the center of semioval, the corona radiata, and the parawhite matter of lateral ventricle.

4) COMPARISON OF THE DIFFERENCES OF INDICATORS IN EACH ROI

The specificity of each index ranged from 55.00% to 76.19%, as shown in Table 5 and Figure 11. Among them,

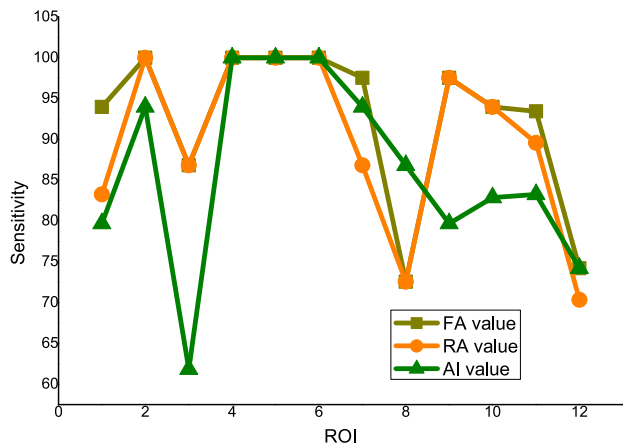


FIGURE 10. Sensitivity comparison of different ROI and different indexes.

TABLE 4. Sensitivity comparison of different ROI and different indexes (%).

ROI	FA value	RA value	AI value
1	93.97	83.25	79.68
2	100	100	93.97
3	86.82	86.82	61.83
4	100	100	100
5	100	100	100
6	100	100	100
7	97.54	86.82	93.97
8	72.54	72.54	86.82
9	97.54	97.54	79.68
10	93.97	93.97	82.86
11	93.42	89.57	83.25
12	74.19	70.34	74.19

the specificity of each index was more than 60% in the cortex of anterior central gyrus, cortex of posterior central gyrus, posterior limb of internal capsule, pons and medullary pyramids.

B. DISCUSSION

In the process of diagnosis of ALS, neuroimaging is mainly used to exclude the diagnosis of ALS. However, the abnormalities of ALS patients on MRI may also reflect the pathological changes of upper motor neurons. There are many kinds of DTI parameters, in which FA value is the ratio of anisotropic part to the whole diffusion, reflecting the integrity of microstructure. Ra value is the ratio of anisotropic part to isotropic part, which is linearly related to the anisotropy of water molecules; AI value = 1-volume ratio, which reflects the diffusion speed of water molecules in different directions, and decreases with the decrease of anisotropy. Different

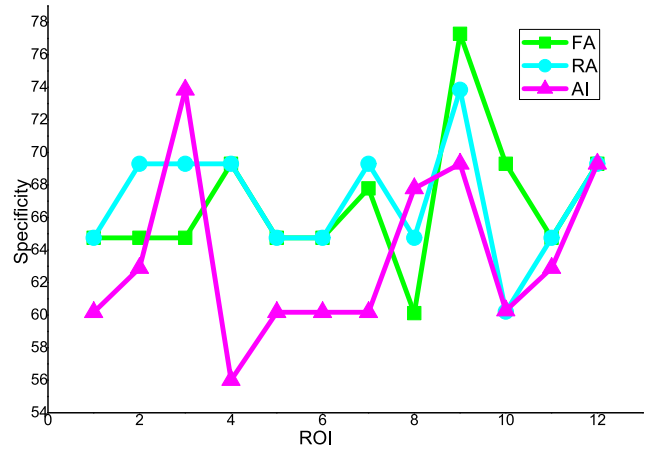


FIGURE 11. Comparison of the specificity of different ROI and different indexes.

TABLE 5. Comparison of the specificity of different ROI and different indexes (%).

ROI	FA	RA	AI
1	64.75	64.75	60.18
2	64.75	69.29	62.89
3	64.75	69.29	73.84
4	69.29	69.29	56.01
5	64.75	64.75	60.18
6	64.75	64.75	60.18
7	67.78	69.29	60.18
8	60.12	64.75	67.78
9	77.28	73.84	69.29
10	69.29	60.21	60.28
11	64.75	64.75	62.89
12	69.29	69.29	69.29

parameters have different sensitivity and specificity for different disease diagnosis, but the optimal parameter selection for each scanning process has not yet reached a unified understanding. DTI is one of the valuable methods to evaluate the lesions of pyramidal tract in vitro and noninvasively. Our study shows that the changes of FA and DAC in the posterior limb of the internal capsule in ALS patients are significant and stable, the former is more sensitive; these information are of great significance for the diagnosis of a ratio and the further understanding of the disease. However, as a new method, DTI still needs deep research to obtain evidence-based medicine. There are abundant case resources in China. Compared with foreign countries, it is more convenient to carry out large-scale research in the future.

DTI is a new technology developed on the basis of DWI, which provides an objective quantitative method to show the

strength and direction of water diffusion in three-dimensional space. Under the physiological condition of human body, the diffusion movement of water molecules in all directions of three-dimensional space is not only affected by the characteristics of cell itself, but also by various barriers such as axon myelin, the interaction between water molecules and protein macromolecules, and the state of basement membrane. As a result, the diffusion of water molecules in some directions is easier than that in other directions. For example, the diffusion limit of water molecules in the direction of myelinated nerve fibers perpendicular to axons is greater than that along axons. This kind of diffusion with strong direction dependence is called diffusion anisotropy, which is the key of DTI imaging. Diffusion tensor refers to the anisotropic diffusion of water molecules, or the diffusion characteristics of inhomogeneous tissues. In DTI imaging, the key factor determining diffusion tensor is to apply diffusion gradient in at least six non collinear directions, and obtain a diffusion weighted image in each gradient direction, so as to obtain a group of diffusion weighted images.

ALS is a progressive neurodegenerative disease that selectively involves the upper and lower motor neurons in the brain and spinal cord. The pathological changes of the upper motor neurons are mainly manifested in the disappearance of the cells in the motor cortex and the large pyramidal cells, the degeneration and demyelination of the pyramidal tract. The following microscopic changes may exist in the brain tissue of ALS patients:

- 1) Unstable cell structure;
- 2) The loss of myelin sheath and Wallerian degeneration of axon lead to the destruction of cell membrane;
- 3) The reactive proliferation of glial cells results in the increase of extracellular space;
- 4) The ion environment has changed;
- 5) Secondary to changes in cell structure and function, blood flow block and axonal flow decline.

All of these changes in microstructure can reduce the ability of brain tissue to limit the diffusion of water molecules, increase the diffusion ability of water molecules and change the diffusion anisotropy. Therefore, we choose FA and MD to evaluate the damage of motor neurons on ALS.

In this study, 13 ROIs were set in the bilateral motor area and non motor area of ALS patients and normal people. There was no significant difference in the parameters of each ROI in the case group between the left and right sides, which may be related to the bilateral limb involvement of patients with limb symptoms. In the case group, the parameters of the knee part of the corpus callosum, the pressure part and the white matter area under the cortex of the central posterior gyrus were lower than those of the control group, and the FA value of the cortex of the central posterior gyrus was lower than that of the control group. In this study, we found that the changes of FA, RA and AI values in the brain of ALS patients were similar, which confirmed that there were lesions in corticospinal tract and non motor area of ALS patients. The decrease of FA value

is related to the demyelination of fiber bundle, the decrease of anisotropy of water diffusion caused by the rupture, dissolution and disappearance of axon, which is consistent with the research results of thivard *et al.* There was no obvious sensory disturbance in this group, but the fibers in sensory area and non corticospinal tract were also damaged. Some studies have shown that the FA values of white matter and corpus callosum in the subcortical posterior gyrus of ALS patients are significantly reduced, which is consistent with the degeneration of pyramidal tract through the corpus callosum confirmed by pathological studies, suggesting that ALS is not only a damage to the motor system, but a more extensive systemic disease. Nelles *et al* found that the FA values of the central anterior gyrus, semioval center and the posterior limb of the internal capsule in ALS patients were lower than that in healthy people, while the positive rate in this study was significantly higher, which may be related to the smaller ROI area and the reduction of part volume effect in this study.

In this study, the parameters of the case group were reduced by more than 30% compared with the control group in 4, 8 and 12 places respectively. The diffusion anisotropy was mainly affected by the integrity of myelin sheath and nerve membrane of axons. The three parameters of diffusion anisotropy of water molecules included in this study were significantly lower than those in the control group, indicating that the integrity and consistency of myelin sheath and axons in ALS patients were damaged, which confirmed that the white matter fibers in ALS patients had different degrees of demyelination and axonal degeneration. The change of AI value is more extensive than that of FA and RA, which is related to the lower order of AI value and the relatively obvious change of AI value. In this study, the parameters at the center of corona and semioval of ALS patients changed the most, that is, the white matter fiber damage was the most serious, which could be used as the first choice of ROI in DTI scanning of ALS patients; RA and AI values changed more obviously, which was the first choice of parameters. In addition, the injury degree of nerve fibers in ALS patients is more serious near motor cortex than brain stem, which supports the view that nerve fibers secondary walleri an degeneration after motor cortex neuron degeneration and necrosis.

In this study, the sensitivity of FA and RA was more than 80% and that of AI was more than 80%. The sensitivity of semioval center, corona radiata, and paraventricular white matter were all 100%, suggesting that they could be the first choice. The SNR of AI map is significantly lower than that of FA and RA map, and the measurement error is more likely to occur. Influenced by b value, it is not suitable to compare among individuals, and it is not as stable as FA value and RA value.

Under the premise of setting parameter threshold, the specificity of each index in this study is 55.00% - 76.19%. Among them, the specificity of each index in subcortical white matter of anterior central gyrus, subcortical white matter of posterior central gyrus, posterior limb of internal capsule, pons and pyramidal medulla oblongata is more than

60%. The demyelination and axonal degeneration of nerve fibers caused by various causes can cause the changes of DTI parameters, so its specificity is not as high as sensitivity. This study did not include patients with other diseases, but only ALS patients compared with healthy people, the specificity of the posterior limb of the internal capsule, pons and medulla oblongata cone is relatively higher than other ROI, which is the preferred level.

We found that compared with the control group, the value of white matter and posterior limb of internal capsule in the case group increased. The results are consistent with the results of the study on the brain white matter of patients with chronic multiple sclerosis, chronic ischemic damage and other axonal degeneration diseases and Alzheimer's disease. The increase of MD indicates that the mobility of water molecules in the white matter of anterior central gyrus and the posterior limb of the internal capsule is enhanced in ALS patients, which may be related to the axonal changes in the above areas leading to the expansion of extracellular matrix and the expansion of extracellular space, thus enhancing the diffusion ability of water molecules. However, compared with the control group, the FA values in the center of semioval, the white matter around the lateral ventricle, the foot of brain and the pyramidal area of medulla oblongata in the case group were significantly reduced, but the difference in MD was not statistically significant, which may indicate that the pyramidal tract in the above areas was damaged, but the cell density did not change. This is because the accompanying glial cell proliferation fills the extracellular space enlarged by axonal degeneration and deletion, which keeps the cell density of pyramidal tract in ALS patients, and the diffusivity of water molecules has not changed significantly. It can be seen that FA value is a sensitive index to evaluate the change of pyramidal tract disease.

V. CONCLUSION

DTI is a non-invasive method to trace the white matter fibers and reflect their anatomical connectivity. It provides a new technical means to study the direction, detour, crossing, sparse, pushing, interruption, destruction and other abnormal manifestations of white matter fiber bundles in vivo. Our study showed that compared with the control group, the values of subcortical white matter, semicircular center, periventricular white matter, posterior limb of internal capsule, cerebral foot and medullary cone in the case group were significantly reduced. The MD value of white matter in anterior central gyrus and posterior limb of internal capsule increased, which was consistent with the pathological changes of atrophy and disappearance of motor cortex cells, axonal degeneration and demyelination of pyramidal tract in ALS patients. In a word, among the many parameters of DTI, the changes of RA and AI in ALS patients are more obvious, among which RA is more stable; the sensitivity of detection in the center of semioval, corona radiata and parawhite matter of lateral ventricle is higher, and the specificity of multi parameter judgment in the posterior limb of

internal capsule, pons and pyramidal medulla oblongata is higher. DTI is one of the valuable methods to evaluate the pathological changes of pyramidal tract in vitro and non-invasively. It can objectively and quantitatively evaluate the pathological changes of pyramidal tract of patients, provide valuable information for the diagnosis of ALS, and have important significance for deepening our understanding of the disease. However, as a new means, DTI is still in the exploration stage in its application, and the current research samples are mostly small samples, so it is still necessary to carry out a large sample of in-depth research to get evidence-based medicine. It is believed that with the further study of DTI, its role in pyramidal tract diseases including ALS will be further revealed. DTI is a non-invasive and objective method to reflect the pathological damage of upper motor neurons, but there is no unified parameter and numerical value to judge the damage of pyramidal tract, so it has great limitations in clinical application. With the development of MR technology and ALS molecular pathology, DTI will become a mature diagnostic tool, which can provide important help for clinical practice.

REFERENCES

- [1] A. Carotenuto, "Upper motor neuron evaluation in multiple sclerosis patients treated with Sativex," *Acta Neurologica Scandinavica*, vol. 135, no. 4, pp. 442–448, 2016.
- [2] F. Antonescu, "A review of cervical spine MRI in ALS patients," *J. Med. Life*, vol. 11, no. 2, pp. 123–127, 2018.
- [3] H. P. Gunbey, E. Gunbey, K. Aslan, T. Bulut, A. Unal, and L. Incesu, "Limbic-auditory interactions of tinnitus: An evaluation using diffusion tensor imaging," *Clin. Neuroradiol.*, vol. 27, no. 2, pp. 221–230, Jun. 2017.
- [4] A. Kia, K. McAvoy, K. Krishnamurthy, D. Trotti, and P. Pasinelli, "Astrocytes expressing ALS-linked mutant FUS induce motor neuron death through release of tumor necrosis factor- α ," *Glia*, vol. 66, no. 5, pp. 1016–1033, May 2018.
- [5] D. K. Wright, S. Liu, C. van der Poel, S. J. McDonald, R. D. Brady, L. Taylor, L. Yang, A. J. Gardner, R. Ordidge, T. J. O'Brien, L. A. Johnston, and S. R. Shultz, "Traumatic brain injury results in cellular, structural and functional changes resembling motor neuron disease," *Cerebral Cortex*, vol. 27, no. 9, pp. 4503–4515, Aug. 2016.
- [6] A. Geronimo and Z. Simmons, "Evaluation of remote pulmonary function testing in motor neuron disease," *Amyotrophic Lateral Sclerosis Frontotemporal Degeneration*, vol. 20, nos. 5–6, pp. 348–355, Jul. 2019.
- [7] M. P. Menezes, M. A. Farrar, R. Webster, J. Antony, K. O'Brien, R. Ouvrier, M. C. Kiernan, J. Burns, and S. Vucic, "Pathophysiology of motor dysfunction in a childhood motor neuron disease caused by mutations in the riboflavin transporter," *Clin. Neurophysiol.*, vol. 127, no. 1, pp. 911–918, Jan. 2016.
- [8] M.-G. Liu, J.-W. Niu, and L.-Y. Cui, "A report on paraneoplastic motor neuron disease," *Chin. Med. J.*, vol. 132, no. 6, pp. 719–722, Mar. 2019.
- [9] Q. J. Zhang, D. Wang, Z. L. Bai, B. C. Ren, and X.-H. Li, "Diffusion tensor imaging of optic nerve and optic radiation in primary chronic angle-closure glaucoma using 3T magnetic resonance imaging," *Int. J. Ophthalmol.*, vol. 8, no. 5, pp. 975–983, 2015.
- [10] M. Koszewicz, S. Budrewicz, P. Szewczyk, and K. Slotwinski, "Symptoms of degeneration of the pyramidal tracts in conventional magnetic resonance imaging and diffusion tensor imaging in a young woman with primary lateral sclerosis," *J. Postgraduate Med.*, vol. 61, no. 3, pp. 206–208, 2015.
- [11] K. K. Hirai, B. N. Groisser, W. A. Copen, A. B. Singhal, and J. D. Schaechter, "Comparing prognostic strength of acute corticospinal tract injury measured by a new diffusion tensor imaging based template approach versus common approaches," *J. Neurosci. Methods*, vol. 257, pp. 204–213, Jan. 2016.

- [12] M. M. Gold, K. Shifteh, S. Valdborg, J. Lombard, and M. L. Lipton, "Brain injury due to ventricular shunt placement delineated by diffusion tensor imaging (DTI) tractography," *Neurologist*, vol. 14, no. 4, pp. 252–255, 2015.
- [13] Y. Chen, Q. Wang, Q. Wang, H. Liu, F. Zhou, Y. Zhang, M. Yuan, C. Zhao, Y. Guan, and X. Wang, "DDX3 binding with CK1 ϵ was closely related to motor neuron degeneration of ALS by affecting neurite outgrowth," *Amer. J. Transl. Res.*, vol. 9, no. 10, pp. 4627–4639, 2017.
- [14] N. D. Rudnick, C. J. Griffey, P. Guarnieri, V. Gerbino, X. Wang, J. A. Piersaint, J. C. Tapia, M. M. Rich, and T. Maniatis "Distinct roles for motor neuron autophagy early and late in the SOD1G93A mouse model of ALS," *Proc. Nat. Acad. Sci. USA*, vol. 114, no. 39, pp. 8294–8303, 2017.
- [15] C. Yang, E. W. Danielson, T. Qiao, J. Metterville, R. H. Brown, J. E. Landers, and Z. Xu, "Mutant PFN1 causes ALS phenotypes and progressive motor neuron degeneration in mice by a gain of toxicity," *Proc. Nat. Acad. Sci. USA*, vol. 113, no. 41, pp. E6209–E6218, Oct. 2016.
- [16] P. Ciryam, I. A. Lambert-Smith, D. M. Bean, R. Freer, F. Cid, G. G. Tartaglia, D. N. Saunders, M. R. Wilson, S. G. Oliver, R. I. Morimoto, C. M. Dobson, M. Vendruscolo, G. Favrin, and J. J. Yerbury, "Spinal motor neuron protein supersaturation patterns are associated with inclusion body formation in ALS," *Proc. Nat. Acad. Sci. USA*, vol. 114, no. 20, pp. E3935–E3943, May 2017.
- [17] E. Verstraete, M. R. Turner, J. Grosskreutz, M. Filippi, and M. Benatar, "Mind the gap: The mismatch between clinical and imaging metrics in ALS," *Amyotrophic Lateral Sclerosis Frontotemporal Degeneration*, vol. 16, nos. 7–8, pp. 524–529, Nov. 2015.
- [18] R. Arakawa, M. Arakawa, K. Kaneko, N. Otsuki, R. Aoki, and K. Saito, "Imaging flow cytometry analysis to identify differences of survival motor neuron protein expression in patients with spinal muscular atrophy," *Pediatric Neurol.*, vol. 61, pp. 70–75, Aug. 2016.
- [19] A. Chiò, and B. J. Traynor, "Biomarkers for ALS—In search of the Promised Land," *Nature Rev. Neurol.* vol. 11, no. 2, pp. 72–75, 2015.
- [20] D. V. Emeliannikov, E. Y. Shapkova, T. R. Moshonkina, and Y. P. Gerasimenko, "Evaluation of motor neuron excitability in lumbosacral spinal cord: Transcutaneous spinal cord stimulation as compared to H-reflex," *Fiziologija Cheloveka*, vol. 42, no. 3, pp. 32–36, 2016.
- [21] K. Szacka, A. Potulska-Chromik, K. Fronczewska-Wieniawska, A. Spychala, L. Króllicki, and M. Kuzma-Kozakiewicz, "Scintigraphic evaluation of mild to moderate dysphagia in motor neuron disease," *Clin. Nucl. Med.*, vol. 41, no. 4, pp. e175–e180, Apr. 2016.
- [22] P. Tripathi, N. Rodriguez-Muela, J. R. Klim, A. S. de Boer, S. Agrawal, J. Sandoe, C. S. Lopes, K. S. Oglari, L. A. Williams, M. Shear, L. L. Rubin, K. Eggan, and Q. Zhou, "Reactive astrocytes promote ALS-like degeneration and intracellular protein aggregation in human motor neurons by disrupting autophagy through TGF- β 1," *Stem Cell Rep.*, vol. 9, no. 2, pp. 667–680, Aug. 2017.
- [23] J.-I. Satoh, N. Asahina, S. Kitano, and Y. Kino, "A comprehensive profile of ChIP-Seq-based Olig2 target genes in motor neuron progenitor cells suggests the possible involvement of Olig2 in the pathogenesis of amyotrophic lateral sclerosis," *J. Central Nervous Syst. Disease*, vol. 7, Jan. 2015, Art. no. JCNDS.S23210.
- [24] Q. M. Zhou, J. J. Zhang, S. Li, S. Chen, and W.-D. Le, "n-butylidenephthalide treatment prolongs life span and attenuates motor neuron loss in SOD1^{G93A} mouse model of amyotrophic lateral sclerosis," *CNS Neurosci. Therapeutics*, vol. 23, no. S1, pp. 375–385, 2017.
- [25] M. Baguma-Nibasheka, A. Fracassi, W. J. Costain, S. Moreno, and B. Kablar, "Role of skeletal muscle in motor neuron development," *Histol. Histopathol.*, vol. 31, no. 7, pp. 699–719, 2016.
- [26] J. Li, Y. Lu, H. Liang, C. Tang, L. Zhu, J. Zhang, and R. Xu, "Changes in the expression of FUS/TLS in spinal cords of SOD1^{G93A} transgenic mice and correlation with motor-neuron degeneration," *Int. J. Biol. Sci.*, vol. 12, no. 10, pp. 1181–1190, 2016.
- [27] Y. Kushimura, T. Tokuda, Y. Azuma, I. Yamamoto, I. Mizuta, T. Mizuno, M. Nakagawa, M. Ueyama, Y. Nagai, H. Yoshida, and M. Yamaguchi, "Overexpression of ter94, Drosophila VCP, improves motor neuron degeneration induced by knockdown of TBPH, Drosophila TDP-43," *Amer. J. Neurodegenerative Diseases*, vol. 7, no. 1, pp. 11–31, 2018.
- [28] K. Shibuya, "Cortical motor neuron hyperexcitability and motor neuron death in ALS: Dying forward hypothesis," *Brain Nerve Shinkei Kenkyu Shinpo*, vol. 69, no. 5, pp. 565–569, 2017.
- [29] N. Bernard-Marissal, J.-J. Médard, H. Azzedine, and R. Chrast, "Dysfunction in endoplasmic reticulum-mitochondria crosstalk underlies SIGMAR1 loss of function mediated motor neuron degeneration," *Brain*, vol. 138, no. 4, pp. 875–890, Apr. 2015.
- [30] C. C. Iyer, V. L. McGovern, J. D. Murray, S. E. Gombash, P. G. Zaworski, K. D. Foust, P. M. L. Janssen, and A. H. M. Burghes, "Low levels of Survival Motor Neuron protein are sufficient for normal muscle function in the SMN Δ 7 mouse model of SMA," *Hum. Mol. Genet.*, vol. 24, no. 21, pp. 6160–6173, 2015.
- [31] N. T. Le, L. Chang, I. Kovlyagina, P. Georgiou, N. Safren, K. E. Braunstein, M. D. Kvarata, A. M. Van Dyke, T. A. Philips, and B. M. Morrison, "Motor neuron disease, TDP-43 pathology, and memory deficits in mice expressing ALS–FTD-linked UBQLN2 mutations," *Proc. Nat. Acad. Sci. USA*, vol. 113, no. 47, pp. E7580–E7589, 2016.
- [32] M. Naseri, P. Petramfar, and A. Ashraf, "Effect of motor imagery on the F-Wave parameters in hemiparetic stroke survivors," *Ann. Rehabil. Med.*, vol. 39, no. 3, pp. 401–408, 2015.
- [33] K. Sugiyama, T. Aida, M. Nomura, R. Takayanagi, H. U. Zeilhofer, and K. Tanaka, "Calpain-dependent degradation of nucleoporins contributes to motor neuron death in a mouse model of chronic excitotoxicity," *J. Neurosci.*, vol. 37, no. 36, pp. 8830–8844, Sep. 2017.
- [34] G. C. Tan, E. O. Mazzoni, and H. Wichterle, "Iterative role of notch signaling in spinal motor neuron diversification," *Cell Rep.*, vol. 16, no. 4, pp. 907–916, Jul. 2016.
- [35] Y. Kobayakawa, K. Sakumi, K. Kajitani, T. Kadoya, H. Horie, J.-I. Kira, and Y. Nakabeppu, "Galectin-1 deficiency improves axonal swelling of motor neurons in SOD1G93A transgenic mice," *Neuropathol. Appl. Neurobiol.*, vol. 41, no. 2, pp. 227–244, Feb. 2015.
- [36] D. Capauto, A. Colantoni, L. Lu, T. Santini, G. Peruzzi, S. Biscarini, M. Morlando, N. A. Sheider, E. Caffarelli, P. Laneve, and I. Bozzoni, "A regulatory circuitry between *gria2*, miR-409, and miR-495 is affected by ALS FUS mutation in ESC-derived motor neurons," *Mol. Neurobiol.*, vol. 55, no. 10, pp. 7635–7651, Oct. 2018.
- [37] J. E. Brandenburg, H. M. Gransee, M. J. Fogarty, and G. C. Sieck, "Differences in lumbar motor neuron pruning in an animal model of early onset spasticity," *J. Neurophysiol.*, vol. 120, no. 2, pp. 601–609, Aug. 2018.
- [38] G. R. Barsh, A. J. Isabella, and C. B. Moens, "Vagus motor neuron topographic map determined by parallel mechanisms of *hox5* expression and time of axon initiation," *Current Biol.*, vol. 27, no. 24, pp. 3812–3825, Dec. 2017.
- [39] A. Sarsilmaz, Z. Firat, A. M. Ulug, G. Karlıkaya, C. A. Bingöl, A. Hamamci, I. Kovanlikaya, "Diffusion tensor imaging in early amyotrophic lateral sclerosis using 3T magnetic resonance imaging," *J. Neurol. Sci. Turkish*, vol. 35, no. 2, pp. 102–107, 2018.
- [40] Y. Duclos, A. M. Grapperon, E. Jouve, R. Truillet, C. Zemmour, A. Verschueren, J. Pouget, and S. Attarian, "Motor-evoked potential gain is a helpful test for the detection of corticospinal tract dysfunction in amyotrophic lateral sclerosis," *Clin. Neurophysiol.*, vol. 128, no. 2, pp. 357–364, Feb. 2017.
- [41] N. G. Simon, J. Lagopoulos, S. Paling, C. Pfluger, S. B. Park, J. Howells, T. Gallagher, M. Kliot, R. D. Henderson, S. Vucic, and M. C. Kiernan, "Peripheral nerve diffusion tensor imaging as a measure of disease progression in ALS," *J. Neurol.*, vol. 264, no. 5, pp. 882–890, May 2017.
- [42] E. G. Spinelli, F. Agosta, P. M. Ferraro, N. Riva, C. Lunetta, Y. M. Falzone, G. Comi, A. Falini, and M. Filippi, "Brain MR imaging in patients with lower motor neuron-predominant disease," *Radiology*, vol. 280, no. 2, pp. 545–556, Aug. 2016.
- [43] W. Huynh, N. G. Simon, J. Grosskreutz, S. Vucic, M. C. Kiernan, and M. R. Turner, "Assessment of the upper motor neuron in amyotrophic lateral sclerosis," *Clin. Neurophysiol.*, vol. 127, no. 7, pp. 2643–2660, 2016.
- [44] A. F. Geraldo, J. Pereira, P. Nunes, S. Reimão, R. Sousa, M. Castelo-Branco, S. Pinto, J. G. Campos, and M. de Carvalho, "Beyond fractional anisotropy in amyotrophic lateral sclerosis: The value of mean, axial, and radial diffusivity and its correlation with electrophysiological conductivity changes," *Neuroradiology*, vol. 60, no. 5, pp. 505–515, May 2018.
- [45] Y. Fukui, N. Hishikawa, K. Sato, Y. Nakano, R. Morihara, J. Shang, M. Takemoto, Y. Ohta, T. Yamashita, and K. Abe, "Detecting spinal pyramidal tract of amyotrophic lateral sclerosis patients with diffusion tensor tractography," *Neurosci. Res.*, vol. 133, pp. 58–63, Aug. 2018.

- [46] A. Hübers, H. P. Müller, J. Dreyhaupt, K. Böhm, F. Lauda, H. Tumani, J. Kassubek, A. C. Ludolph, and E. H. Pinkhardt, "Retinal involvement in amyotrophic lateral sclerosis: A study with optical coherence tomography and diffusion tensor imaging," *J. Neural Transmiss.*, vol. 123, no. 3, pp. 281–287, Mar. 2016.
- [47] F. Zhang, G. Chen, M. He, J. Dai, H. Shang, Q. Gong, and Z. Jia, "Altered white matter microarchitecture in amyotrophic lateral sclerosis: A voxel-based meta-analysis of diffusion tensor imaging," *NeuroImage, Clin.*, vol. 19, pp. 122–129, Jan. 2018.
- [48] T. M. Jenkins, J. J. P. Alix, J. Fingret, T. Esmail, N. Hoggard, K. Baster, C. J. McDermott, I. D. Wilkinson, and P. J. Shaw, "Longitudinal multimodal muscle-based biomarker assessment in motor neuron disease," *J. Neurol.*, vol. 267, no. 1, pp. 244–256, Jan. 2020.
- [49] R. G. Gatto, M. Amin, A. Finkielstein, C. Weissmann, T. Barrett, C. Lamoutte, O. Uchitel, R. Sumagin, T. H. Mareci, and R. L. Magin, "Unveiling early cortical and subcortical neuronal degeneration in ALS mice by ultra-high field diffusion MRI," *Amyotrophic Lateral Sclerosis Frontotemporal Degeneration*, vol. 20, nos. 7–8, pp. 549–561, Oct. 2019.
- [50] J. Fabes, L. Matthews, N. Filippini, K. Talbot, M. Jenkinson, and M. R. Turner, "Quantitative FLAIR MRI in amyotrophic lateral sclerosis," *Acad. Radiol.*, vol. 24, no. 10, pp. 1187–1194, Oct. 2017.
- [51] J. Prudlo, C. Bißbort, A. Glass, A. Grossmann, K. Hauenstein, R. Benecke, and S. J. Teipel, "White matter pathology in ALS and lower motor neuron ALS variants: A diffusion tensor imaging study using tract-based spatial statistics," *J. Neurol.*, vol. 259, no. 9, pp. 1848–1859, Sep. 2012.
- [52] A. Ishaque, D. Mah, P. Seres, C. Luk, W. Johnston, S. Chenji, C. Beaulieu, Y. Yang, and S. Kalra, "Corticospinal tract degeneration in ALS unmasked in T1-weighted images using texture analysis," *Hum. Brain Mapping*, vol. 40, no. 4, pp. 1174–1183, Mar. 2019.
- [53] A. Calvo, A. Chiò, M. Pagani, S. Cammarosano, F. Dematteis, C. Moglia, L. Solero, U. Manera, T. Martone, M. Brunetti, and M. Balma, "Parkinsonian traits in amyotrophic lateral sclerosis (ALS): A prospective population-based study," *J. Neurol.*, vol. 266, no. 7, pp. 1633–1642, Jul. 2019.



YONG SANG was born in Shouguang, China, in 1981. He studied at the School of Physical Education and Sports Science, from 1999 to 2003, majored in volleyball. After his graduation, he has been working with the Department of Physical Education, since 2003. From 2007 to 2010, he enrolled his graduate study in humane and sociological science of sports. Since 2013, he began to coach the school volleyball team and accumulated rich experience. Over the years, he has published several high quality articles on various academic journals. In 2019, he championed the Qufu Normal University Young Teachers' Teaching Contest.



JINGFENG XU was born in Linqu, China, in 1979. He studied in the School of Physical Education and Sports Science, from 1999 to 2003, majored in basketball. After his graduation, he worked at the Department of Physical Education, from 2003 to 2013. From 2009 to 2012, he enrolled his graduate study in science of sports pedagogy and training. Since 2013, he has been working at the Office of Academic Affairs, Weifang Vocational College, and accumulated rich working experience. Over the years, he has published several high quality articles on various academic journals.

• • •