

Received December 22, 2019, accepted December 30, 2019, date of publication January 3, 2020, date of current version January 10, 2020.

Digital Object Identifier 10.1109/ACCESS.2019.2963748

Tortuosity of Retinal Main and Branching Arterioles, Venules in Patients With Type 2 Diabetes and Diabetic Retinopathy in China

SHANSHAN ZHU¹, HENAN LIU², RUNYU DU³, DIBANDA S. ANNICK¹, SHUO CHEN^{1,4}, AND WEI QIAN⁵

¹College of Medicine and Biological Information Engineering, Northeastern University, Shenyang 110169, China

²Department of Ophthalmology, Shengjing Hospital, China Medical University, Shenyang 110004, China

³Department of Endocrinology, Shengjing Hospital, China Medical University, Shenyang 110004, China

⁴Key Laboratory of Data Analytics and Optimization for Smart Industry (Northeastern University), Ministry of Education, Shenyang 110169, China

⁵College of Engineering, The University of Texas at El Paso, El Paso, TX 79968, USA

Corresponding author: Shuo Chen (chenshuo@bmie.neu.edu.cn)


This work was supported in part by the National Natural Science Foundation of China under Grant 61605025, in part by the Innovative Research Groups of the National Natural Science Foundation of China under Grant 71621061, in part by the Program for Innovation Talents in Universities of Liaoning Province under Grant LR2016031, in part by the Ningbo Natural Science Foundation under Grant 2018A610365, in part by the Fundamental Research Funds for the Central Universities under Grant N171902001, Grant N171904006, and Grant N180719020, and in part by the 111 Project under Grant B16009.

ABSTRACT The epidemic studies have demonstrated an excessively increase of diabetic patients in recent years, who are at high risk of developing microvascular complications. Those microvascular complications usually lead to chronic health problems, e.g. diabetic retinopathy (DR), thus early and regular screening is indeed necessary. Retinal vascular tortuosity, which is one of geometrical parameters related to microvascular morphological changes, has been investigated in many studies related to diabetes, diabetic risk factors and diabetic complications. However, the global tortuosity of retinal vessels in DR progression is quantified either subjectively or imprecisely in those previous studies. Furthermore, to our best knowledge, the association of tortuosity, diabetes and DR has never been investigated based on a Chinese population-based cohort, even though it accounts for more than 30% of diabetic patients worldwide. Therefore, it is of great necessary and clinical significance to extract retinal tortuosity in a more reliable way and explore its associations with diabetic risk factors and DR severity in China. In this study, high contrast retinal images from 495 Chinese patients with type 2 diabetes were acquired by confocal scanning laser ophthalmoscope and the global tortuosity was extracted from main and branching arterioles, venules in the whole retinal image based on the theory of best-fit exponential curves in the roto-translation group $SE(2)$. The statistical analysis results show that retinal arteriolar and venular tortuosity might be remarkable indices for assessing retinopathy severity and identifying individuals with high-risk of renal disease in diabetes, which may provide additional insights on microvascular changes for diabetic retina and kidney diseases.

INDEX TERMS Diabetes, diabetic retinopathy, tortuosity, main and branching vessels, confocal scanning laser ophthalmoscope.

I. INTRODUCTION

The epidemic of diabetes shows an excessive increase from 108 million adults in 1980 to an estimated 422 million adults worldwide in recent years [1]. With the economic and social development in China, lifestyle change has led to the rapid

The associate editor coordinating the review of this manuscript and approving it for publication was Donato Impedovo .

growth of diabetes [2]. It is reported that more than one in ten Chinese adults suffer from diabetes, and even half of Chinese adults suffer from pre-diabetes [3]. It is known that microvascular complications such as diabetic retinopathy (DR) are considerably prevalent in diabetic patients [4]. A meta-analysis reports that 34.6% diabetic patients suffer from DR and 10.2% of those suffer from vision-threatening DR in Asia, and similar situations also happened

worldwide [5]. Although the pathological mechanisms of those microvascular complications are still unclear, early screening and regular examination of retina based on retinal photography are clinically essential. The retinal vasculature can be viewed directly and noninvasively, thus offers a unique and accessible way to assess the status of the microvasculature *in vivo* and quantify the microvascular changes in diabetic patients.

Recently, many researches have shown great interest in one of the morphological features of retinal microvasculature, i.e. retinal vascular tortuosity (curvature), which is sensitive to early hemodynamic changes in diabetes [6]–[9] and is expected to be a useful biomarker for diabetes and diabetic retinopathy. However, the global tortuosity of retinal vessels in DR progression is quantified either subjectively or imprecisely in the previous studies. In clinics, the global tortuosity is commonly quantified based on the clinician's observation and roughly categorized into four grades (i.e. mild, moderate, severe and extreme), which relies heavily on the clinician's experience and the grading may vary among different clinicians [10]. Although computer-aided quantification methods have been developed for tortuosity extraction, the global tortuosity might not be finely quantified because those methods are usually performed on color fundus images, which optical resolution and contrast should be lower compared to confocal scanning laser ophthalmoscopy (SLO) image. In some previous studies [7], [9], even only partial of the color fundus image, i.e. the biggest six arterioles and venules with diameter larger than $40\mu\text{m}$ within a local region of 0.5 to 2.0 disc diameters away from the disc margin, were used for tortuosity extraction, in which smaller arterioles and venules were always ignored. However, the retinal vessels become tortuous either locally and/or over an extended area during DR progression [11]. Therefore, tortuosity extracted from main and branching retinal vessels in an extended area is more convincing to assess the pathological origin and can play an important role in helping ophthalmologists in diagnosing the severity of DR [12]. In response to this demand, we extract tortuosity features directly from the entire SLO retinal image including main and branching arterioles and venules instead of vessels in a local grid, and explore the associations among tortuosity, diabetes and DR.

Although prior studies have demonstrated that retinal vascular tortuosity is closely associated with diabetic risk factors and DR [7], [9], [13], the relationships of arteriolar and venular tortuosity separately with diabetic risk factors and the severity of DR are inconsistent. Sasongko *et al.* indicated that people with diabetes were more likely to have tortuous arteriolar and venular vessels, and larger arteriolar tortuosity value was usually associated with mild and moderate DR [7]. Moreover, it was found that larger retinal arteriolar tortuosity value was related to longer diabetes duration, thus retinal arteriolar tortuosity can be used as a biomarker for diabetes damage on the retinal microvasculature [8]. In contrast, by controlling age, sex, arterial blood pressure, body mass index, total cholesterol level, and smoking status,

Cheung *et al.* found that diabetic patients had less tortuous arterioles [9], which is contrary to the conclusion drawn by the above studies. This might be attributed to the vascular tortuosity differences among various ethnicities [14]. Thus, it is necessary to investigate various ethnic groups individually in order to find an accurate relationship between vascular tortuosity, diabetes and diabetic retinopathy. To our best knowledge, there has been no report about retinal vascular tortuosity and DR severity based on diabetes in China, even though it accounts for more than 30% of diabetic patients worldwide [2]. Thus, it is of great necessary and clinical significance to explore the associations between arteriolar and venular tortuosity and diabetic risk factors as well as DR severity among diabetic patients in China.

In this study, we aimed to investigate the associations of retinal arteriolar and venular tortuosity with diabetic risk factors and DR in a Chinese population-based cohort. Strengths of our study include that a quantitative method was used to extract retinal arteriolar and venular tortuosity including main and branching vessels with high reliability. Combined with higher contrast retinal photographs taken by a confocal laser-scanning ophthalmoscope camera, more precise global tortuosity of the retinal vasculature can be extracted from main and branching vessels. Moreover, this is for the first time that a cohort study of Chinese diabetes was performed to explore the associations of arteriolar and venular tortuosity with diabetic risk factors and DR, which can provide additional insights in microvascular disease for Chinese diabetic patients.

II. MATERIAL AND METHODS

A. STUDY PARTICIPANTS AND RETINAL PHOTOGRAPHS COLLECTION

This study complies with the principles of the Declaration of Helsinki and was approved by the Institutional Review Board/Ethics Committee of Shengjing Hospital, China Medical University, China. All patients signed written informed consent before enrollment. All data were collected from diabetic patients who were hospitalized in the department of endocrinology at Shengjing Hospital. After excluding individuals with glaucoma, cataract, vitreous/retinal surgery history, or suffered from any retinal or eye disease other than DR, a total of 495 patients with type 2 diabetes were selected. Participants underwent a standardized interview, systemic and ocular examination, and laboratory investigations using standardized protocols. Retinal photographs were taken from both eyes by using a confocal scanning laser ophthalmoscope (EasyScan, i-Optics Inc., Netherlands). Such ophthalmoscope can capture a field of view of 45° with pupil size above 1.5mm, in which the image acquisition can typically be implemented without mydriasis. Two lasers with different wavelengths (i.e. 520nm and 780nm) and confocal optical design were employed to alleviate the stray light from the lens and the viscous body, thus good contrast and high optical resolution ($\sim 15\mu\text{m}$) can be achieved. In this study, only the

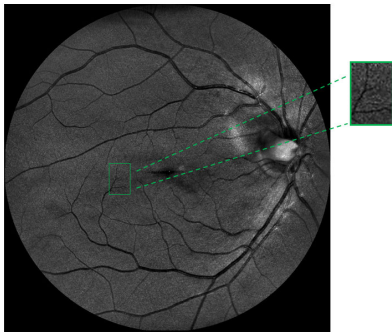


FIGURE 1. The 5th branching vessels near the macula can be visualized by using confocal laser scanning ophthalmoscope.

green channel images were used for maximum contrast of the blood vessels in the top layer of the retina, which allows the clear visualization of the 5th branching vessels near the macula, as shown in Fig.1. The retinal images with fovea-center of the right eye were preferentially used for further analysis, however, the retinal image of the left eye would be used if the right eye's retinal image was blurred, contained incomplete regions, or with more than two ungradable arterioles or venules.

B. ASSESSMENT OF DR SEVERITY

DR was evaluated from the retinal photographs by ophthalmologists according to the simple International Classification of DR scale [15]. DR was diagnosed upon the presence of at least one microaneurysm or hemorrhage in either eye. The severity of DR was graded as follows: 1. Class R0: no abnormalities; 2. Class R1 (mild non-proliferative DR, mild NPDR): only microaneurysms were observed; 3. Class R2 (moderate non-proliferative DR, moderate NPDR): other symptoms were found, such as dot and blot hemorrhages, hard exudates and cotton wool spots, but milder than severe non-proliferative DR; 4. Class R3 (severe non-proliferative DR and proliferative DR, severe NPDR and PDR): more abnormalities were observed, such as intraretinal hemorrhages, venous beading, intraretinal microvascular abnormalities, neovascularization and vitreous/preretinal hemorrhage.

C. MEASUREMENT OF RETINAL VASCULAR TORTUOSITY

Before the retinal vascular tortuosity was calculated, an automatic and efficient software (Retinal Health Information and Notification System-RHINO) [16] was used to identify the arteries from veins in those retinal images. More specifically, the artery and vein identification was implemented according to the following steps: 1. The retinal images were locally normalized to alleviate non-uniform illumination and varying contrast; 2. The retinal vascular tree were further enhanced and segmented by using rotating multi-scale second-order Gaussian derivative filters and a proper threshold [17], [18], thus binary vessel map can be obtained; 3. A logistic regression classifier was employed to classify arteries and veins according to each pixel features, i.e. local intensities of the

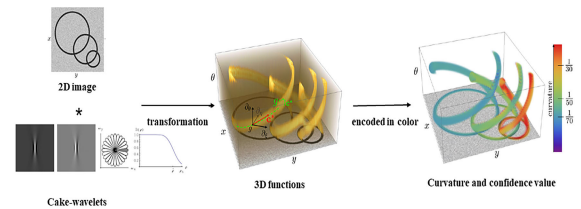


FIGURE 2. The schematic of global tortuosity extraction based on the theory of best-fit exponential curves in the roto-translation group $SE(2)$.

green channels, the mean, standard deviation, median, minimum and maximum of the intensities inside circular regions, and the intensity values along each vessel centerline.

Thereafter, a quantitative method [19] developed by Bekkers *et al.* was used to derive global tortuosity of the arterioles and venules directly from retinal images after A/V classification, respectively. This method was based on the theory of best-fit exponential curves in the roto-translation group $SE(2)$ [20]–[22], as shown in Fig. 2. Planar curves were lifted to 3D functions by adding an orientation dimension in the domain, in which such 3D functions can be calculated by convoluting retinal images with a specially designed anisotropic cake-wavelet [23], [24]. In this extended domain of positions and orientations, a curvature and confidence value were assigned to each location by locally fitting exponential curves to the data in 3D functions. The global tortuosity can finally be calculated by the weighted average of the curvatures from all pixels in each retinal image, in which the corresponding confidence values were served as the weights.

D. STATISTICAL ANALYSIS

In this study, three types of statistical analysis, i.e. baseline characteristics analysis, linear regression analysis and logistic regression analysis, were performed. In baseline characteristics analysis, the participants were divided into DR and no DR groups, and the participants' characteristics between those two groups were statistically analyzed by Student's t test, Mann-Whitney U test or Chi-squared test, respectively [7], [9]. In linear regression analysis, global tortuosity values of arterioles and venules were treated as dependent variables respectively, and both univariable regression analysis and multivariate regression analysis were implemented. More specifically, two models were constructed during the multivariable regression analysis: Model 1 adjusted for age and sex, and model 2 additionally adjusted for duration of diabetes, low density lipoprotein (LDL), high density lipoprotein (HDL), glycated hemoglobin (HbA_{1c}), urine microalbuminuria and urinary albumin/creatinine ratio. In logistic regression analysis, global tortuosity values of arterioles and venules were served as independent variables respectively, while severity level of DR was served as dependent variable. More specifically, multinomial logistic regression models [7] were performed to assess the odds of each DR severity stage associated with arteriolar and venular tortuosity, in which diabetic patients without DR were served as reference.

TABLE 1. Baseline characteristics and comparison between DR and no DR in type 2 diabetes.

Participants' characteristics	Groups ^a			<i>p</i> value ^b
	Total (n=495)	No DR (n=122)	Any DR (n=373)	
Sex (male), %	58.2	61.1	57.3	0.516
Hypertension, %	40.6	44.2	39.5	0.384
Current smoking, %	35.8	42.5	33.8	0.095
CVD history, %	10.5	9.7	10.7	0.862
Thrombosis history, %	5.3	7.1	4.7	0.338
Age, years	51.4±12.8	49.1±15.2	51.6±11.3	0.043
Duration, years	6.93±6.51	5.8±5.4	7.3±6.7	0.041
HbA _{1c} , %	8.9±2.4	9.0±2.3	8.9±2.5	0.634
FBS, mmol/L	9.3±3.5	9.4±2.8	9.3±3.7	0.983
BMI, kg/m ²	26.0±4.0	26.1±4.4	26.0±3.8	0.882
SBP, mmHg	132.2 ± 16.1	125.6±14.1	133.5±15.7	0.004
DBP, mmHg	78.6 ± 10.1	74.7±8.7	81.2±10.3	0.003
Cholesterol, mmol/L	4.8±1.2	4.8±1.4	4.8±1.1	0.847
LDL, mmol/L	2.9±0.9	2.8±0.9	2.9±0.9	0.448
HDL, mmol/L	1.0±0.4	1.0±0.5	1.0±0.3	0.622
Triglyceride, mmol/L	2.9±3.4	3.1±3.9	2.9±3.2	0.513
Urea, mmol/L	5.4±1.8	5.6±1.9	5.3±1.8	0.276
Urine microalbuminuria, mg/dL	10.0±43.0	6.8±33.9	11.0±45.3	0.384
Urinary albumin/creatinine ratio	120.6±513.7	85.7±502.2	131.2±517.4	0.430
Blood creatinine, μmol/L	63.9±23.2	64.3±19.8	63.4±24.1	0.854
Retinal arteriolar tortuosity (×10 ³)	14.5±3.0	14.0±2.5	14.7±3.1	0.013
Retinal venular tortuosity (×10 ³)	17.6±2.2	17.3±2.2	17.6±2.2	0.171

CVD: Cerebral vascular disease; HbA_{1c}: glycated hemoglobin; FBS: Fasting Blood Sugar; BMI: body mass index; SBP: systolic blood pressure; DBP: diastolic blood pressure; LDL: low density lipoprotein; HDL: high density lipoprotein.

^a The descriptive statistics were expressed as mean and standard deviation for continuous variables, while percentage for categorical variables.

^b *p* values were obtained using Chi-squared test for categorical data, Student's *t* test for continuous and normally distributed data, and Mann-Whitney *U* test for continuous and skewed data.

All statistical analyses were conducted by IBM SPSS Statistics Version 22.0 (IBM, Armonk, NY, USA). All the above mentioned statistical tests were two-tailed, and $p < 0.05$ was considered statistically significant.

III. RESULTS

Table 1 shows the summary of participants' characteristics. There were 373 (75.4%) diabetic patients with DR. Compared with those without DR, diabetic patients with DR were older and more likely to have longer durations of diabetes, higher systolic blood pressure (SBP) and diastolic blood pressure (DBP) levels. Furthermore, arteriolar tortuosity values were larger in diabetic patients with DR compared to patients without DR, but no significant difference of venular tortuosity was found between the groups of DR and no DR.

Table 2 and 3 show the linear regression analysis between conventional diabetic risk factors with retinal arteriolar and venular tortuosity, respectively. As risk factors for renal disease, urine microalbuminuria was cataloged into low-risk (≤ 1.9 mg/dL) and high-risk (>1.9 mg/dL) groups, and the

urine albumin/creatinine ratio was cataloged into large-ratio (>30) and small-ratio (≤ 30) groups [25]. It was found that greater arteriolar and venular tortuosity were independently associated with younger age in both univariable and multivariable linear regression analyses (all $p < 0.05$). In addition, compared to the small-ratio group, both arteriolar and venular tortuosity were significantly higher in large-ratio group of urinary albumin/creatinine ratio (all $p < 0.05$) in the linear regression models.

Table 4 shows the linear regression analysis between retinal tortuosity and DR severity. After adjustment for age and sex, arteriolar and venular tortuosity values of diabetic patients with moderate NPDR, severe NPDR and PDR were significantly higher than that of diabetic patients without DR (β : 0.77 and 3.88 in arterioles, respectively; β : 0.79 and 2.53 in venules, respectively; all $p < 0.05$). In multivariable-adjusted model, compared to diabetic patients without DR, arteriolar tortuosity significantly increased in diabetic patients with severe NPDR and PDR (β : 3.83 and $p < 0.05$) and venular tortuosity was significantly enlarged with the

TABLE 2. Univariable linear regression analysis of retinal arteriolar/venular tortuosity and diabetic risk factors.

Diabetic risk factors		Retinal arteriolar tortuosity ($\times 10^3$)		Retinal venular tortuosity ($\times 10^3$)	
		β (95% CI)	<i>p</i> value	β (95% CI)	<i>p</i> value
Sex	Male	Ref		Ref	
	Female	0.09(-0.44~-0.62)	0.751	-0.13(-0.52~-0.23)	0.524
Age		-0.04(-0.06~-0.02)	0.000	-0.02(-0.04~-0.07)	0.006
Duration		0.02(-0.02~-0.06)	0.396	0.01(-0.02~-0.04)	0.385
HbA _{1c}		0.06(-0.05~-0.17)	0.259	0.04(-0.04~-0.12)	0.377
Urine microalbuminuria	$\leq 1.9\text{mg/dL}$	Ref		Ref	
	$> 1.9\text{mg/dL}$	1.02(0.44~1.59)	0.001	0.43(-0.01~0.87)	0.053
Urinary albumin /creatinine ratio	≤ 30	Ref		Ref	
	> 30	1.21(0.60~1.81)	0.000	0.99(0.54~1.44)	0.000
DR severity	R0(No DR)	Ref		Ref	
	R1(Mild NPDR)	0.29(-0.35~-0.93)	0.372	0.34(-0.14~-0.83)	0.162
	R2(Moderate NPDR)	0.36(-0.33~1.06)	0.304	0.58(0.06~1.10)	0.029
	R3(Severe NPDR and PDR)	3.53(2.45~4.62)	0.000	2.34(1.53~3.16)	0.000

HbA_{1c}: glycated hemoglobin

TABLE 3. Multivariable linear regression analysis of retinal arteriolar/venular tortuosity and diabetic risk factors.

Diabetic risk factors	Retinal arteriolar tortuosity ($\times 10^3$)				Retinal venular tortuosity ($\times 10^3$)			
	Model 1		Model 2		Model 1		Model 2	
	β (95%CI)	<i>p</i> value	β (95%CI)	<i>p</i> value	β (95%CI)	<i>p</i> value	β (95%CI)	<i>p</i> value
Age	-0.05 (-0.07~-0.03)	0.000	-0.05 (-0.07~-0.02)	0.000	-0.02 (-0.04~-0.01)	0.008	-0.02 (-0.04~-0.01)	0.013
Urine microalbuminuria	$\leq 1.9\text{mg/dL}$	Ref	Ref		Ref		Ref	
	$> 1.9\text{mg/dL}$	0.96 (0.39~1.53)	0.001	0.10 (-0.80~1.01)	0.826	0.38 (-0.06~0.81)	0.091	-0.63 (-1.30~-0.05)
Urinary albumin /creatinine ratio	≤ 30	Ref	Ref		Ref		Ref	
	> 30	1.19 (0.60~1.78)	0.000	1.17 (0.21~2.13)	0.017	0.96 (0.52~1.41)	0.000	1.42 (0.70~2.13)

Model 1 was adjusted for age and sex.

Model 2 was adjusted for age, sex, duration of diabetes, LDL, HDL, HbA_{1c}, urine microalbuminuria and urinary albumin/creatinine ratio.

HbA_{1c}: glycated hemoglobin; LDL: low density lipoprotein; HDL: high density lipoprotein.

increasing DR severity of moderate NPDR, severe NPDR and PDR (β : 0.77 and 2.31, respectively; both $p < 0.05$). Thus, diabetic patients with severe NPDR and PDR were more likely to suffer from a larger tortuosity of both arterioles and venules, whereas those with moderate NPDR were more likely to suffer from larger tortuosity of venules only. In addition, it can be found in Fig. 3 that arteriolar and venular tortuosity increased with increasing DR severity, which was in good agreement with the statistical analysis results in Table 4.

Table 5 shows the logistic regression analysis between DR severity with retinal arteriolar and venular tortuosity, respectively. DR severity was significantly associated with increased arteriolar and venular tortuosity in both models. Furthermore, in model 1 adjusted for age and sex, diabetic patients with moderate NPDR, severe NPDR and PDR were more likely to accompany with raising arteriolar

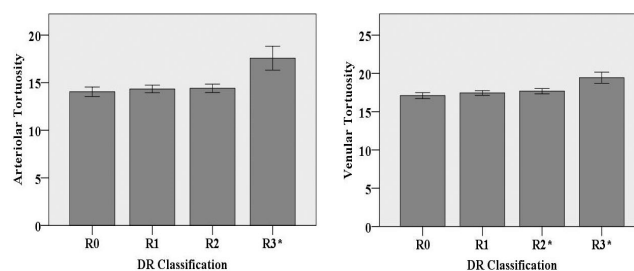


FIGURE 3. Relationships between arteriolar/venular tortuosity and DR severity. * $p < 0.05$ versus diabetic patients without retinopathy. R0: No DR, R1: Mild NPDR, R2: Moderate NPDR, R3: Severe NPDR and PDR.

and venular tortuosity (OR: 1.11 and 1.57 for arteriolar, 1.21 and 1.75 for venular, respectively; all $p < 0.05$). In model 2 adjusted for age, sex, duration of diabetes, LDL, HDL, HbA_{1c}, urine microalbuminuria and urinary

TABLE 4. Multivariable linear regression analysis of retinal arteriolar/venular tortuosity and DR severity.

Groups	N	Mean	Model 1		Model 2	
			β (95%CI)	<i>p</i> value	β (95%CI)	<i>p</i> value
Retinal arteriolar tortuosity ($\times 10^3$)						
R0(No DR)	122	14.0	Ref		Ref	
R1(Mild NPDR)	200	14.3	0.26 (-0.37~0.88)	0.414	0.24(-0.46~0.94)	0.501
R2(Moderate NPDR)	139	14.4	0.77(0.08~1.46)	0.029	0.46(-0.32~1.24)	0.244
R3(Severe NPDR and PDR)	34	17.6	3.88(2.82~4.94)	0.000	3.83 (2.55~5.10)	0.000
Retinal venular tortuosity ($\times 10^3$)						
R0(No DR)	122	17.1	Ref			
R1(Mild NPDR)	200	17.4	0.32(-0.16~0.80)	0.186	0.46 (-0.07~0.99)	0.088
R2(Moderate NPDR)	139	17.7	0.79(0.27~1.32)	0.003	0.77 (0.18~1.36)	0.011
R3(Severe NPDR and PDR)	34	19.4	2.53(1.72~3.34)	0.000	2.31 (1.34~3.27)	0.000

Model 1 was adjusted for age and sex.

Model 2 was adjusted for age, sex, duration of diabetes, LDL, HDL, HbA_{1c}, urine microalbuminuria and urinary albumin/creatinine ratio. HbA_{1c}: glycated hemoglobin; LDL: low density lipoprotein; HDL: high density lipoprotein.

TABLE 5. Logistic regression analysis between DR severity and retinal arteriolar/venular tortuosity.

	Model 1		Model 2	
	OR (95%CI)	<i>p</i> value	OR (95%CI)	<i>p</i> value
Retinal arteriolar tortuosity ($\times 10^3$)				
R0(No DR)	Ref		Ref	
R1(Mild NPDR)	1.04(0.95~1.13)	0.405	1.05(0.95~1.15)	0.333
R2(Moderate NPDR)	1.11(1.01~1.22)	0.028	1.06(0.95~1.18)	0.279
R3(Severe NPDR and PDR)	1.57(1.36~1.81)	0.000	1.58(1.32~1.88)	0.000
Retinal venular tortuosity ($\times 10^3$)				
R0(No DR)	Ref		Ref	
R1(Mild NPDR)	1.08(0.97~1.20)	0.183	1.12(0.99~1.27)	0.068
R2(Moderate NPDR)	1.21(1.06~1.37)	0.003	1.19(1.03~1.38)	0.017
R3(Severe NPDR and PDR)	1.75(1.44~2.12)	0.000	1.74(1.37~2.20)	0.000

Model 1 was adjusted for age and sex.

Model 2 was adjusted for age, sex, duration of diabetes, LDL, HDL, HbA_{1c}, urine microalbuminuria and urinary albumin/creatinine ratio. HbA_{1c}: glycated hemoglobin; LDL: low density lipoprotein; HDL: high density lipoprotein.

albumin/creatinine ratio, the associations between DR severity and venular tortuosity remained unchanged, whereas moderate NPDR was not associated with arteriolar tortuosity.

IV. DISSUSIONS

Based on the above results, both higher arteriolar and venular tortuosity values were associated with lower age, which is consistent with previous research by Sasongko *et al.* [26]. Although the exact mechanism of the relation between retinal vascular tortuosity and age remains unclear, it is suspected that the vessel integrity, stability and tortuosity alter more severely due to the abnormal vessel wall function (e.g. mis-regulation of tensile forces and vascular transmural pressure), especially for those diabetic patients with lower age [7], [27].

Furthermore, significant associations of larger retinal arteriolar and venular tortuosity with higher urinary

albumin/creatinine ratio were found, in which the urinary albumin/creatinine ratio has been employed as a sensitive biomarker for detecting renal function impairments for diabetic patients in the previous study [28]. Although the potential mechanisms between renal damage and retinal microvascular abnormalities are not fully elucidated, it might be attributed to the fact that the waste production removal function of kidney may partially fail due to microvascular abnormalities in diabetes, thus leading to a high urinary albumin/creatinine ratio [28], [29]. Interestingly, similar association between retinal vascular tortuosity and urinary albumin/creatinine ratio has been found in type 1 diabetes [30]. Therefore, it is expected that increased retinal vascular tortuosity can be used as a potential determinant for assessing the risk of renal diseases for both type 1 and type 2 diabetic patients.

Moreover, the tortuosity of retinal arterioles and venules showed a significant positive correlation with DR severity, which confirms the findings in the previous studies [7], [9], [31], [32]. In this study, it was found that diabetic patients with more tortuous venules were more likely to suffer from moderate NPDR, severe NPDR, and PDR, whereas those with more tortuous arterioles were more likely to suffer from severe NPDR and PDR. Although venules were more likely to suffer from morphology changes during DR development, tortuous arterioles were also observed in severe NPDR and PDR with statistical significance. This is in contrast to the conclusion of the previous study [7], [31], in which insignificant correlation was found between arteriolar tortuosity with severe NPDR or PDR. This can be attributed to the fact that the tortuosity information about the small branching vessels was missing in those previous studies [7], [31], which used only partial of the color fundus image, i.e. the biggest six arterioles and venules with diameter larger than $40\mu\text{m}$ within a local region of 0.5 to 2.0 disc diameters away from the disc margin. The retinal vessels become tortuous either locally and/or over an extended area during DR progression [11] and those small vessels were more likely to become tortuous during retinal neovascularization with more severe DR stage [12], [33], which was not fully considered in those previous studies. However, in our study, more precise global tortuosity was extracted from both main and branching vessels, in which the entire region of SLO image with good contrast and high optical resolution ($\sim 15\mu\text{m}$) was employed. Therefore, in our study, tortuosity extracted from the entire retinal image involving both main and branching vessels can provide a more substantial insight into the microvascular damage of retina during the DR progression and should be more convincing for DR diagnosis and assessment.


V. CONCLUSION

In summary, the association between the tortuosity with type 2 diabetes and DR severity was investigated based on a Chinese population-based cohort. Higher contrast retinal photographs taken by a confocal scanning laser ophthalmoscope were used to extract retinal arteriolar and venular tortuosity from both main and branching vessels, thus this study is with higher reliability. It was found that increased arteriolar and venular tortuosity extracted from main and branching arterioles, venules were associated with lower age and higher urinary albumin/creatinine ratio, which demonstrate its capability of identifying individuals with high-risk of diabetic renal disease. Furthermore, arteriolar and venular tortuosity increased with increasing DR severity, and diabetic patients with more tortuous venules were more likely to suffer from moderate NPDR, severe NPDR, and PDR, whereas those with more tortuous arterioles were more likely to suffer from severe NPDR and PDR, which indicates that retinal vascular tortuosity might be an remarkable indicator of the retinopathy severity. These results may provide additional insights on microvascular changes for diabetic retina and kidney diseases.

REFERENCES

- [1] NCD Risk Factor Collaboration (NCD-RisC), "Worldwide trends in diabetes since 1980: A pooled analysis of 751 population-based studies with 4.4 million participants," *Lancet*, vol. 387, no. 10027, pp. 1513–1530, Apr. 2016.
- [2] F. B. Hu, "Globalization of diabetes: The role of diet, lifestyle, and genes," *Diabetes Care*, vol. 34, no. 6, pp. 1249–1257, Jun. 2011.
- [3] Y. Xu, "Prevalence and control of diabetes in Chinese adults," *J. Amer. Med. Assoc.*, vol. 310, no. 9, p. 948, Sep. 2013.
- [4] N. Cho, J. Shaw, S. Karuranga, Y. Huang, J. Da Rocha Fernandes, A. Ohlrogge, and B. Malanda, "IDF diabetes atlas: Global estimates of diabetes prevalence for 2017 and projections for 2045," *Diabetes Res. Clin. Pract.*, vol. 138, pp. 271–281, Apr. 2018.
- [5] T. Y. Wong, "Guidelines on diabetic eye care: The international council of ophthalmology recommendations for screening, follow-up, referral, and treatment based on resource settings," *Ophthalmology*, vol. 125, no. 10, pp. 1608–1622, Oct. 2018.
- [6] A. E. Kiely, "Computer-assisted measurement of retinal vascular width and tortuosity in retinopathy of prematurity," *Arch. Ophthalmol.*, vol. 128, no. 7, p. 847, Jul. 2010.
- [7] M. B. Sasongko, T. Y. Wong, T. T. Nguyen, C. Y. Cheung, J. E. Shaw, and J. J. Wang, "Retinal vascular tortuosity in persons with diabetes and diabetic retinopathy," *Diabetologia*, vol. 54, no. 9, pp. 2409–2416, Sep. 2011.
- [8] M. B. Sasongko, T. Y. Wong, T. T. Nguyen, C. Y. Cheung, J. E. Shaw, R. Kawasaki, E. L. Lamoureux, and J. J. Wang, "Retinal vessel tortuosity and its relation to traditional and novel vascular risk markers in persons with diabetes," *Current Eye Res.*, vol. 41, pp. 1–7, Jun. 2015.
- [9] C. Y.-L. Cheung, E. Lamoureux, M. K. Ikram, M. B. Sasongko, J. Ding, Y. Zheng, P. Mitchell, J. J. Wang, and T. Y. Wong, "Retinal vascular geometry in asian persons with diabetes and retinopathy," *J. Diabetes Sci. Technol.*, vol. 6, no. 3, pp. 595–605, May 2012.
- [10] W. E. Hart, M. Goldbaum, B. Côté, P. Kube, and M. R. Nelson, "Measurement and classification of retinal vascular tortuosity," *Int. J. Med. Inform.*, vol. 53, nos. 2–3, pp. 239–252, Feb. 1999.
- [11] A. A. Kalitzeos, G. Y. Lip, and R. Heitmar, "Retinal vessel tortuosity measures and their applications," *Exp. Eye Res.*, vol. 106, pp. 40–46, Jan. 2013.
- [12] G. S. Ramlugun, V. K. Nagarajan, and C. Chakraborty, "Small retinal vessels extraction towards proliferative diabetic retinopathy screening," *Expert Syst. Appl.*, vol. 39, no. 1, pp. 1141–1146, Jan. 2012.
- [13] C. Y.-L. Cheung, Y. Zheng, W. Hsu, M. L. Lee, Q. P. Lau, P. Mitchell, J. J. Wang, R. Klein, and T. Y. Wong, "Retinal vascular tortuosity, blood pressure, and cardiovascular risk factors," *Ophthalmology*, vol. 118, no. 5, pp. 812–818, May 2011.
- [14] S. Zoungas, M. Woodward, Q. Li, M. E. Cooper, P. Hamet, S. Harrap, S. Heller, M. Marre, A. Patel, N. Poulter, B. Williams, and J. Chalmers, "Impact of age, age at diagnosis and duration of diabetes on the risk of macrovascular and microvascular complications and death in type 2 diabetes," *Diabetologia*, vol. 57, no. 12, pp. 2465–2474, Dec. 2014.
- [15] C. Wilkinson, F. L. Ferris, R. E. Klein, P. P. Lee, C. D. Agardh, M. Davis, D. Dills, A. Kampik, R. Pararajasegaram, and J. T. Verdager, "Proposed international clinical diabetic retinopathy and diabetic macular edema disease severity scales," *Ophthalmology*, vol. 110, no. 9, pp. 1677–1682, Sep. 2003.
- [16] B. Dashtbozorg, J. Zhang, S. Abbasi-Sureshjani, F. Huang, and B. M. T. H. Romeny, "Retinal health information and notification system (RHINO)," *Proc. SPIE, Med. Imag.*, vol. 10134, Mar. 2017, Art. no. 1013437.
- [17] J. Zhang, E. Bekkers, S. Abbasi, B. Dashtbozorg, and B. T. H. Romeny, "Robust and fast vessel segmentation via Gaussian derivatives in orientation scores," in *Proc. Int. Conf. Image Anal. Process.*, Genova, Italy, Sep. 2015.
- [18] J. Zhang, B. Dashtbozorg, E. Bekkers, J. P. W. Pluim, R. Duits, and B. M. T. H. Romeny, "Robust retinal vessel segmentation via locally adaptive derivative frames in orientation scores," *IEEE Trans. Med. Imag.*, vol. 35, no. 12, pp. 2631–2644, Dec. 2016.
- [19] E. J. Bekkers, J. Zhang, R. Duits, and B. M. T. H. Romeny, "Curvature based biomarkers for diabetic retinopathy via exponential curve fits in SE(2)," in *Proc. Ophthalmic Med. Image Anal. Second Int. Workshop*, Munich, Germany, May 2017.
- [20] E. Franken and R. Duits, "Crossing-preserving coherence-enhancing diffusion on invertible orientation scores," *Int. J. Comput. Vis.*, vol. 85, no. 3, pp. 253–278, Dec. 2009.

- [21] R. Duits and E. Franken, "Left-invariant parabolic evolutions on SE(2) and contour enhancement via invertible orientation scores. Part II: Non-linear left-invariant diffusions on invertible orientation scores," *Quart. Appl. Math.*, vol. 68, no. 2, pp. 293–331, Jun. 2010.
- [22] R. Duits, M. H. J. Janssen, J. Hannink, and G. R. Sanguinetti, "Locally adaptive frames in the roto-translation group and their applications in medical imaging," *J. Math. Imag. Vis.*, vol. 56, no. 3, pp. 367–402, Nov. 2016.
- [23] B. M. T. H. Romeny et al., "Brain-inspired algorithms for retinal image analysis," *Mach. Vis. Appl.*, vol. 27, no. 8, pp. 1117–1135, Nov. 2016.
- [24] R. Duits, M. Felsberg, G. Granlund, and B. T. H. Romeny, "Image analysis and reconstruction using a wavelet transform constructed from a reducible representation of the Euclidean motion group," *Int. J. Comput. Vis.*, vol. 72, no. 1, pp. 79–102, 2007.
- [25] J. Stockman, "Risk of microalbuminuria and progression to macroalbuminuria in a cohort with childhood onset type 1 diabetes: Prospective observational study," *Yearbook Pediatrics*, vol. 2010, pp. 464–466, Jan. 2010.
- [26] M. B. Sasongko, J. J. Wang, K. C. Donaghue, N. Cheung, P. Benitez-Aguirre, A. Jenkins, W. Hsu, M.-L. Lee, and T. Y. Wong, "Alterations in retinal microvascular geometry in young type 1 diabetes," *Diabetes Care*, vol. 33, no. 6, pp. 1331–1336, Jun. 2010.
- [27] H.-C. Han, "Twisted blood vessels: Symptoms, etiology and biomechanical mechanisms," *J. Vas. Res.*, vol. 49, no. 3, pp. 185–197, 2012.
- [28] T. Karar, "Assessment of microalbuminuria and albumin creatinine ratio in patients with type 2 diabetes mellitus," *J. Natural Sci., Biol., Med.*, vol. 6, no. 3, pp. 89–92, Aug. 2015.
- [29] T. Y. Wong, "Retinal microvascular abnormalities and renal dysfunction: The atherosclerosis risk in communities study," *J. Amer. Soc. Nephrol.*, vol. 15, no. 9, pp. 2469–2476, Sep. 2004.
- [30] P. Z. Benitez-Aguirre, M. B. Sasongko, M. E. Craig, A. J. Jenkins, J. Cusumano, N. Cheung, T. Y. Wong, and K. C. Donaghue, "Retinal vascular geometry predicts incident renal dysfunction in young people with type 1 diabetes," *Diabetes Care*, vol. 35, no. 3, pp. 599–604, Mar. 2012.
- [31] M. B. Sasongko, T. Y. Wong, K. C. Donaghue, N. Cheung, A. J. Jenkins, P. Benitez-Aguirre, and J. J. Wang, "Retinal arteriolar tortuosity is associated with retinopathy and early kidney dysfunction in type 1 diabetes," *Amer. J. Ophthalmol.*, vol. 153, no. 1, pp. 176.e1–183.e1, Jan. 2012.
- [32] D. L. Weiler, C. B. Engelke, A. L. O. Moore, and W. W. Harrison, "Arteriole tortuosity associated with diabetic retinopathy and cholesterol," *Optometry Vis. Sci.*, vol. 92, no. 3, pp. 384–391, Mar. 2015.
- [33] N. B. A. Mustafa, W. M. D. W. Zaki, A. Hussain, and J. C. Hamzah, "A study of retinal vascular tortuosity in diabetic retinopathy," in *Proc. Int. Conf. Adv. Electr., Electron. Syst. Eng. (ICAEEES)*, Putrajaya, Malaysia, Nov. 2016.




RUNYU DU received the bachelor's and master's degrees from China Medical University, China. She is currently with the Department of Endocrinology, Shengjing Hospital, China Medical University. Her research interest includes diabetes and its complications diagnosis.



DIBANDA S. ANNICK received the bachelor's degree from the University of Yaounde I. She is currently pursuing the master's degree with the College of Medicine and Biological Information Engineering, Northeastern University, China. Her research interest includes vessels segmentation and analysis on retinal image.



SHUO CHEN received the bachelor's degree from Shanghai Jiao Tong University, China, the master's degree from Heidelberg University, Germany, and the Ph.D. degree from the School of Chemical and Biomedical Engineering, Nanyang Technological University, Singapore. He is currently an Associate Professor with the College of Medicine and Biological Information Engineering, Northeastern University, China. His research interest includes fast spectroscopic imaging in biomedical applications.



SHANSHAN ZHU received the master's degree from the College of Sciences, Northeastern University, China, where she is currently pursuing the Ph.D. degree with the College of Medicine and Biological Information Engineering. Her research interests include Raman spectroscopy imaging in biomedical applications, and diabetes and complications analysis based on biomedical engineering technology.



HENAN LIU received the bachelor's and master's degrees from China Medical University, China, and the Ph.D. degree from the Ophthalmology College, China Medical University. He is currently with the Department of Ophthalmology, Shengjing Hospital, China Medical University. His research is focused on vitreoretinal diseases clinical and basic research.



WEI QIAN received the B.Sc. and M.Sc. degrees from the Nanjing University of Telecommunications, China, in 1982 and 1985, respectively, and the Ph.D. degree in biomedical engineering from Southeast University, Nanjing, in 1990. From 1990 to 1991, he was doing his postdoctoral research training at the Department of Electrical Engineering, University of Notre Dame, South Bend, Indiana. From 1991 to 1993, he was continuing his postdoctoral research training at the Department of Radiology, College of Medicine, University of South Florida, where he was an Assistant Professor, from 1993 to 2000. From 2001 to 2008, he was with the Moffitt Cancer Center, Department of Interdisciplinary Oncology, College of Medicine, University of South Florida. Since 2008, he was a Professor with the Department of Electrical and Computer Engineering, College of Engineering, The University of Texas at El Paso. He is also the Director of Medical Imaging Informatics Laboratory. His research interests include medical imaging informatics, biomedical imaging, and molecular imaging biomarker analysis.

...