

Received September 17, 2019, accepted September 29, 2019, date of publication October 11, 2019, date of current version October 24, 2019.

Digital Object Identifier 10.1109/ACCESS.2019.2946689

# Diabetic Vascular Damage: Review of Pathogenesis and Possible Evaluation Technologies

SERGEJ SOSUNKEVIČ<sup>1</sup>, ANDRIUS RAPALIS<sup>1</sup>, MINDAUGAS MAROZAS<sup>1</sup>, JONAS ČEPONIS<sup>2,3</sup>, AND ARŪNAS LUKOŠEVIČIUS<sup>1</sup>

<sup>1</sup>Biomedical Engineering Institute, Kaunas University of Technology, 44249 Kaunas, Lithuania

<sup>2</sup>Institute of Endocrinology, Lithuanian University of Health Sciences, 44307 Kaunas, Lithuania

<sup>3</sup>Department of Endocrinology, Lithuanian University of Health Sciences, 44307 Kaunas, Lithuania

Corresponding author: Arūnas Lukoševičius (arunas.lukosevicius@ktu.lt)

This work was supported by the Research Council of Lithuania under Grant S-MIP-19-8.

**ABSTRACT** Diabetes mellitus (DM) is a rapidly increasing problem in health care worldwide: recent forecast indicates that the number of DM patients will rise to 640 million by 2040. Vascular damage is associated with severe complications, including cardiac neuropathy and limb amputation. Therefore, early prediction of diabetic vascular damage using advanced technologies is an important challenge because timely preventive and therapeutic measures could diminish the risk of development and burden of complications. The aim of the article is to provide a review of the initial stages of vascular damage and main mechanisms for development, as well as appropriate modern technologies for prediction and diagnosis. The manuscript provides an overview of interrelated vascular damage mechanisms influenced by diabetes, along with a review of possible technologies for early prediction and diagnosis. A comparative analysis of technologies appropriate for particular issues of prediction is summarised in the discussion.

**INDEX TERMS** Arterial stiffness and atherosclerosis, diabetes mellitus vascular complications, endothelial dysfunction, evaluation technologies.

## I. INTRODUCTION

Diabetes mellitus (DM) is a major health care challenge globally. Morbidity of DM is increasing [1] and recently has reached an epidemic level [2], [3]. Long-term forecasts indicate that a number of DM patients will rise to 640 million by 2040 [4]. The age of DM onset is decreasing, and more young people (including children) have DM diagnosis [5]. A study has shown that about a third of people (33% of men and 39% of women) born in 2000 in the United States have a high risk of DM [6].

DM is a metabolic disorder and a vascular disease. The majority (85-95%) of DM cases is type 2 diabetes mellitus (T2DM) [7]. The diagnosis of T2DM is often overlooked until the advanced stage due to non-specific symptoms [8]. Metabolic derangement affects and damages entire body, but it is the effects on the cardiovascular system that result in majority of unfavourable outcomes [8], [9]. Elevated plasma

glucose levels and insulin resistance lead to macrovascular damage, and the risk of vascular complications may be increased years before DM diagnosis is established [8]. An elevation in glycosylated haemoglobin of 1% increases the risk of peripheral arterial disease by 28% [10]. Therefore, DM is a major and independent risk factor of cardiovascular disease and complications [11]. No wonder that cardiovascular disease is the main cause of death for DM patients [12]. These complications occur in 30-40% of DM cases [13]; moreover, additional 12-63.6% of those are asymptomatic atherosclerosis [14]. The progression rate of coronary vascular atherosclerosis is multiple times faster when glucose tolerance is impaired [15]. It is well-known that vascular disorder is the main mechanism of evolving disease for patients with DM [16].

Therefore, there is an unmet need for new methods and technologies to predict cardiovascular risks caused by DM reliably. Such methods should help to evaluate the interrelated dynamic changes of endothelial dysfunction (ED) [17], vascular stiffness, calcification, and atherosclerosis (ATS).

The associate editor coordinating the review of this manuscript and approving it for publication was Yongtao Hao.

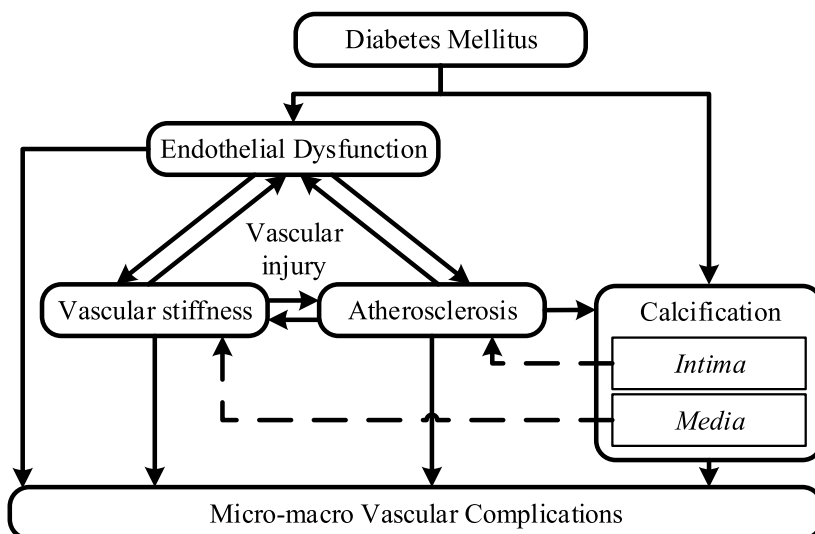


FIGURE 1. Mechanisms of DM induced vascular micro-macro complications.

These methods should preferably be reproducible, affordable, non-invasive or minimally invasive, unobtrusive, and suitable for screening. They should satisfy high technological requirements of safety, sensitivity and accuracy, which are needed for detection of minimal early-stage changes [18] and should allow dynamic monitoring of long-lasting vascular damage. Although there are a lot of articles dealing with the pathogenesis of diabetes and development of complications, there is a lack of reviews relating the early stages of complication development with the existing and emerging advanced evaluation methods and technologies. This article aims to overview main mechanisms of vascular impairment caused by diabetes mellitus (from endothelial dysfunction to atherosclerosis and vascular complications), along with diagnostic methods and technological solutions used for early evaluation in each stage of damage. The main focus is on early organic and structural, rather than micromolecular changes, showing all comorbid complications together with possible evaluation methods enabled by the evolving technologies. Chapters of the paper are consecutively devoted to the particular mechanisms of evolving vascular damage caused by DM - from endothelial dysfunction to more advanced stages of early damage together with diagnostic opportunities and related technologies applicable at each stage of pathology.

## II. MAIN STAGES OF EARLY VASCULAR DAMAGE

The pathogenesis of diabetes and complications of the vascular system are closely related. Main interrelated mechanisms of vascular pathogenesis in T2DM are shown in Fig. 1. Insulin resistance typical for T2DM evolves along with progressive endothelial dysfunction until atherosclerosis develops [19]. Hence, endothelial dysfunction could be considered as the first stage of evolving atherosclerosis [16]. In general, mechanisms of atherosclerosis development in DM case can be divided into three relative phases [20]:

- Endothelial dysfunction;
- Increased arterial stiffness;
- Intima-media calcification.

To predict early vascular complications, the time interval from the beginning of glycaemic impairment (including pre-diabetes) to the development of early vascular damage is essential. It should be pointed out that aetiology of vascular complications and causality of pathological stages is highly complicated. The simplified diagram in Fig. 1 is presented mainly for the classification of applicable methods and technologies. Stages of vascular damage and possible diagnostic methods are described in the sections below.

## III. DEVELOPMENT OF ENDOTHELIAL DYSFUNCTION AND ITS EVALUATION METHODS

Healthy endothelium is a dynamic organ which: 1) regulates vascular tone (in response to various stimuli) [21]; 2) ensures vascular perfusion and healthy vessel integrity, growth, and remodelling; 3) inhibits formation of thrombi [22]; 4) plays a vital role in metabolism, tissue growth, immune system, angiogenesis, haemostasis, cell adhesion, and vascular permeability. The overall vascular tone and blood fluidity highly depend on endothelium, which also influence perfusion and inflammatory responses [23]. However, these functions are impaired with development of insulin resistance or DM [24].

Endothelial dysfunction consists of many complex mechanisms. Persistent hyperglycaemia augments oxidative stress, changes the function and metabolism of endothelium; those changes lead to vascular injury [25], vascular inflammation [26], and development of ED [25]. Etiopathogenesis of ED in DM patients is somewhat different. In the presence of metabolic syndrome and insulin resistance, the ED develops in early stages - it can be observed several years before T2DM is diagnosed and the main alteration of endothelium is only functional [23], which is specific to DM [27].

ED is a systemic pathological state described as an imbalance between endothelial production of vasodilative and vasoconstrictive agents. ED is a failure in appropriate dilative response under proper stimuli of endothelial vasodilators in arteries and arterioles [28], which also leads to increased vasoconstriction and stiffness of the artery [29]. Endothelium may also influence the elastic properties of arterial walls that directly influence the vascular tone [30]. In general, ED is a disorder of vascular homeostasis [31] and an early signal of atherosclerosis [16], [32].

For a long time, an endothelial dysfunction (a significant indicator of vascular disease) did not receive adequate attention as the primary cause of cardiovascular diseases and their complications for DM patients [32]. The investigation of endothelial function has a prognostic value when detecting or predicting cardiovascular diseases such as myocardial infarction, peripheral vascular diseases, and stroke [33], [34]. Therefore, early identification of endothelial dysfunction can be key to diagnosing asymptomatic cardiovascular diseases [16]. Primary non-invasive methods for detecting endothelial dysfunction are:

- Photoplethysmography (PPG) is an optically recorded blood volume changes in a microvascular bed of tissue. It has many modifications and allows to evaluate perfusion of the tissues [35], vasomotor activity [36], and the state of the autonomic nervous system [7], [36]. Application of PPG method for ED has several modifications:
  - 1) PPG, in conjunction with the post-occlusive reactive hyperaemia (a custom-designed clamping method), allows evaluation of the endothelial function [37] and metabolic syndrome [7]. The method of examination of forearm blood flow is simple, well-tolerated, and easily reproducible [21].
  - 2) Pulse contour analysis (PCA) is a PPG pulse wave morphology-based method, quite accurate and relatively cheap - a fingertip photoplethysmogram waveform is analysed. The method detects morphological changes of finger probe photoplethysmogram signal waveform that respond to endothelium-dependent and independent vasodilators. The portability and affordability of devices and technique make this method attractive in screening and detecting early endothelial dysfunction to prevent cardiovascular disease [38].
- Fingertip peripheral artery tonometry measures the pulsatile volume changes in latex air cuffs that are sensed by the inflating device. Pulsatile volume changes alter the pressure in the cuffs which is sensed by transducers and expressed as reactive hyperaemia index which is expressed as a ratio between reactive hyperaemic responses to basal flow and indexed to the contralateral control arm [21]. Fingertip peripheral artery tonometry was suggested as an evaluation method of microvascular function. During the examination, an amplitude of finger arterial blood pulse wave before and during hyperaemia is evaluated [39].
- The ultrasound (US) can measure changes of the arterial lumen (B-scan technologies), blood flow (Doppler technologies), and a response to reactive hyperaemia [21]. The US, in conjunction with the reactive hyperaemia, allows evaluation of vascular stress and dilatation [39], which are related to permanent hyperglycaemia and endothelial dysfunction. Endothelial function can be evaluated by infusing specific vasodilator (e.g., acetylcholine) into the coronary, forearm, or peripheral circulation [21], recording changes of conduit vessel diameter using quantitative angiography and blood flow by intracoronary Doppler [21], [40].  
The specific method of US is a flow-mediated dilation (FMD), which measures a change in diameter of the brachial artery using high-resolution ultrasound [21]. Since arterial vasodilatation occurs in response to the shear stress produced by increased blood flow, it is a good biomarker of endothelial function. FMD is widely used for large population trials. Nevertheless, usually, for assessing FMD, it is required to perform up to 5 min ischemia on the forearm in supine position. The procedure requires additional time and a skilled operator. The method is applicable for adults and children, also in conjunction with magnetic resonance imaging (MRI) [40]. Although MRI is less operator dependent and, unlike US, allows assessment of peripheral and central endothelial function, it is rather expensive and less accessible method. MRI may also be used for the quantitative function of coronary artery endothelial analysis. The main benefits are significant contrast of soft tissues, excellent spatial resolution and ability to quantitatively evaluate bloodstream speed and flow [39].
- Laser speckle contrast imaging is a specific high-resolution optical method which allows rapid evaluation of microcirculation within the skin [41] and perfusion within other thin superficial layers of tissue [17] such as retina. It allows direct measurement of the microvascular system [42], [43], evaluate retinal vascular spasms or vascular dilation (an early sign of hyperglycaemia and ED) [43].

Although there are many methods for evaluation of different pathobiological aspects of endothelial function, the most suitable method that would be pre-clinical, non-invasive, efficient, reliable, inexpensive and easily performed is yet to be developed [40]. Evaluation of endothelial function using vasodilators along with quantitative angiography supplemented with Doppler blood flow measurements is a “gold standard” [39]. However, this method is of limited value in premenopausal women due to endothelial function fluctuation related to menstrual cycle [38]. Among the most popular real-world methods, PPG and US based ones are prevailing.

#### IV. DEVELOPMENT OF ARTERY STIFFNESS AND ITS EVALUATION METHODS

Arterial stiffness develops with age; while it may be predisposed by other diseases, it is highly associated with

DM [44], [45] and atherosclerosis [46]. Arterial stiffness can be one of the most important parameters binding diabetes with increased risk of cardiovascular diseases [47]. Besides, there is plenty of evidence indicating that increased arterial stiffness appears in early micro and macrovascular DM pathogenesis [48]. Diabetes increases stiffness of arteries through pathological variations such as increased oxidative stress, chronic endothelial inflammation, increased sympathetic tone, structural changes of elastin and collagen within the artery wall [47]. The elasticity of large artery walls mainly depends on the ratio of elastin and collagen content. It gradually decreases towards periphery. The elasticity is decreased by rising blood pressure and with the increase of non-elastic fibres of collagen. Decreased elasticity or increased arterial stiffness is a gradual process and a result of elastomeric degeneration [49]. Therefore, arterial stiffness is an important early marker of vascular atherosclerosis [50] and is an independent predictor of cardiovascular events [50], [51]. Arterial stiffness highly correlates with insulin resistance and endothelial dysfunction [52]. All these mechanisms form a vicious cycle. In early age (<40 years), increased vascular stiffness is associated with a risk of cardiovascular and peripheral vascular diseases [53], especially in DM [50]. Certain micro and macrovascular complications for DM patients can be evaluated by measuring changes of vascular stiffness [45] since biomechanical properties of arteries and consequently, their functionality depends on stiffness, calcification, and formation of plaque [54]. The most common quantitative markers of arterial stiffness are the intima-media thickness, pulse wave velocity (PWV), and cross-sectional distensibility [51]. Increased vascular stiffness elevates PWV and reduces reflection of this wave from the vascular system. Also, it causes increased heart rate and left ventricular hypertrophy [46] being a strong indicator of cardiovascular risk independently associated with mortality of DM patients [45]. An analysis of PWV, which increases with development of arterial stiffness is considered a “gold standard” for vascular stiffness determination. The most commonly used methods for assessing vascular stiffness are:

- Pulse wave velocity is measured by calculating the time lag between systolic pressure pulses recorded in two distant points of an artery, but the most popular method is by the use of a time lag between R peak of an electrocardiogram and a pulse of fingertip photoplethysmogram [55]. The shape (morphology) of the pulses also is informative. The morphology is defined by pressure wave reflections from artery branching and impedance mismatch sites. The morphology is used in pulse contour analysis (PCA) which gives information about arterial stiffness and vessel tone, and is independent of the investigator and is well accepted by patients, although currently, there is no standard protocol [48]. The difference between the first (incident) and second (reflected) wave peaks are expressed as augmentation index. This index is a measure of aortic pressure pulse reflection from the vascular periphery. PWV could be measured

by using ultrasound Doppler or MRI [21]. Besides, morphology-based methods such as peripheral arterial tonometry, central blood pressure, and augmentation index are applied [56]. Peripheral arterial tonometry is a version of measuring direct and reflected arterial waves by ultrasonographic methods. Found changes directly correlate to vascular stiffness [57].

- Modern ultrasound scanners that are available in most clinical settings allow inspecting motion of internal and middle layers of large arteries not only in radial but also in the longitudinal direction, which depends on elastic properties of arteries [51]. Doppler echocardiography allows evaluating arterial stiffness by using changes in blood volume and pressure relationships [58].

Despite the high diagnostic value, arterial stiffness evaluation has not been assessed in routine clinical practice due to some technical difficulties and probably due to the influence of vasoconstriction on the stiffness [59]. However, the potential of traditional markers such as PWV or morphological parameters of the pulse wave (PCA) remains underutilised [51], even though they have been long approved as reliable methods of artery stiffness evaluation. Although magnetic resonance imaging allows evaluating the stiffness by direct tracking of their expansion, the usage is highly limited by the price and limited resolution [52].

## V. DEVELOPMENT OF INTIMA AND MEDIA CALCIFICATION AND ITS EVALUATION METHODS

Permanent hyperglycaemia causes multiple changes in the intima and media of the vessels, which accelerates atherosclerosis [60]. The most noticeable change is an arterial calcification, which is typical for T2DM [61]. Vascular calcification is an evolving process which leads to arterial stiffness and ATS formation [62]. Two types of calcification specifically related to diabetes could be analysed separately [63].

- The first type of calcification (of the intima layer in the vicinity of lipid and cholesterol deposits within the endothelial monolayer). This calcification leads to vascular stenosis, occlusion, and additional calcification of ATS plaque. The calcification of the intima layer is associated with an early prediction of ATS [63].
- The second type of calcification (known as Mönckeberg's sclerosis). Present in media layer in the absence of lipid or cholesterol deposits [63]. It is an accumulation of mineral matter within vascular smooth muscle layer [61]. This calcification also increases vascular stiffness [64] and in DM is associated with an increased risk of nephropathy, retinopathy, limb amputation, and coronary artery disease [65].

Calcification of coronary artery correlates with a development of ATS plaques [18] and is one of the causes of high mortality for DM patients [63]. Due to the accumulation of calcium within vessels, it is possible to visualise vascular changes and indirectly assess vascular elasticity. Timely assessment of arterial calcification significantly improves

coronary outcomes [18]. Calcification almost always appears as a consequence of ATS [66]. The following methods can be used to assess vascular calcification:

- Intravascular ultrasound (IVUS) is an invasive “gold standard” method which allows evaluation of the calcification of coronary arteries with high sensitivity (90%) and specificity (100%) [67]. The colour-coded echogenicity corresponds to the damage of the blood vessels; for example, white colour shows a higher density of calcium [68].
- The ankle-brachial index (ABI) is a ratio of systolic arterial blood pressure and systolic brachial pressure. It is an accurate method for the detection of peripheral arterial disease [69] and arterial calcification [70]. For healthy blood vessels, ABI ranges from 1.00 to 1.40. If ABI is higher than 1.40, it indicates the potential vascular calcification. If ABI is less than 1.00, it indicates an increased risk of cardiovascular disease. ABI specificity is 96% for clinical assessment and 89% for asymptomatic phenomena [69]. However, in rare cases, thigh arteries can be damaged by cuff during measurement. For these reasons, there is some debate on the credibility and informativeness of this method [70].
- Computed tomography (CT) imaging allows to detect and assess calcified plaques of coronary arteries, aortic valve, and aorta [66]. However, non-contrast CT imaging has been largely superseded by usage of computed tomography angiography in clinical practice, which is limited to symptomatic patients. Meanwhile, coronary artery calcium (CAC) scoring is a relatively fast and accurate screening method. This technique has low radiation exposure, does not require intravenous contrast, is easy to interpret, and allows measurement of the amount (including volume and mass score) of calcium in the coronary arteries using ECG-gated non-contrast CT [71], [72]. Due to the cost, the suitability of this method for predictive screening is rather limited.

Advanced non-invasive imaging methods, such as CT, MRI, and digital angiography, are sensitive for arterial calcification assessment since they are based on the chemical composition of a tissue. However, these methods have limitations in usage in DM patients because conventional contrast materials may induce nephrotoxicity [70]. Additionally, CT and X-ray have been considered sub-optimal for screening purposes due to ionising radiation, yet recent technological advances, among others, have allowed to significantly decrease radiation exposure [73]. In specific cases an optical coherence tomography using direct access to the inner artery wall is used [67]. Although most of these methods have a high sensitivity and specificity for arterial calcification assessment, however (with and exception of an indirect ABI) require high-cost equipment, highly qualified operators and interpreters, and are not feasible for monitoring permanent dynamic changes.

## VI. ATHEROSCLEROSIS AND ITS EVALUATION METHODS

Atherosclerosis involves two processes: fatty degeneration (atherosis) and stiffening (sclerosis) of the arterial wall [74]. Atherosclerosis is a dynamic and progressive process which damages blood vessels. Patients with diagnosed DM have a higher risk of accelerating ATS [75], [76]. Endothelial dysfunction is the first element in the chain of damage, leading to injuries, thickening and stiffening of inner artery layers and thus induction of the ATS [16], [19], [77]. One of the pathological indications of early ATS is thickening of the intima layer [78]. ATS is a change of the thickness of tunica intima and tunica media, the innermost two layers of the wall of an artery [79]. Intima-media thickness (IMT) of the carotid artery is greater in DM patients [74]. IMT can be used for early identification of subclinical atherosclerotic disease [80]. Carotid IMT can be a predictor of multi-territory atherosclerosis [81]. ATS detected in a single vascular segment indicates potential damage in other segments [69]. Although ATS occurs in people without DM, however, in those with DM, the damage is multi-segmental, reciprocal [82] and diffusive and often starts distally [83]. ATS is characterised by a specific sequence of processes. The main phases of atherosclerosis formation are a fatty streak, fibrous plaque, and complicated lesion [84] which is the same for both people with and without DM. However, in long-term hyperglycaemia leads to accelerated development of ATS [83]. Late stages of ATS are characterised by rupture of intima, erosion, and plaque formation in vessel layers [85]. Atherosclerotic plaque develops as a reaction to local inflammation processes [86], and reparative processes in blood vessels [87]. The plaques can develop on one side of the blood vessel or in its entire radius [84]. This vascular damage can be characterised by vascular occlusion, plaque instability, and rupture. The size of ATS plaques allows determining the degree of vascular occlusion [84]. In the worst-case occlusive vascular damage may evolve to critical ischemia [69]. ATS is a major factor in developing chronic DM complications [26], and in each stage of ATS increases the risk of death [84]. Direct methods used to evaluate arteriosclerosis and atherosclerosis and their progression are presented in comparative usage priority order:

- The ultrasound is the most popular and somewhat reliable method which allows visualising vascular walls (e.g. carotid intima-media thickness) and ATS changes [18]. The US is widely used to diagnose carotid ATS for DM patients. Three leading ultrasound technologies are used to determine the ATS:

- 1) Ultrasonography (type B ultrasound imaging) has long been considered a “gold standard” to identify and assess changes of carotid ATS [88]. It allows assessing the thickness of intima and media layers of the carotid artery and even sub-clinical changes of ATS [89]. It provides information about the thickness of blood vessels walls, plaque, stenosis, and arterial remodelling [57].

Ultrasonography with additional contrast allows assessing the damage of intima and media layers and a degree of stenosis and occlusion of the vascular wall [90]. Ultrasonography, however, provides somewhat indirect information on systemic vascular status based on a limited “window” of a visible carotid vessel, does not provide information about inflammatory processes within the carotid artery [88] and is highly operator-dependent.

- 2) Ultrasonic duplex scanning (type B imaging combined with Doppler method) can directly visualise blood vessels and provide information about the thickness of the artery wall, together with the parameters of blood flow velocity and turbulence, in real-time and across vessel lumen [69].
  - 3) Intravascular ultrasound is invasive, however, allows high-resolution visualisation of vascular intima, media, and adventitia layers by using an internal probe and high-frequency ultrasound waves with accordingly increased resolution. Additionally very informative virtual histology can be used to evaluate the morphology of four different types of ATS plaques: fibre, fibro-fatty density, calcium, and necrotic core [68]. Despite a high informativity the usage is limited by complicated equipment, invasiveness and cost.
- Computed tomography angiography (CTA) has great potential for various applications, including the ability to evaluate vascular states in various vessels such as coronary heart artery, aorta, carotid, and other arteries [91]. CTA provides detailed information about location, degree, and characteristics of coronary ATS [92]. In recent years, this method has shown high reliability and allowed precisely estimation of coronary artery disease and an assessment of the coronary lumen [73], [93]. CTA also can be used for preprocedural planning in preparation for surgical treatment [91].
  - Magnetic resonance imaging in conjunction with black-blood method (the blood-flowing signal is suppressed) allows quantification of the endothelial function, thickness index of a coronary artery wall, arterial remodelling, and early coronary atherosclerosis [39]. In addition, it allows identification of the main features of atherosclerotic plaques such as fibrous cap, intra-plaque haemorrhage, neovascularization, and signs of inflammation. Furthermore, this method gains popularity as it allows identification of changes in biomechanical forces, which are related to the pathogenesis of plaque vulnerability [90].
  - Positron emission tomography (PET) is a nuclear imaging method that uses intravenous radioactive contrast materials that accumulate in the target tissues. The radio decay signals are detected externally and carry information about physiological parameters, including time-activity based kinetic models. PET method alone has a rather poor imaging resolution (4-5 mm);

therefore, it is co-registered with CT or MRI for accurate mapping of zones of interest and assessment of ATS. Also, due to ionising radiation, it is not sufficiently safe for screening purposes [78]. The advantage of the method is its very high sensitivity [94] in exploring various processes of ATS progression and plaque rupture [78].

- Optical coherence tomography allows high-resolution imaging and is among rear methods. It provides high precision quantitative analysis of cross-sectional images of the retina and choroid vessels [68]; it doubles as a means to detect and monitor subclinical ocular pathology [95]. Analysis of fundus even by relatively simple optical methods proves highly valuable in estimating ATS and other cardiovascular damage [96].
- Intracoronary near-infrared spectroscopy (NIRS) is an effective coronary imaging technique based on the detection of lipids within vessels. In contrast to optical coherence tomography, NIRS can be applied to vessels with blood present in the lumen [68] and for detection of atherosclerotic plaques. NIRS, in combination with IVUS, provides compositional information and structural information at the same time [97], however, is invasive and rather complicated to perform. Vascular inflammation can also be diagnosed by microwave radiometry based temperature of carotid ATS plaque [88].

In the long run, the ATS damage progresses, leading to narrowing of arteries, impaired blood flow, subsequent thrombosis, and development of acute syndromes such as stroke or myocardial infarction. In recent years, attention to the characterisation of coronary atherosclerosis has increased. CT angiography became an informative clinical common practice for the imaging of the heart and coronary arteries with increasing possibilities regarding improved temporal resolution, multi-slice operation and reduced radiation doses [73]. Additionally, this method can be combined with CAC score - a simple pre-CTA scan to allow for quantified calcification burden of the coronary arteries for streamlined clinical decision making [98]. MRI technology provides further information and may be useful in further assessing cardiac structural changes. The method does not expose patients to radiation, but it is more expensive and taxing to the patient. Among non-invasive methods for evaluation, both anatomical and functional parameters related to ATS increasing popularity gains ultrasound methods, and its modifications. Echography (B-scanning) gives a real-time image of pulsating vessels in real-time and together with M-scanning enable to measure the thickness of intima and media as well as fluctuation of pulsating arteries. Even more detailed information is obtained by intravascular ultrasound, which is used in special cases due to the invasiveness. Besides, Doppler method and ultrasound electrography enable estimate blood flow parameters, stenosis and blood turbulence as well as ATS plaques [40], [99]. Other non-invasive imaging techniques can be used for special needs to evaluate the morphological features of occlusions [69]. However, still very actual remains

the preclinical assessment of ATS for DM patients. Even assessment technologies for early age individuals are still in progress [40].

## VII. DISCUSSION AND CONCLUSION

Despite the best efforts, diabetes leads to a decreased life expectancy of five to ten years [100] due to micro and macro complications caused by long-term hyperglycaemia and other risk factors [101], [102]. Quality of life is also impaired, especially when chronic micro and macrovascular complications develop [100]. Early diagnosis of the disease, prediction of complications and their management are priorities in managing long-term consequences [75], [103]. Therefore, advanced predictive technologies play a significant role. However, the most clinically relevant question of what technology is the most appropriate at a particular stage of pathogenesis is yet to be answered. It is not possible to align unambiguously the timeline of DM induced cardiovascular complication pathogenesis with appropriate early diagnostic technologies since multiple pathological mechanisms are interrelated and usually overlap in time. Roughly, those stages could be divided into three groups: 1) early pre-clinical changes without observable clinical defects in function and in structure (potentially could be revealed by molecular-level methods or stress tests); 2) changes with clinical signs of the pathophysiological function, but without noticeable structural changes; and 3) changes when pathophysiological malfunction is accompanied by structural changes. The most prominent changes in the third group naturally are also easiest to diagnose and evaluate. Here ultrasound, MRI, and CT are the superior techniques for visualizing and providing structural information. Ultrasound is especially usable due to affordability and compactness with even pocket-sized modifications; it provides information about tissue density and elasticity, as well as tissue micro-motion and blood flow [104]. Methods of direct evaluation of vascular condition include evaluation of atherosclerotic load, the carotid intima-media thickness, etc. by using high-frequency US measurements. CT and MRI are much more expensive, require adequately trained technical and medical personnel and are mainly used in specialized centres.

In earlier stages, when structural damage is still absent, but functional cardiovascular pathology is already detectable (group two), functional evaluation technologies are applicable. For example, the most easily detectable change in dynamics is seen in brachial artery when assessing endothelium-dependent vasodilatation by ultrasound or by using invasive thermodilution methods [105]. Functional pathology could be evaluated by recording changes of microvascular blood supply by photoplethysmography. This optical method allows registration of blood perfusion in superficial tissues at any site of the body, including information about blood oxygenation [35]. Photoplethysmography, along with electrocardiography, may also be used for registration of pulse wave velocity and analysis of general vascular status through signal morphology [106]. Near-infrared

spectroscopy, a method which uses near-infrared radiation is helpful in functional analysis of blood supply to the brain and other tissues with the depth of several centimetres [107].

However, initial pathological deviations develop before visible functional changes can be detected [78]. More fundamental methods should be applied for the earliest group of changes at the onset of cardiovascular damage. By targeting specific molecules and metabolic processes with contrast materials, it is possible to achieve higher specificity in visualising fundamental cellular processes [78]. Lipoprotein-based contrast agents are generating significant interest in atherosclerosis field. The new “molecular visualisation” approach combined with US or MRI may bring a new perspective into early diagnosis. The molecular targeting of plaque formation could be effective in early detection of the developing disease and effective risk control. Molecular imaging of endothelial inflammation processes is under development and has shown promise in animal studies [108]. Those methods are rather complicated for clinical use but have high scientific value as they reveal very early mechanisms of the diabetic cardiovascular pathogenesis.

In the context of rapidly evolving technologies, it is reasonable to choose technologies that are appropriate for the particular purpose. Complex criteria are sensitivity to early pathological signs, suitability for non-invasive screening, cost, qualification of the personnel, and duration of the procedure, level of computerisation, consumables and other. Detailed and specific recommendations are out of the scope of the present article, and this could be considered as a limitation of the review. In each case, this choice is highly specific, a review presented in this article allows to point out some general observations:

- 1) The early diagnosis or even prediction of cardiovascular complications caused by DM is still a challenge. Majority of the technologies are suitable for the late stages of damage when functional and structural changes are already evident, however, by then means for complication prevention and treatment are of limited effectiveness. Therefore, methods and technologies for evaluation of epithelial dysfunction - an early mechanism of pathogenesis - a combination of photoplethysmography, arterial tonometry and ultrasound are highly promising due to affordability and reliability.
- 2) In practice, early stages of vascular damage could be revealed by appropriate screening methods. Unfortunately, usage of almost all described methods for screening is limited by moderate to high-cost equipment, operator- or interpreter- dependency, and limited ability to monitor dynamic changes in development of complications starting with early dysglycaemia to emergent ATS. Few approaches can be used for stiffness evaluation that would allow measurement of properties such as compliance, elasticity, and resistance to deformation, rate of return to the non-deformed state [105].

- 3) Non-invasive, unobtrusive and inexpensive technologies would be the most attractive for early diagnosis and screening. Emerging wearables, such as multimodal smartwatch [109] with integrated ECG, PPG and galvanic skin response signal and data processing shows promise for monitoring and screening.
- 4) Mostly all contemporary devices are capable of digital data processing and generating vast amount of valuable information. This includes ultrasound, MRI, CT, as well as long term wearable multimodal monitoring devices. The growing capacity of machine learning and artificial intelligence algorithms allows for complex use of data and knowledge [110].

Novel methods of early damage prediction would allow detecting vascular pathology in their initial stages, and this would allow early intervention to delay or prevent possible complications. Existing technologies provide a solid base for new smart multimodal solutions.

#### ACKNOWLEDGMENT

The authors express appreciation to Kaunas University of Technology and Lithuanian University of Life Sciences.

#### REFERENCES

- [1] G. Fagherazzi, G. Gusto, B. Balkau, M.-C. Boutron-Ruault, F. Clavel-Chapelon, and F. Bonnet, "Functional gastrointestinal disorders and incidence of type 2 diabetes: Evidence from the E3N-EPIC cohort study," *Diabetes Metabolism*, vol. 42, no. 3, pp. 178–183, Jun. 2016.
- [2] J. R. Nansseu, S.-J. N. Petnga, C. P. Atangana, A. S. Ossa, S. N. N. Sangong, P. Ebendeng, and J. J. Noubiap, "The general public's knowledge of diabetes mellitus: A cross-sectional study in Cameroon," *Primary Care Diabetes*, vol. 13, no. 2, pp. 97–105, Apr. 2019.
- [3] A. W. Stitt, T. M. Curtis, M. Chen, R. J. Medina, G. J. McKay, A. Jenkins, T. A. Gardiner, T. J. Lyons, H.-P. Hammes, R. Simó, and N. Lois, "The progress in understanding and treatment of diabetic retinopathy," *Prog. Retinal Eye Res.*, vol. 51, pp. 156–186, Mar. 2016.
- [4] G. Štiglic, N. Fijačko, A. Stožer, A. Sheikh, and M. Pajnikar, "Validation of the finnish diabetes risk score (FINDRISC) questionnaire for undiagnosed type 2 diabetes screening in the Slovenian working population," *Diabetes Res. Clin. Pract.*, vol. 120, pp. 194–197, Oct. 2016.
- [5] P. Balakumar, K. Maung-U, and G. Jagadeesh, "Prevalence and prevention of cardiovascular disease and diabetes mellitus," *Pharmacological Res.*, vol. 113, pp. 600–609, Nov. 2016.
- [6] D. R. Lally, C. P. Shah, and J. S. Heier, "Vascular endothelial growth factor and diabetic macular edema," *Surv. Ophthalmol.*, vol. 61, no. 6, pp. 759–768, Nov./Dec. 2016.
- [7] A. L. De Souza, G. A. Batista, and S. M. Alegre, "Assessment of insulin sensitivity by the hyperinsulinemic euglycemic clamp: Comparison with the spectral analysis of photoplethysmography," *J. Diabetes Complications*, vol. 31, no. 1, pp. 128–133, Jan. 2017.
- [8] F. M. Task, L. Ryden, P. J. Grant, S. D. Anker, C. Berne, F. Cosentino, and H. Huikuri, "ESC Guidelines on diabetes, pre-diabetes, and cardiovascular diseases developed in collaboration with the EASD: The task force on diabetes, pre-diabetes, and cardiovascular diseases of the European Society of Cardiology (ESC) and developed in collaboration with the European Association for the Study of Diabetes (EASD)," *Eur. Heart J.*, vol. 34, no. 39, pp. 3035–3087, Oct. 2013.
- [9] S. Madsbad, "Impact of postprandial glucose control on diabetes-related complications: How is the evidence evolving?" *J. Diabetes Complications*, vol. 30, no. 2, pp. 374–385, Mar. 2016.
- [10] L. Potier, C. A. Khalil, K. Mohammedi, and R. Roussel, "Use and utility of ankle brachial index in patients with diabetes," *Eur. J. Vascular Endovascular Surg.*, vol. 41, no. 1, pp. 110–116, Jan. 2011.
- [11] A. Kumar, S. K. Bharti, and A. Kumar, "Type 2 diabetes mellitus: The concerned complications and target organs," *Apollo Med.*, vol. 11, no. 3, pp. 161–166, Sep. 2014. [Online]. Available: <https://www.sciencedirect.com/science/article/pii/S0976001614000106>
- [12] Q. Zhao, X.-X. Wu, J. Zhou, and X. Wang, "Elevated plasma levels of copeptin linked to diabetic retinopathy in type 2 diabetes," *Mol. Cellular Endocrinology*, vol. 442, pp. 106–112, Feb. 2017.
- [13] E. Y. Choe, H. J. Wang, O. Kwon, K. J. Kim, B. S. Kim, B.-W. Lee, C. W. Ahn, B. S. Cha, H. C. Lee, E. S. Kang, and C. S. Mantzoros, "Variants of the adiponectin gene and diabetic microvascular complications in patients with type 2 diabetes," *Metabolism*, vol. 62, no. 5, pp. 677–685, May 2013.
- [14] J. Vouillarmet, M. Helfre, D. Maucort-Boulch, B. Riche, C. Thivolet, and C. Grange, "Carotid atherosclerosis progression and cerebrovascular events in patients with diabetes," *J. Diabetes Complications*, vol. 30, no. 4, pp. 638–643, 2016.
- [15] T. Nakayama, N. Komiya, M. Yokoyama, S. Namikawa, N. Kuroda, Y. Kobayashi, and I. Komuro, "Pioglitazone induces regression of coronary atherosclerotic plaques in patients with type 2 diabetes mellitus or impaired glucose tolerance: A randomized prospective study using intravascular ultrasound," *Int. J. Cardiol.*, vol. 138, no. 2, pp. 157–165, Jan. 2010.
- [16] R. M. Bruno, K. D. Reesink, and L. Ghiadoni, "Advances in the non-invasive assessment of vascular dysfunction in metabolic syndrome and diabetes: Focus on endothelium, carotid mechanics and renal vessels," *Nutrition, Metabolism, Cardiovascular Diseases*, vol. 27, no. 2, pp. 121–128, Feb. 2017.
- [17] A. S. de M. Matheus, E. L. S. Clemente, M. de L. G. Rodrigues, D. C. T. Valença, and M. B. Gomes, "Assessment of microvascular endothelial function in type 1 diabetes using laser speckle contrast imaging," *J. Diabetes Complications*, vol. 31, no. 4, pp. 753–757, Apr. 2017.
- [18] A. Gallino, M. Stuber, F. Crea, E. Falk, R. Corti, J. Lekakis, J. Schwitter, P. Camici, O. Gaemperli, M. Di Valentino, J. Prior, H. M. Garcia-Garcia, C. Vlachopoulos, F. Cosentino, S. Windecker, G. Pedrazzini, R. Conti, F. Mach, R. De Caterina, and P. Libby, "In vivo" imaging of atherosclerosis," *Atherosclerosis*, vol. 224, no. 1, pp. 25–36, Sep. 2012.
- [19] R. Dhana, K. S. S. Koundinya, T. Malati, and V. K. Kutala, "Endothelial dysfunction in type 2 diabetes mellitus," *Indian J. Clin. Biochem.*, vol. 31, no. 4, pp. 372–379, Oct. 2016.
- [20] I. Zavoreo, V. B. Kes, L. Čorić, and V. Demarin, "Breath holding index and arterial stiffness in evaluation of stroke risk in diabetic patients," *Perspect. Med.*, vol. 1, nos. 1–12, pp. 156–159, 2012.
- [21] C. N. Marti, M. Gheorghiu, A. P. Kalogeropoulos, V. V. Georgiopoulos, A. A. Quyyumi, and J. Butler, "Endothelial dysfunction, arterial stiffness, and heart failure," *J. Amer. College Cardiol.*, vol. 60, no. 16, pp. 1455–1469, Oct. 2012.
- [22] M. M. Hartge, T. Unger, and U. Kintscher, "The endothelium and vascular inflammation in diabetes," *Diabetes Vascular Disease Res.*, vol. 4, no. 2, pp. 84–88, Jun. 2007.
- [23] C. M. Sena, A. M. Pereira, and R. Seiça, "Endothelial dysfunction—A major mediator of diabetic vascular disease," *Biochimica et Biophysica Acta*, vol. 1832, no. 12, pp. 2216–2231, Dec. 2013.
- [24] D. Tousoulis, N. Papageorgiou, E. Androulakis, G. Siasos, G. Latsios, K. Tentolouris, and C. Stefanadis, "Diabetes mellitus-associated vascular inflammation: Novel circulating biomarkers and therapeutic approaches," *J. Amer. College Cardiol.*, vol. 62, no. 8, pp. 667–676, Aug. 2013.
- [25] V. Altbas, "Diabetes, endothelial dysfunction, and vascular repair: What should a diabetologist keep his eye on?" *Int. J. Endocrinology*, vol. 2015, Jan. 2015, Art. no. 848272.
- [26] J. Lu, G. Xiang, M. Liu, W. Mei, L. Xiang, and J. Dong, "Irisin protects against endothelial injury and ameliorates atherosclerosis in apolipoprotein E-Null diabetic mice," *Atherosclerosis*, vol. 243, no. 2, pp. 438–448, Dec. 2015.
- [27] M.-H. Hwang and S. Kim, "Type 2 diabetes: Endothelial dysfunction and exercise," *J. Exerc. Nutrition Biochem.*, vol. 18, no. 3, pp. 239–247, Sep. 2014.
- [28] G. K. Kolluru, S. C. Bir, and C. G. Kevil, "Endothelial dysfunction and diabetes: Effects on angiogenesis, vascular remodeling, and wound healing," *Int. J. Vascular Med.*, vol. 2012, Oct. 2012, Art. no. 918267.
- [29] P. Meagher, M. Adam, R. Civitarese, A. Bugyei-Twum, and K. A. Connelly, "Heart failure with preserved ejection fraction in diabetes: Mechanisms and management," *Can. J. Cardiol.*, vol. 34, no. 5, pp. 632–643, May 2018.
- [30] H. S. Lim and G. Y. H. Lip, "Arterial stiffness in diabetes and hypertension," *J. Hum. Hypertension*, vol. 18, no. 7, pp. 467–468, Feb. 2004.
- [31] E. Chang and J.-I. Abe, "Kinase-SUMO networks in diabetes-mediated cardiovascular disease," *Metabolism*, vol. 65, no. 5, pp. 623–633, May 2016.



- [32] A. A. M. Adly, E. A. Ismail, L. M. Tawfik, F. S. E. Ebeid, and A. A. S. Hassan, "Endothelial monocyte activating polypeptide II in children and adolescents with type 1 diabetes mellitus: Relation to micro-vascular complications," *Cytokine*, vol. 76, no. 2, pp. 156–162, Dec. 2015.
- [33] W. K. C. Leung, L. Gao, P. M. Siu, and C. W. K. Lai, "Diabetic nephropathy and endothelial dysfunction: Current and future therapies, and emerging of vascular imaging for preclinical renal-kinetic study," *Life Sci.*, vol. 166, pp. 121–130, Dec. 2016.
- [34] S. Podtaev, R. Stepanov, E. Smirnova, and E. Loran, "Wavelet-analysis of skin temperature oscillations during local heating for revealing endothelial dysfunction," *Microvascular Res.*, vol. 97, pp. 109–114, Jan. 2015.
- [35] J. Allen, "Photoplethysmography and its application in clinical physiological measurement," *Physiol. Meas.*, vol. 28, no. 3, pp. R1–R39, Feb. 2007.
- [36] C.-H. Lin, "Assessment of bilateral photoplethysmography for lower limb peripheral vascular occlusive disease using color relation analysis classifier," *Comput. Methods Programs Biomed.*, vol. 103, no. 3, pp. 121–131, Sep. 2011.
- [37] N. Selvaraj, A. K. Jaryal, J. Santhosh, S. Anand, and K. K. Deepak, "Monitoring of reactive hyperemia using photoplethysmographic pulse amplitude and transit time," *J. Clin. Monitoring Comput.*, vol. 23, no. 5, pp. 315–322, Oct. 2009.
- [38] S. E. Gordon, N. Cartwright, and M. J. D. Griffiths, "Investigation of endothelial function by pulse contour analysis: A protocol for drug administration and timing of pulse contour assessment," *Brit. J. Clin. Pharmacol.*, vol. 68, no. 4, pp. 630–633, Oct. 2009.
- [39] M. Iantorno and R. G. Weiss, "Using advanced noninvasive imaging techniques to probe the links between regional coronary artery endothelial dysfunction and atherosclerosis," *Trends Cardiovascular Med.*, vol. 24, no. 4, pp. 149–156, May 2014.
- [40] M. Al-Qaisi, R. K. Kharbanda, T. K. Mittal, and A. E. Donald, "Measurement of endothelial function and its clinical utility for cardiovascular risk," *Vascular Health Risk Manage.*, vol. 4, no. 3, pp. 647–652, 2008.
- [41] I. Cordovil, G. Huguenin, G. Rosa, A. Bello, O. Köhler, R. de Moraes, and E. Tibiriçá, "Evaluation of systemic microvascular endothelial function using laser speckle contrast imaging," *Microvascular Res.*, vol. 83, no. 3, pp. 376–379, May 2012.
- [42] A. H. Al-Fiadh, O. Farouque, R. Kawasaki, T. T. Nguyen, N. Uddin, M. Freeman, S. K. Patel, L. M. Burrell, and T. Y. Wong, "Retinal microvascular structure and function in patients with risk factors of atherosclerosis and coronary artery disease," *Atherosclerosis*, vol. 233, no. 2, pp. 478–484, Apr. 2014.
- [43] B. Gopinath, J. Chiha, A. J. H. Plant, A. Thiagalingam, G. Burlutsky, P. Kovoor, G. Liew, and P. Mitchell, "Associations between retinal microvascular structure and the severity and extent of coronary artery disease," *Atherosclerosis*, vol. 236, no. 1, pp. 25–30, Sep. 2014.
- [44] I.-M. Su, D.-A. Wu, C.-J. Lee, J.-S. Hou, B.-G. Hsu, and J.-H. Wang, "Serum cystatin C is independently associated with aortic arterial stiffness in patients with type 2 diabetes," *Clinica Chim. Acta*, vol. 480, pp. 114–118, May 2018.
- [45] M. Giraldo-Gruoso and D. Echeverri, "From endothelial dysfunction to arterial stiffness in diabetes mellitus," *Current Diabetes Rev.*, pp. 1–7, Oct. 2018.
- [46] M. E. Boesen, D. Singh, B. K. Menon, and R. Frayne, "A systematic literature review of the effect of carotid atherosclerosis on local vessel stiffness and elasticity," *Atherosclerosis*, vol. 243, no. 1, pp. 211–222, 2015.
- [47] R. de Oliveira Alvim, P. C. J. L. Santos, M. M. Musso, R. de Sá Cunha, J. E. Krieger, J. G. Mill, and A. C. Pereira, "Impact of diabetes mellitus on arterial stiffness in a representative sample of an urban Brazilian population," *Diabetology Metabolic Syndrome*, vol. 5, no. 1, p. 45, Aug. 2013.
- [48] A. S. de M. Matheus, B. P. Pires, E. Tibiriçá, A. T. K. Silva, and M. B. Gomes, "Assessment of arterial stiffness in type 1 diabetes using digital pulse contour analysis: Is it a reliable method?" *Acta Diabetologica*, vol. 53, no. 3, pp. 477–482, Jun. 2016.
- [49] E. Gkaliagkousi and S. Douma, "The pathogenesis of arterial stiffness and its prognostic value in essential hypertension and cardiovascular diseases," *Hippokratia*, vol. 13, no. 2, pp. 70–75, Apr./Jun. 2009.
- [50] P.-Y. Lin, F.-Y. Lee, C. G. Wallace, K.-H. Chen, G.-S. Kao, P.-H. Sung, S. Chua, S.-F. Ko, Y.-L. Chen, S.-C. Wu, H.-W. Chang, H.-K. Yip, and P.-L. Shao, "The therapeutic effect of rosuvastatin and propylthiouracil on ameliorating high-cholesterol diet-induced rabbit aortic atherosclerosis and stiffness," *Int. J. Cardiol.*, vol. 227, pp. 938–949, Jan. 2017.
- [51] M. Makunaite, R. Jurkonis, A. Rodríguez-Martínez, R. Jurgaitiene, V. Semaška, K. Melinyté, and R. Kubilius, "Ultrasonic parametrization of arterial wall movements in low- and high-risk CVD subjects," *Appl. Sci.*, vol. 9, no. 3, p. 465, Jan. 2019. [Online]. Available: <http://www.mdpi.com/2076-3417/9/3/465>
- [52] N. A. Shirwany and M.-H. Zou, "Arterial stiffness: A brief review," *Acta Pharmacologica Sinica*, vol. 31, no. 10, pp. 1267–1276, Aug. 2010.
- [53] B. Güngör, H. Yılmaz, A. Ekmekçi, K. S. Özcan, M. Tījani, D. Osmonov, B. Karataş, A. T. Alper, F. O. Mutluer, U. Gürkan, and O. Bolca, "Aortic stiffness is increased in patients with premature coronary artery disease: A tissue Doppler imaging study," *J. Cardiol.*, vol. 63, no. 3, pp. 223–229, Mar. 2014.
- [54] H. Chen and G. S. Kassab, "Microstructure-based biomechanics of coronary arteries in health and disease," *J. Biomech.*, vol. 49, no. 12, pp. 2548–2559, Aug. 2016.
- [55] S. Rajala, H. Lindholm, and T. Taipalus, "Comparison of photoplethysmogram measured from wrist and finger and the effect of measurement location on pulse arrival time," *Physiol. Meas.*, vol. 39, no. 7, Aug. 2018, Art. no. 075010.
- [56] L. N. Cosenso-Martin, L. T. Giollo-Júnior, L. A. B. Fernandes, C. B. Cesarino, M. A. Nakazonok, M. de Nassau Machado, J. C. Yugar-Toledo, and J. F. Vilela-Martin, "Effect of vildagliptin versus glibenclamide on endothelial function and arterial stiffness in patients with type 2 diabetes and hypertension: A randomized controlled trial," *Acta Diabetologica*, vol. 55, no. 12, pp. 1237–1245, Dec. 2018.
- [57] I. J. Kullo and A. R. Malik, "Arterial ultrasonography and tonometry as adjuncts to cardiovascular risk stratification," *J. Amer. College Cardiol.*, vol. 49, no. 13, pp. 1413–1426, Apr. 2007.
- [58] J. Y. Cho and K. H. Kim, "Evaluation of arterial stiffness by echocardiography: Methodological aspects," *Chonnam Med. J.*, vol. 52, no. 2, pp. 101–106, May 2016. [Online]. Available: <http://synapse.koreamed.org/DOLx.php?id=10.4068%2Fcmj.2016.52.2.101>
- [59] N. A. Proudfoot, J. S. Au, B. W. Timmons, and M. J. MacDonald, "Associations between carotid artery longitudinal wall motion and arterial stiffness indicators in young children," *Atherosclerosis*, vol. 287, pp. 64–69, Aug. 2019.
- [60] T. Li, H.-F. Xi, H.-M. Luo, W.-X. Liu, X. Gao, D.-W. Liu, and L. Yang, "Association of the NAD(P)H oxidase p22 phox gene C242T polymorphism with type 2 diabetes mellitus, diabetic nephropathy, and carotid atherosclerosis with type 2 diabetes mellitus: A meta-analysis," *Meta Gene*, vol. 6, pp. 1–8, Dec. 2015.
- [61] R. W. Jayalath, S. H. Mangan, and J. Golledge, "Aortic calcification," *Eur. J. Vascular Endovascular Surg.*, vol. 30, no. 5, pp. 476–488, Nov. 2005.
- [62] T. Hirota, E. Suzuki, I. Ito, M. Ishiyama, S. Goto, Y. Horikawa, T. Asano, M. Kanematsu, H. Hoshi, and J. Takeda, "Coronary artery calcification, arterial stiffness and renal insufficiency associate with serum levels of tumor necrosis factor-alpha in Japanese type 2 diabetic patients," *Diabetes Res. Clin. Pract.*, vol. 82, no. 1, pp. 58–65, Oct. 2008.
- [63] E. Harper, H. Forde, C. Davenport, C. D. Rochford, D. Smith, and P. M. Cummins, "Vascular calcification in type-2 diabetes and cardiovascular disease: Integrative roles for OPG, RANKL and TRAIL," *Vascular Pharmacol.*, vol. 82, pp. 30–40, Jul. 2016.
- [64] E. J. E. Hendriks, P. A. de Jong, Y. van der Graaf, W. P. T. M. Mali, Y. T. van der Schouw, and J. W. J. Beulens, "Breast arterial calcifications: A systematic review and meta-analysis of their determinants and their association with cardiovascular events," *Atherosclerosis*, vol. 239, no. 1, pp. 11–20, Mar. 2015.
- [65] J.-S. Moon, V. M. Clark, J. W. Beabout, R. G. Swee, and P. J. Dyck, "A controlled study of medial arterial calcification of legs: Implications for diabetic polyneuropathy," *Arch. Neurol.*, vol. 68, no. 10, pp. 1290–1294, Oct. 2011.
- [66] M. Moradi and E. Varasteh, "Coronary atherosclerosis evaluation among Iranian patients with zero coronary calcium score in computed tomography coronary angiography," *Adv. Biomed. Res.*, vol. 5, p. 24, Feb. 2016.
- [67] W. Liu, Y. Zhang, C.-M. Yu, Q.-W. Ji, M. Cai, Y.-X. Zhao, and Y.-J. Zhou, "Current understanding of coronary artery calcification," *J. Geriatric Cardiol.*, vol. 12, no. 6, pp. 668–675, Nov. 2015.
- [68] T. Roleder and W. Wojakowski, "Intravascular ultrasound, optical coherence tomography and near infrared spectroscopy," *Cor et Vasa*, vol. 57, no. 6, pp. e439–e445, Dec. 2015. [Online]. Available: <https://www.sciencedirect.com/science/article/pii/S0010865015001083>

- [69] S. P. Marso and W. R. Hiatt, "Peripheral arterial disease in patients with diabetes," *J. Amer. College Cardiol.*, vol. 47, no. 5, pp. 921–929, Mar. 2006.
- [70] K. J. Rocha-Singh, T. Zeller, and M. R. Jaff, "Peripheral arterial calcification: Prevalence, mechanism, detection, and clinical implications," *Catheterization Cardiovascular Interventions, Off. J. Soc. Cardiac Angiography Intervent.*, vol. 83, no. 6, pp. E212–E220, May 2014.
- [71] G. Liew, C. Chow, N. van Pelt, J. Younger, M. Jelinek, J. Chan, and C. Hamilton-Craig, "Cardiac society of australia and new zealand position statement: Coronary artery calcium scoring," *Heart, Lung Circulat.*, vol. 26, pp. 1239–1251, Dec. 2017.
- [72] P. O. Neves, J. Andrade, and H. Monção, "Coronary artery calcium score: Current status," *Radiologia Brasileira*, vol. 50, no. 3, pp. 182–189, 2017.
- [73] F. Commaeur, M. Goeller, and D. Dey, "Cardiac CT: Technological advances in hardware, software, and machine learning applications," *Current Cardiovascular Imag. Rep.*, vol. 11, p. 19, Aug. 2018.
- [74] H. Taniwaki, T. Shoji, M. Emoto, T. Kawagishi, E. Ishimura, M. Inaba, Y. Okuno, and Y. Nishizawa, "Femoral artery wall thickness and stiffness in evaluation of peripheral vascular disease in type 2 diabetes mellitus," *Atherosclerosis*, vol. 158, no. 1, pp. 207–214, Sep. 2001.
- [75] A. Chawla, R. Chawla, and S. Jaggi, "Microvascular and macrovascular complications in diabetes mellitus: Distinct or continuum?" *Indian J. Endocrinology Metabolism*, vol. 20, no. 4, pp. 546–551, 2016.
- [76] R. López-Diez, A. Shekhtman, R. Ramasamy, and A. M. Schmidt, "Cellular mechanisms and consequences of glycation in atherosclerosis and obesity," *Biochim. Biophys. Acta (BBA)-Mol. Basis Disease*, vol. 1862, no. 12, pp. 2244–2252, Dec. 2016.
- [77] L. M. Lin, F. Peng, Y. P. Liu, D. J. Chai, R. B. Ning, C. S. Xu, and J. X. Lin, "Coadministration of VDR and RXR agonists synergistically alleviates atherosclerosis through inhibition of oxidative stress: An *in vivo* and *in vitro* study," *Atherosclerosis*, vol. 251, pp. 273–281, Aug. 2016.
- [78] D. R. J. Owen, A. C. Lindsay, R. P. Choudhury, and Z. A. Fayad, "Imaging of atherosclerosis," *Annu. Rev. Med.*, vol. 62, pp. 25–40, Feb. 2011.
- [79] T. Nezu, N. Hosomi, S. Aoki, and M. Matsumoto, "Carotid intima-media thickness for atherosclerosis," *J. Atherosclerosis Thrombosis*, vol. 23, no. 1, pp. 18–31, 2016.
- [80] R. Onut, A. P. S. Balanescu, D. Constantinescu, L. Calmac, M. Marinescu, and P. M. Dorobantu, "Imaging atherosclerosis by carotid intima-media thickness *in vivo*: How to, where and in whom?" *Maedica*, vol. 7, no. 2, pp. 153–162, Jun. 2012.
- [81] M. Zhang, X. Wen, C. Zhou, J. Huang, and Y. He, "Carotid intima-media thickness and plaques in internal carotid artery as surrogate markers of lower limb arterial lesions in Chinese patients with diabetic foot," *Brazilian J. Med. Biol. Res.*, vol. 52, no. 7, p. e8432, 2019.
- [82] G. S. Werner, B. M. Richartz, S. Heinke, M. Ferrari, and H. R. Figulla, "Impaired acute collateral recruitment as a possible mechanism for increased cardiac adverse events in patients with diabetes mellitus," *Eur. Heart J.*, vol. 24, no. 12, pp. 1134–1142, Jun. 2003.
- [83] V. P. dos Santos, R. A. Caffaro, G. Pozzan, M. A. Saieg, and V. Castelli, Jr., "Comparative histological study of atherosclerotic lesions and microvascular changes in amputated lower limbs of diabetic and non-diabetic patients," *Arquivos Brasileiros de Endocrinologia e Metabologia*, vol. 52, no. 7, pp. 1115–1123, Oct. 2008.
- [84] O. Faust, U. R. Acharya, V. K. Sudarshan, R. S. Tan, C. H. Yeong, F. Molinari, and K. H. Ng, "Computer aided diagnosis of coronary artery disease, myocardial infarction and carotid atherosclerosis using ultrasound images: A review," *Phys. Medica*, vol. 33, pp. 1–15, Jan. 2017.
- [85] M. Mudau, A. Genis, A. Lochner, and H. Strijdom, "Endothelial dysfunction: The early predictor of atherosclerosis," *Cardiovascular J. Afr.*, vol. 23, no. 4, pp. 222–231, May 2012.
- [86] F. Demeure, C. Bouzin, V. Roelants, A. Bol, R. Verhelst, P. Astarci, and J. L. J. Vanoverschelde, "Head-to-head comparison of inflammation and neovascularization in human carotid plaques: Implications for the imaging of vulnerable plaques," *Circulat. Cardiovascular Imag.*, vol. 10, no. 5, May 2017, Art. no. e005846.
- [87] R. B. Singh, S. A. Mengi, Y.-J. Xu, A. S. Arneja, and N. S. Dhalla, "Pathogenesis of atherosclerosis: A multifactorial process," *Experim. Clin. Cardiol.*, vol. 7, no. 1, pp. 40–53, 2002.
- [88] K. Toutouzias, G. Benetos, M. Drakopoulou, P. Bounas, D. Tsekoura, K. Stathogiannis, I. Koutagiari, C. Aggeli, A. Karanasos, D. Panagiotakos, E. Siores, and C. Stefanadis, "Insights from a thermography-based method suggesting higher carotid inflammation in patients with diabetes mellitus and coronary artery disease," *Diabetes Metabolism*, vol. 40, no. 6, pp. 431–438, Dec. 2014.
- [89] A. Spångeus, M. Wijkman, T. Lindström, J. E. Engvall, C. J. Östgren, F. H. Nystrom, and T. Länne, "Toe brachial index in middle aged patients with diabetes mellitus type 2: Not just a peripheral issue," *Diabetes Res. Clin. Pract.*, vol. 100, no. 2, pp. 195–202, May 2013.
- [90] M. Magnoni, E. Ammirati, and P. G. Camici, "Non-invasive molecular imaging of vulnerable atherosclerotic plaques," *J. Cardiol.*, vol. 65, no. 4, pp. 261–269, 2015.
- [91] V. Baliyan, K. Shaqdan, S. Hedgire, and B. Ghoshhajra, "Vascular computed tomography angiography technique and indications," *Cardiovascular Diagnosis Therapy*, vol. 9, p. S14, Aug. 2019. [Online]. Available: <http://cdt.amegroups.com/article/view/28039>
- [92] S. H. Kang, G.-M. Park, S.-W. Lee, S.-C. Yun, Y.-H. Kim, Y.-R. Cho, H. W. Park, J. Suh, D. H. Yang, J.-W. Kang, T.-H. Lim, C. H. Jung, E. H. Koh, W. J. Lee, M.-S. Kim, K.-U. Lee, and J.-Y. Park, "Long-term prognostic value of coronary CT angiography in asymptomatic type 2 diabetes mellitus," *JACC Cardiovascular Imag.*, vol. 9, no. 11, pp. 1292–1300, Nov. 2016.
- [93] C. Celeng, P. Maurovich-Horvat, B. B. Ghoshhajra, B. Merkely, T. Leiner, and R. A. P. Takx, "Prognostic value of coronary computed tomography angiography in patients with diabetes: A meta-analysis," *Diabetes Care*, vol. 39, no. 7, pp. 1274–1280, Jul. 2016.
- [94] N. R. Evans, J. M. Tarkin, M. M. Chowdhury, E. A. Warburton, and J. H. F. Rudd, "PET imaging of atherosclerotic disease: Advancing plaque assessment from anatomy to pathophysiology," *Current Atherosclerosis Rep.*, vol. 18, no. 6, p. 30, Jun. 2016.
- [95] S. M. Gospe, M. T. Bhatti, and M. A. El-Dairi, "Emerging applications of optical coherence tomography in pediatric optic neuropathies," *Seminars Pediatric Neurol.*, vol. 24, no. 2, pp. 135–142, May 2017.
- [96] G. Mule, M. Vadala, G. Geraci, and S. Cottone, "Retinal vascular imaging in cardiovascular medicine: New tools for an old examination," *Atherosclerosis*, vol. 268, pp. 188–190, Jan. 2018.
- [97] M. Horvath, P. Hajek, C. Stechovsky, J. Honek, M. Spacek, and J. Veselka, "The role of near-infrared spectroscopy in the detection of vulnerable atherosclerotic plaques," *Arch. Med. Sci.*, vol. 12, no. 6, pp. 1308–1316, Dec. 2016.
- [98] M. J. Blaha, M. B. Mortensen, S. Kianoush, R. Tota-Maharaj, and M. Cainzos-Achirica, "Coronary artery calcium scoring: Is it time for a change in methodology?" *JACC, Cardiovascular Imag.*, vol. 10, no. 8, pp. 923–937, Aug. 2017. [Online]. Available: <http://imaging.onlinejacc.org/content/10/8/923.abstract>
- [99] M. Kaspar, I. Baumgartner, D. Staub, H. Drexel, and C. Thalhammer, "Non-invasive ultrasound-based imaging of atherosclerosis," *VASA Zeitschrift für Gefasskrankheiten*, vol. 48, no. 2, pp. 126–133, Mar. 2019.
- [100] S. M. Marshall and A. Flyvbjerg, "Prevention and early detection of vascular complications of diabetes," *BMJ*, vol. 333, no. 7566, pp. 475–480, Aug. 2006.
- [101] S. Bonapace, A. Rossi, P. Lipari, L. Bertolini, L. Zenari, L. Lanzoni, G. Canali, G. Molon, A. Mantovani, G. Zoppini, E. Bonora, E. Barbieri, and G. Targher, "Relationship between increased left atrial volume and microvascular complications in patients with type 2 diabetes," *J. Diabetes Complications*, vol. 29, no. 6, pp. 822–828, Aug. 2015.
- [102] F. Paneni, J. A. Beckman, M. A. Creager, and F. Cosentino, "Diabetes and vascular disease: Pathophysiology, clinical consequences, and medical therapy: Part I," *Eur. Heart J.*, vol. 34, no. 31, pp. 2436–2443, May 2013.
- [103] D. Marvicin, P. Jennings, and D. Ziegler-Bezaire, "What is new in diabetes technology?" *J. Nurse Practitioners*, vol. 13, no. 3, pp. 205–209, 2017.
- [104] V. Galusko, O. Bodger, and A. Ionescu, "A systematic review of pocket-sized imaging devices: Small and mighty?" *Echo Res. Pract.*, vol. 5, no. 4, pp. 113–138, Dec. 2018.
- [105] K. Mather and R. Lewanczuk, "Measurement of arterial stiffness in diabetes: A cautionary tale," *Diabetes Care*, vol. 27, no. 3, pp. 831–833, Mar. 2004.
- [106] F. Rundo, S. Conoci, A. Ortis, and S. Battiato, "An advanced bio-inspired photoplethysmography (PPG) and ECG pattern recognition system for medical assessment," *Sensors*, vol. 18, no. 2, p. 405, Jan. 2018.
- [107] K. T. Tgavalekos, J. M. Kainerstorfer, A. Sassaroli, and S. Fantini, "Blood-pressure-induced oscillations of deoxy- and oxyhemoglobin concentrations are in-phase in the healthy breast and out-of-phase in the healthy brain," *J. Biomed. Opt.*, vol. 21, no. 10, Mar. 2016, Art. no. 101410.
- [108] A. Alonso, D. Artemis, and M. G. Hennerici, "Molecular imaging of carotid plaque vulnerability," *Cerebrovascular Diseases*, vol. 39, no. 1, pp. 5–12, 2015.

- [109] D. Sokas, A. Petrėnas, S. Daukantas, A. Rapalis, B. Paliakaitė, and V. Marozas, "Estimation of heart rate recovery after stair climbing using a wrist-worn device," *Sensors*, vol. 19, no. 9, p. 2113, May 2019.
- [110] I. Contreras and J. Vehi, "Artificial intelligence for diabetes management and decision support: literature review," *J. Med. Internet Res.*, vol. 20, no. 5, May 2018, Art. no. e10775.



**SERGEJ SOSUNKEVIČ** received the M.Sc. degree in rehabilitation from the Lithuanian University of Health Science, Kaunas, Lithuania in 2012. He is currently pursuing the PhD degree with the Biomedical Engineering Institute the Kaunas University of Technology, Kaunas, Lithuania.

He is a lecturer with the Department of Electronics Engineering, Kaunas University of Technology and Institute of Anatomy, Lithuanian Health Science University. His current research interests

include diabetes, non-invasive techniques for evaluating peripheral circulatory functions, cardiovascular neuropathy, and cardio autonomic neuropathy.



**ANDRIUS RAPALIS** received the B.Sc. degree in electronics engineering in 2010, M.Sc. degree in biomedical engineering in 2012 and the Ph.D. degree in electrical and electronics engineering in 2017 all from the Kaunas University of Technology, Kaunas, Lithuania.

Since 2015, he is a lecturer with the Electronics Engineering Department, Kaunas University of Technology. Since 2017, he is a researcher with the Biomedical Engineering Institute, Kaunas University of Technology.

His research interests include digital biomedical signal processing and development of technologies for monitoring the functional state of cardiovascular system.



**MINDAUGAS MAROZAS** received the B.Sc. degree in electronics engineering and M.Sc. degree in biophysics at Kaunas University of Technology, Kaunas, Lithuania, in 2003 and 2005 respectively. He is currently pursuing the Ph.D. degree with the Biomedical Engineering Institute, Kaunas University of Technology.

Since 2014, he has been assisting in several projects, such as early diabetes diagnosis, and prediction at the Biomedical Engineering Institute.

His research interests include biomedical signal processing, parametrization, and data mining.



**JONAS ČEPONIS** received the MD and MD-PhD degrees in 2004 and 2014, respectively at Lithuanian University of Health Sciences in Kaunas, Lithuania.

He currently works as an endocrinologist at the hospital of the Lithuanian University of Health Sciences and is an associate professor and senior researcher at the Department and Institute of Endocrinology at Lithuanian University of Health Sciences. His research focuses on metabolic

effects of sex hormones and cardiovascular disease in diabetes.



**ARŪNAS LUKOŠEVIČIUS** received the Dipl. Eng., Ph.D., and Doctor Habilitus degrees from the Kaunas University of Technology, Lithuania, in 1964, 1976, and 1996, respectively, all in electronics. He is currently a scientific supervisor of Biomedical Engineering Institute, Kaunas University of Technology. His research interests include biosignal processing, wireless sensing of physiological processes, ultrasonic tissue characterisation, and integration of smart monitoring devices

in eHealth environment. He has been leading FP, Interreg, Eurostars project workgroups in those fields.

Dr. Lukoševičius has been the President of Lithuanian Biomedical Engineering Society since 1997, a member of the Coordination Board for eHealth projects at the Ministry of Health Care of Lithuania (2005-2016), member of National Lisbon strategy implementation target group for research, technological development and innovations since 2006, and member of the Board of Telemedicine Centre, Kaunas University of Medicine since 2001. In 1999, he received a National Science Award for achievements in biomedical engineering.

...